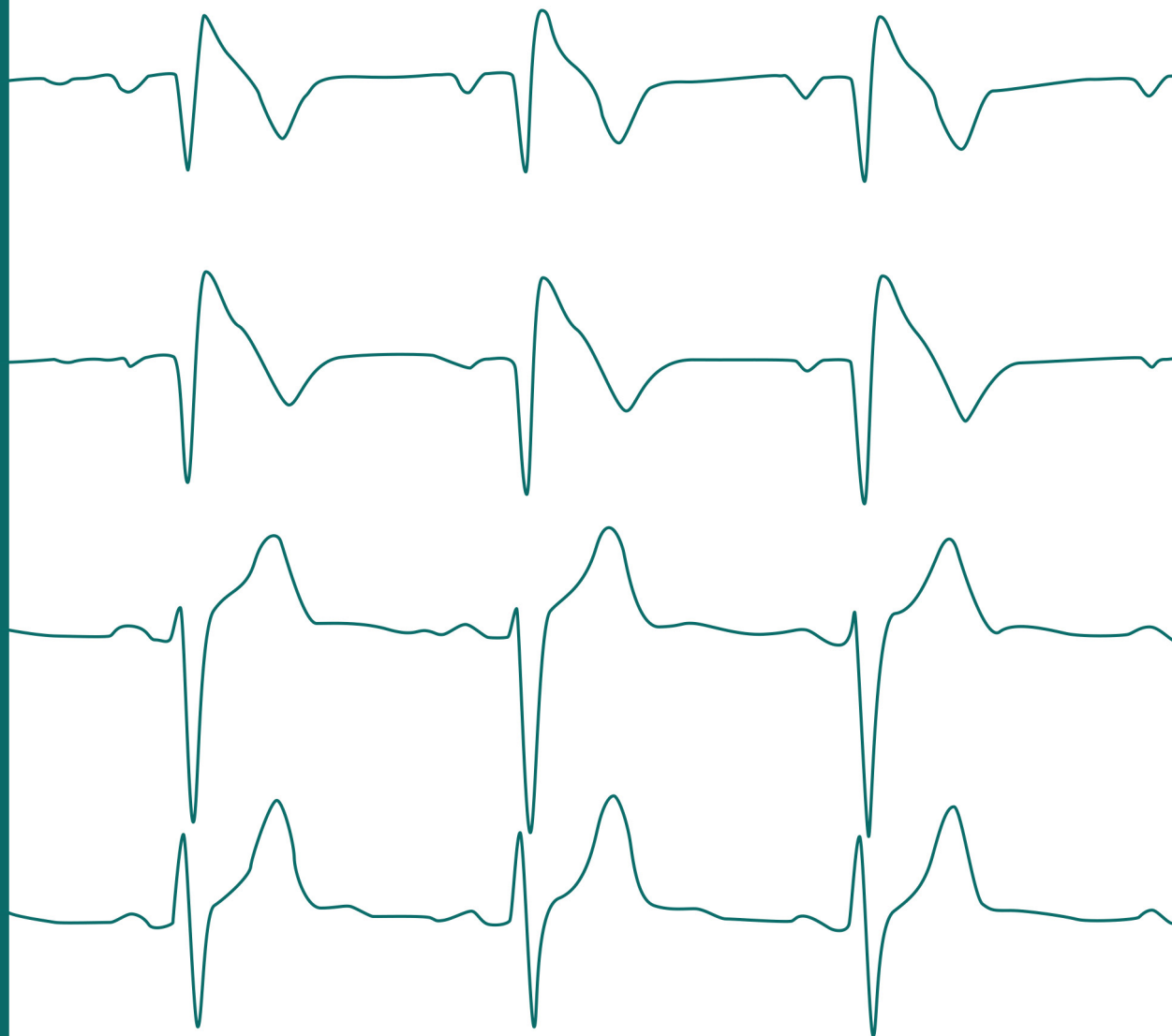

Electrocardiography at your fingertips

Ramon Brugada, Manjot Singh



Electrocardiography at your fingertips

Electrocardiography at your fingertips

**Ramon Brugada
Manjot Singh**

Foreword
by Pere Brugada

CIP data provided by the UdG Library

CIP 616.12-07 BRU

Brugada, Ramon, autor

Electrocardiography at your fingertips / Ramon Brugada, Manjot

Singh ; foreword by Pere Brugada. -- Girona : Documenta

Universitaria : Publications Service of the UdG, [2024]. -- 1 recurs
en línia (245 pàgines) : il·lustracions, gràfics

Descripció del recurs: 12 desembre 2024

ISBN 978-84-9984-697-2 (Documenta Universitaria). ISBN

978-84-8458-700-2 (Universitat de Girona)

I. Singh, Manjot, autor II. Brugada i terradellas, Pere, escriptor d'un
pròleg 1. Electrofisiologia 2. Electrocardiografia

3. Cor – Malalties – Diagnòstic

CIP 616.12-07 BRU

Any form of reproduction, distribution, public communication or transformation of this work can only be carried out with the authorization of its owners, except for the exception provided by the law. Address your requests to CEDRO (Centro Español de Derechos Reprográficos) if you need to photocopy or scan a fragment of this work (www.conlicencia.com; +34 91 702 19 70 / +34 93 272 04 47).


CÀTEDRA UdG DE
MALALTIES
CARDIOVASCULARS


Universitat
de Girona

Language review: Ramon Brugada and Manjot Singh

Design and layout: Documenta Universitaria

© of the text and images: their authors

ISBN

978-84-8458-700-2 – Oficina Edicions UdG

978-84-9984-697-2 – Documenta Universitaria

DOI: 10.33115/b/9788499846972



The texts and images contained in this publication are subject –except where indicated to the contrary– to an Attribution-NonCommercial-NoDeriv license (BY-NC-ND) v.4.0. Creative Commons License. You may copy, publicly distribute and transfer them as long as the author and source are credited, neither the work itself nor derived works may be used for commercial gain. The full terms of the license can be viewed at <https://creativecommons.org/licenses/by-nc-nd/4.0/deed.en>

Foreword

That a brother writes a book can happen to many people. That a brother of yours asks you to write the prologue is something stranger, one that has nothing to do with chance, but everything to do with causality. My brother Ramon writes a book with Manjot, a student of his. Ramon who, for a short but intense period, was a student of mine. No better situation to explain the importance of telescopic learning in the progress of knowledge and science.

One of the first humanoids saw the Sun and gave it the name Sun. Immediately, he told his friend — his first student.

—Do you see what I have discovered in the sky? It is the Sun.

The student, now knowing the Sun, saw the Moon during the night, and explained it to his student.

—That's the sun over there, and I've discovered that one, the moon.

The third humanoid, who had no need to explore what the sun and the moon were because he had already learned it from his teachers, then observed the stars. And so, progressively, each humanoid learned many more things more quickly, as if each time it was given a larger and larger telescope: the geometric progression of knowledge.

Each humanoid was both student and teacher. Their knowledge grew through new research and through interaction with their respective students, through the questions they asked each other, questions that may not yet have had a solution at the time. How many humanoids and humans have it taken to define the black holes of space?

Telescopic teaching, a form of learning that pushes itself by the mere fact that there are teachers who want to teach and students who want to learn. A form of exponential learning that would theoretically reach the point of perfection when the teacher becomes useless as a teacher because he or she has already taught everything.

Undoubtedly, working with students is the best way to progress in the transmission of knowledge. Ramon and Manjot have produced a book on electrocardiography of extraordinary quality, based on a very simple principle: a good picture is worth a thousand words. A book that represents a further step in the progression of telescopic learning, a book that, instead of complicating everything, makes it easy to learn.



Pere Brugada
Brussels, Epiphany 2024

Ramon Brugada

Throughout my life I have met people who have made me a better person.

A heartfelt thank you


to those of you who decided to undertake this journey by my side,

to those with whom we share our joys,

to those who we support each other in the face of difficulties,

to those of us who only see each other from time to time, too little, but know that we are always there when we need each other,

to those of you who are no longer here, but I remember you every day with longing.



Head of Cardiology, Hospital Josep Trueta and Santa Caterina.

Professor of Medicine, Director of the Chair of Cardiovascular Diseases, University of Girona.

Director of the Cardiovascular Genetics Centre, Institute of Biomedical Research of Girona.

Manjot Singh

I can never thank Dr. Ramon Brugada enough, who with his characteristic simplicity, all the will of a good heart and with the ease that comes from overcoming challenges, has helped and guided me since we met.

To my cardiologist teachers at the Hospital Doctor Negrín in Gran Canaria, who have taught me the alphabet of cardiology, and to my colleagues at the Hospital Josep Trueta with whom I continue to learn day by day.



Cardiologist, Hospital Josep Trueta de Girona.

Summary

Basic electrophysiology of the myocyte

1. The cardiac action potential.....15
2. The action potential according to the types
of cardiac cells.....22
3. The transmission of the electrical impulse.....23
4. The action potentials and the electrocardiogram25

Recording of the electrical activity of the heart: the electrocardiogram

1. Detection of electrical activity 29
2. Depolarization..... 36
3. Repolarization37

The normal electrocardiogram

1. Recording..... 41
2. The electrocardiogram: waves, complexes, segments
and intervals49

Systematic assessment of the electrocardiogram

1. Alterations in the recording..... 59
2. Rhythm 73
3. Cardiac frequency 76
4. Axis..... 79
5. P wave..... 90
6. PR interval and segment.....108

7. QRS complex.....	120
8. J point.....	148
9. ST segment.....	152
10. T wave.....	162
11. QT interval.....	170
12. U wave.....	174

Ischemia / Injury / Necrosis

1. Definition.....	179
2. Subendocardial ischemia.....	180
3. Subepicardial or transmural ischemia.....	181
4. Subendocardial injury.....	183
5. Subepicardial or transmural injury.....	184
6. Infarction or necrosis.....	186
7. Progression of acute myocardial infarction.....	188
8. Location of the infarction.....	189
9. Acute and old myocardial infarction.....	191
10. Non-Q infarction.....	193
11. Bundle branch block and infarction.....	194

Arrhythmias

1. Definition.....	199
2. Conduction system.....	200
3. Conduction velocities.....	201
4. Reentry mechanism.....	202
5. Type of arrhythmias.....	203
6. Supraventricular rhythms.....	205
7. Ventricular rhythms.....	234
8. Differentiation between ventricular tachycardia and supraventricular tachycardia with wide QRS.....	243

BASIC ELECTROPHYSIOLOGY OF THE MYOCYTE

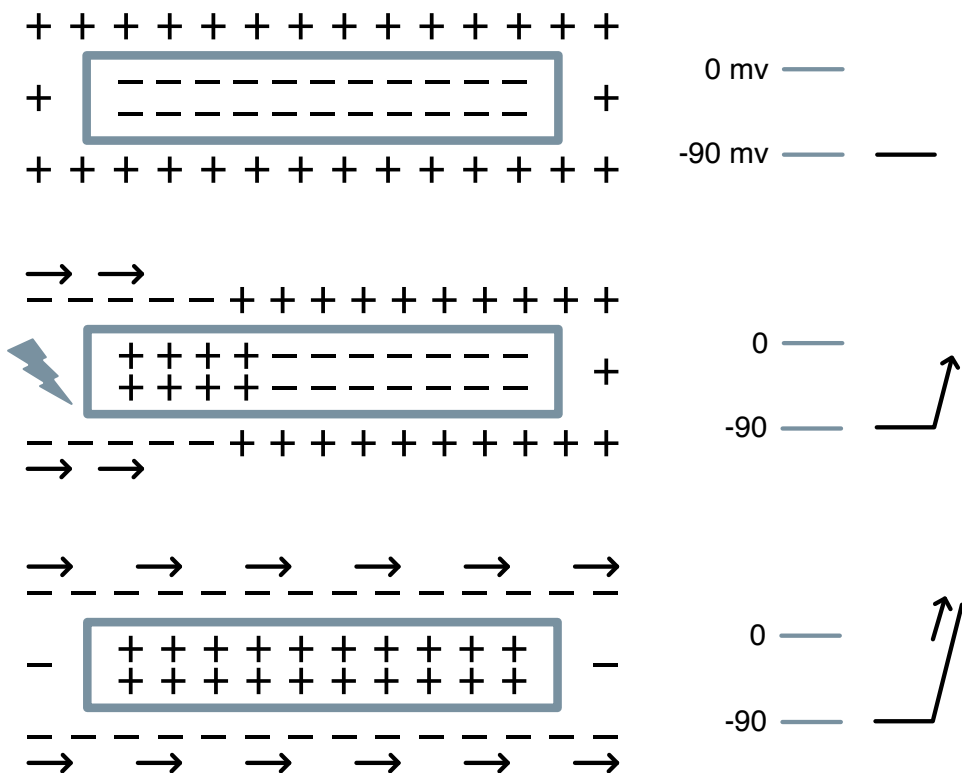


1. The cardiac action potential

The cell at rest is polarized. This polarization is generated by an accumulation of positive charges on the outside and negative charges inside the cell.

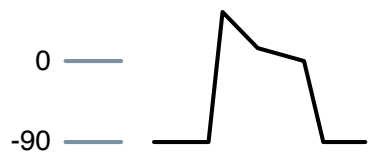
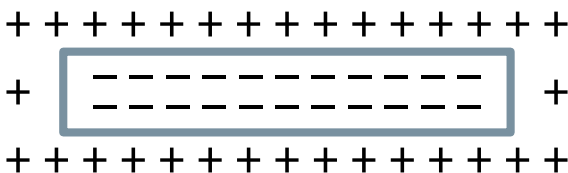
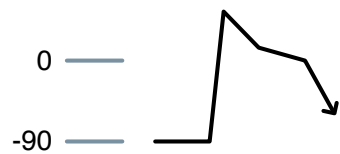
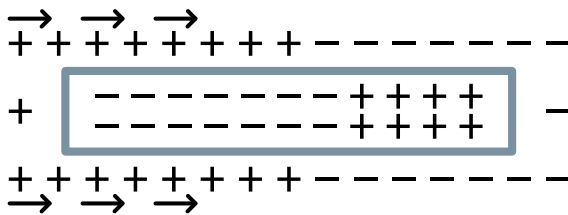
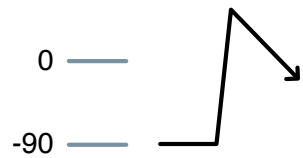
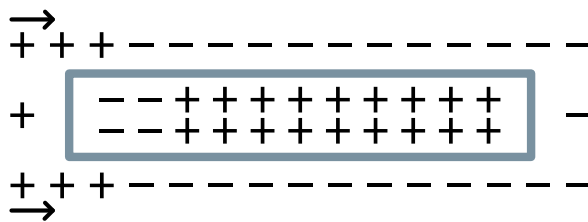
When a stimulus activates the ion channels in the membrane, it sets in motion a ionic exchange between the inside and outside of the cell.

Depolarization



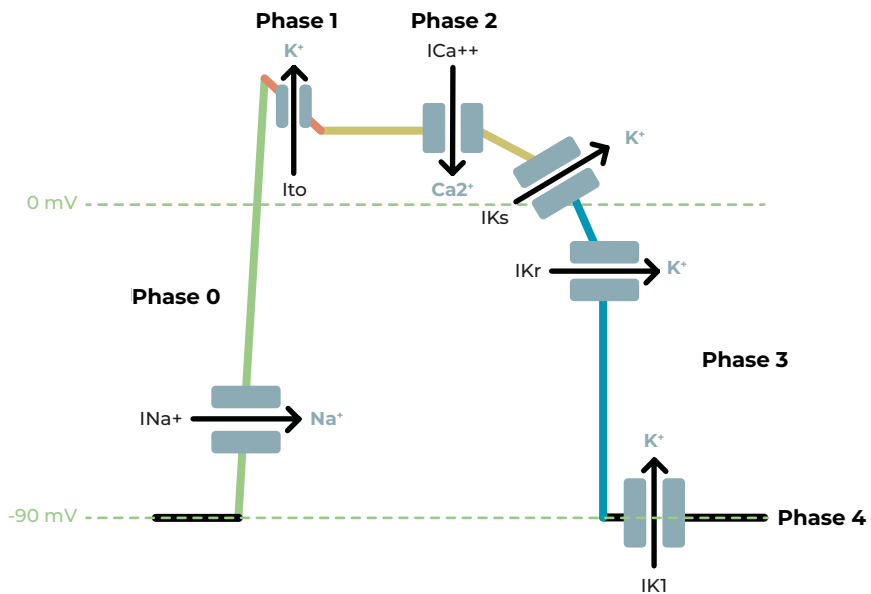
This ionic activation generates the transmembrane action potential, which includes both depolarization and repolarization, to return to its resting phase.

Repolarization



1.1. Generation of action potential

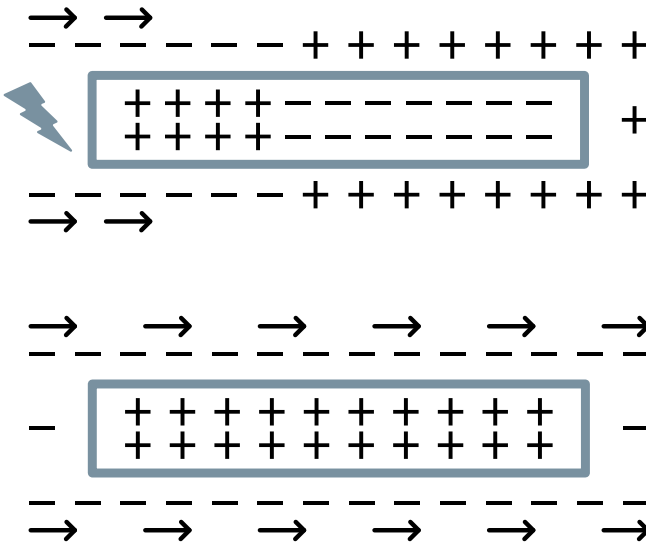
The cardiac action potential consists of 5 phases during which there is activation of different ion channels.



1.2. Phase 0. Depolarization

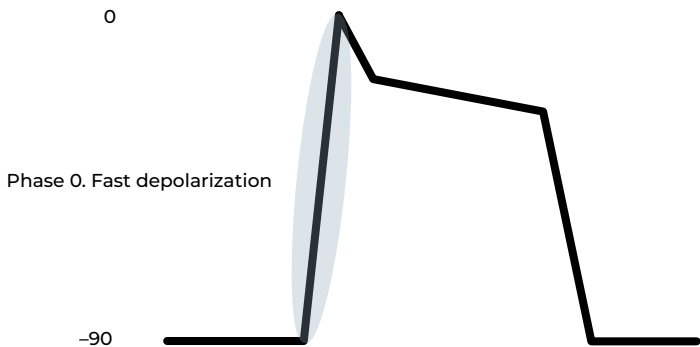
After receiving a stimulus, the cell is activated.

The electrical charge is altered by an exchange of ions (cations and anions) across the membrane.



During depolarization Na^+ enters into the cell. Therefore, the exterior becomes negative and the interior becomes positive.

Depolarization progresses through the entire cell.

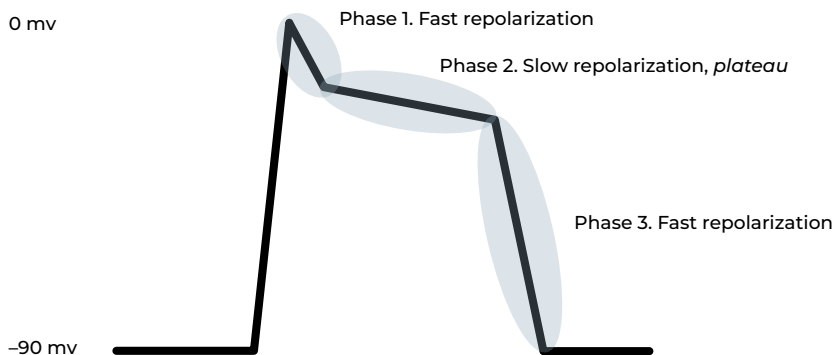
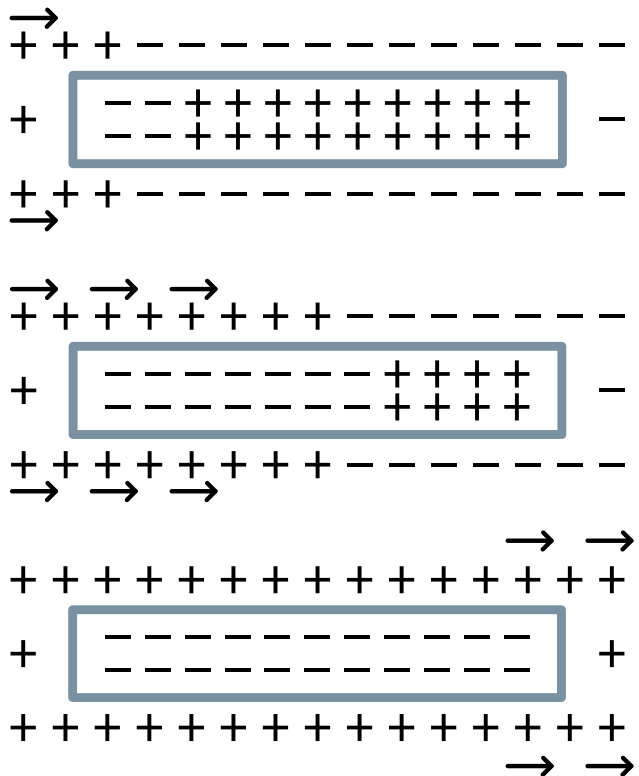


1.3. Phase 1 to 3. Repolarization

Once completely depolarized, the cells begin to regain their internal negative polarity.

During repolarization, cells recover internal negativity to return to the resting phase.

During repolarization, ion channels extract positive charges (especially K⁺) from the cell interior.

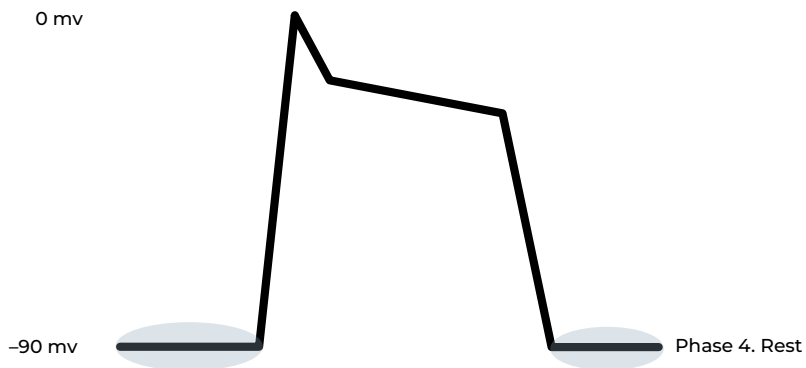
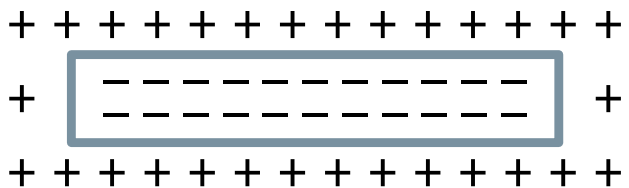


1.4. Phase 4. Resting phase

During the resting phase, the cardiac myocytes are polarized. They have negative charge inside and positive charge on the outside.

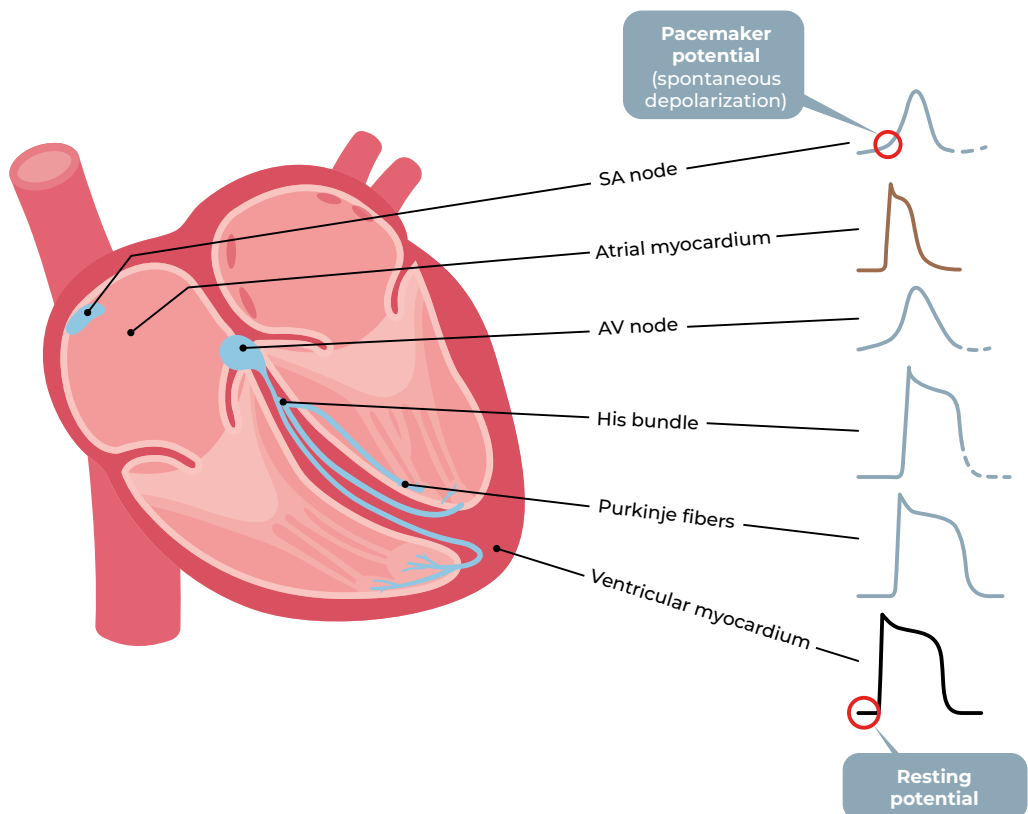
This resting phase is present in contractile or non-automatic cells.

In the automatic cells, as we will see later, there is no real resting phase.



1.5. The different action potentials

The **action potential** is different in each area of the heart and in each cell type to achieve a coordinated electrical and mechanical activity.



2. The action potential according to cardiac cell types

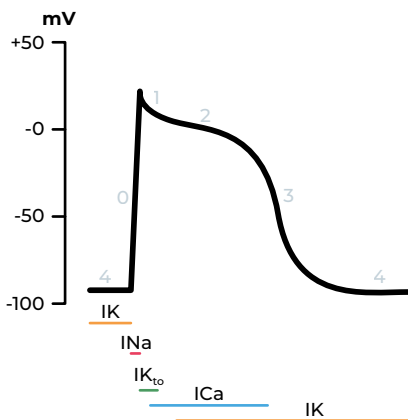
Contractile or non-automatic cell

The non-automatic cell generates contraction, therefore mechanical activity.

It has a resting potential. It needs a stimulus to depolarize. It has a fast response.

It has no capacity to generate or conduct an electrical impulse.

Sodium, calcium and potassium channels participate in the generation of the action potential.



Action potential of a cardiac myocyte (contractile cell)

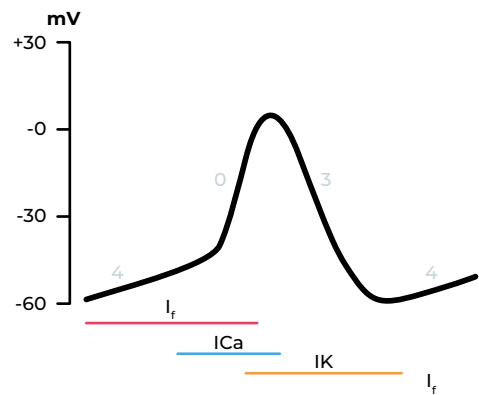
Non-contractile or specific cell

Pacemaker or automatic cell:

- It has the capacity to initiate electrical activation. It has a slow response.
- It can be depolarized continuously without the need for a stimulus.
- It does not have a real resting phase (phase 4 is not horizontal).
- Calcium and potassium channels are involved in the generation of the action potential, as well as the HCN channels responsible for the If current, which allow the entry of sodium and potassium.

Purkinje cell:

- It has the ability to rapidly transmit that electrical impulse.
- It has a fast response.

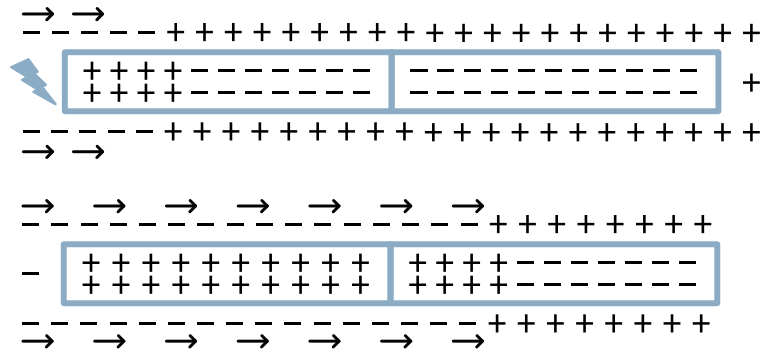


Action potential of an automatic cell

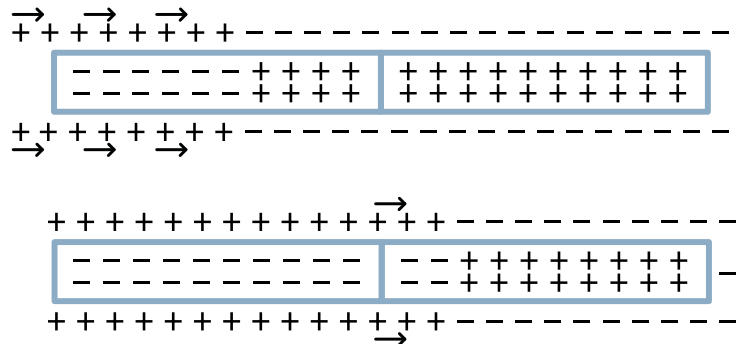
3. The transmission of the electrical impulse

The process of cell activation (depolarization) and of recovery (repolarization) spreads to neighboring cells.

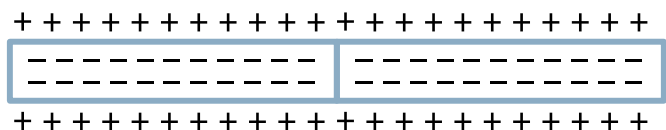
Depolarization



Repolarization



Rest

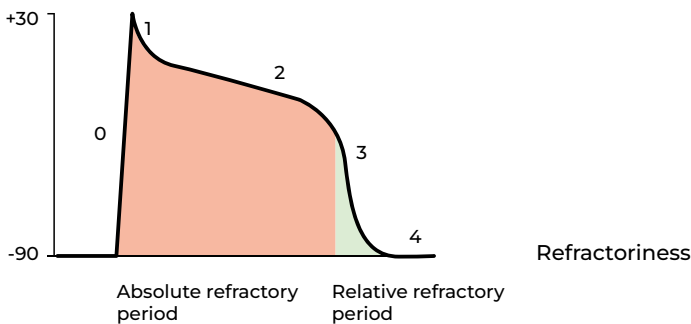
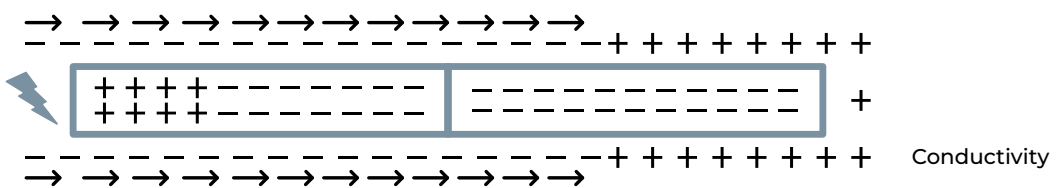
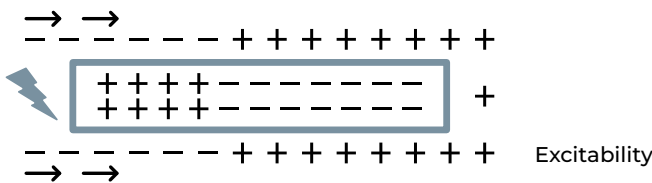
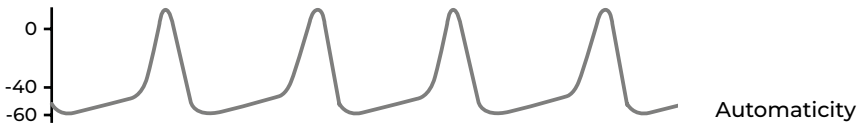


The generation and transmission of the electrical impulse depends on 4 electrophysiological characteristics of cardiac cells:

- **Automaticity** (only in automatic cells). Ability to depolarize spontaneously, to initiate electrical activation without external stimulation.
- **Excitability**. Ability to respond to an external stimulus and generate

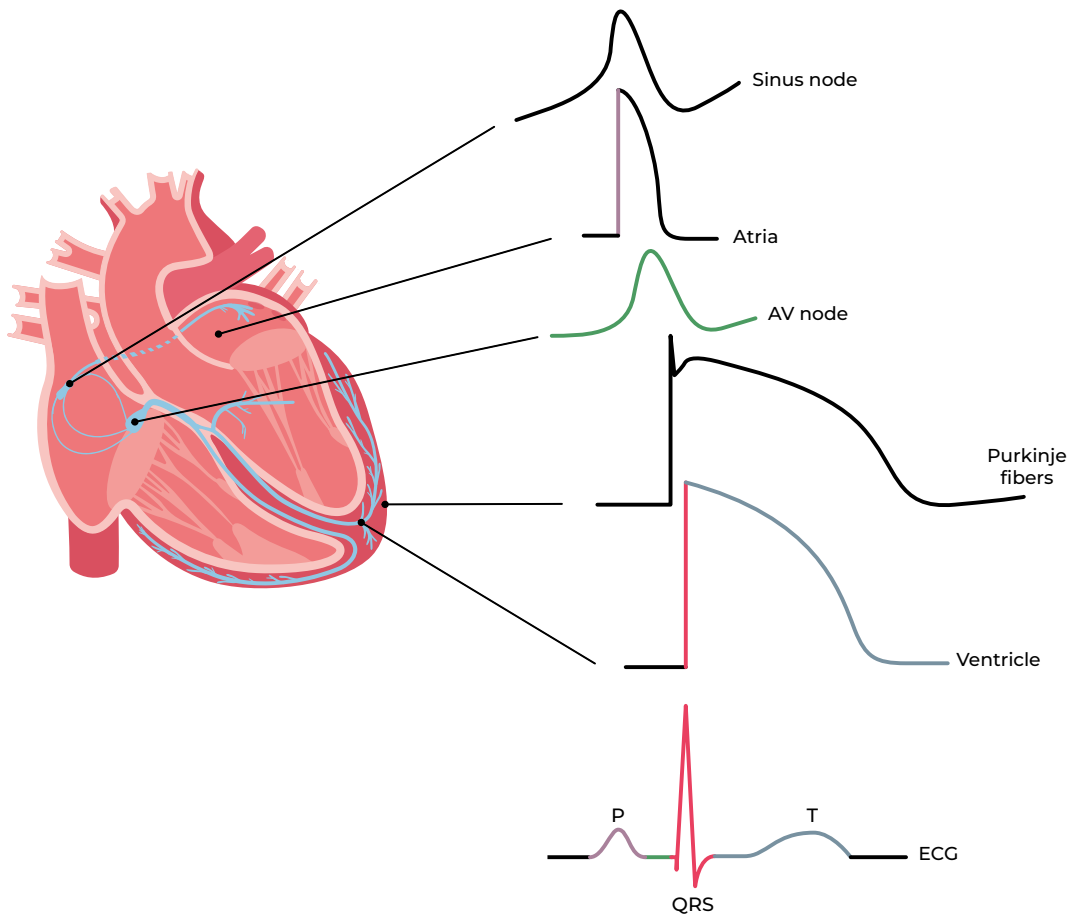
an electrical response (action potential).

- **Conductivity**. Ability to transmit the electrical impulse to another neighboring cell.
- **Refractoriness**. Cells cannot be constantly stimulated. There is a period (refractory period) during which they do not respond to a stimulus.




4. The action potentials and the electrocardiogram

The electrical activity of the heart can be interpreted from the body surface with the **electrocardiogram**, which detects the sum of the electrical activity of all cardiac cells.



**RECORDING
OF THE ELECTRICAL
ACTIVITY OF THE HEART:
THE ELECTROCARDIOGRAM**

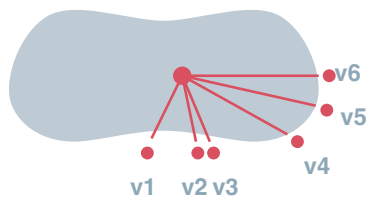


1. Detection of electrical activity

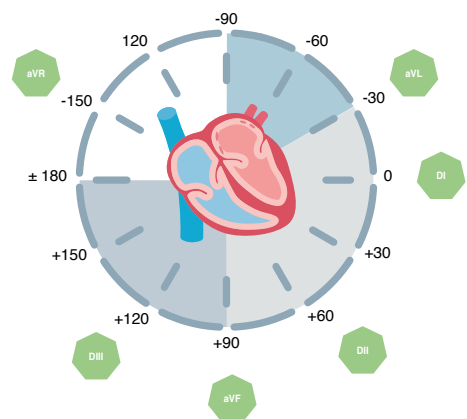
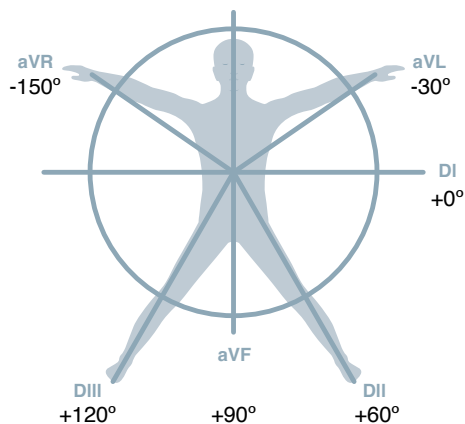
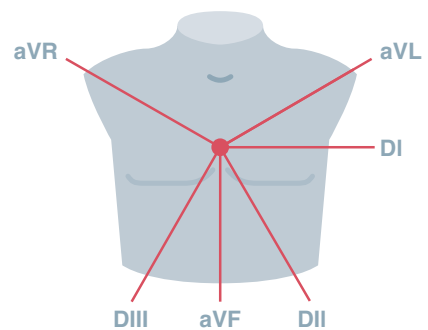
To record an electrocardiogram we use 10 electrodes, which enable the detection of the electrical current from 12 different positions (leads):

- Six limb leads. They detect current from a frontal plane:
 - 3 classic or bipolar leads: DI, DII, DIII.
 - 3 unipolar augmented leads: aVR, aVL, aVF.
- Six unipolar precordial leads (V1 to V6). They detect current from a transverse or horizontal plane.

Horizontal plane



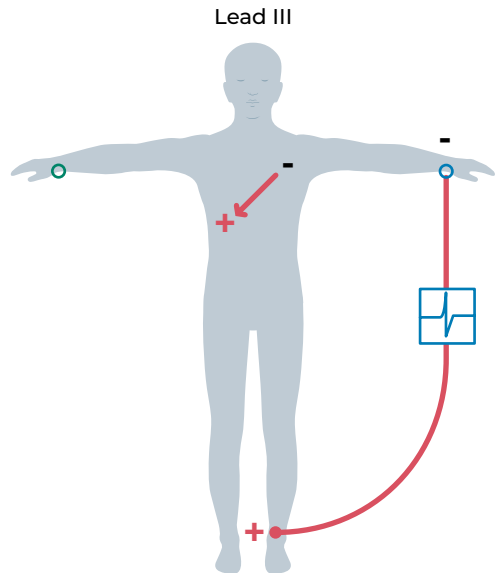
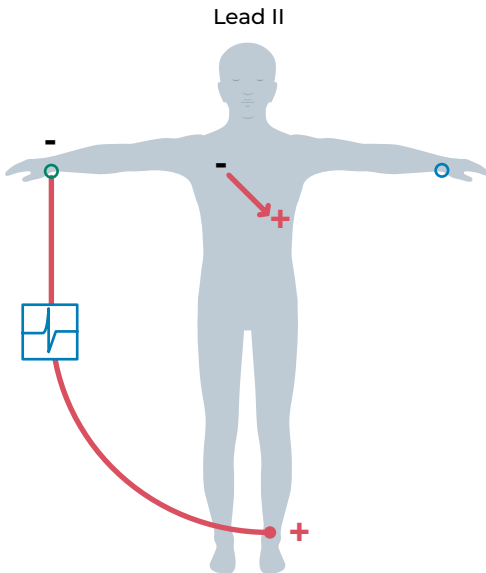
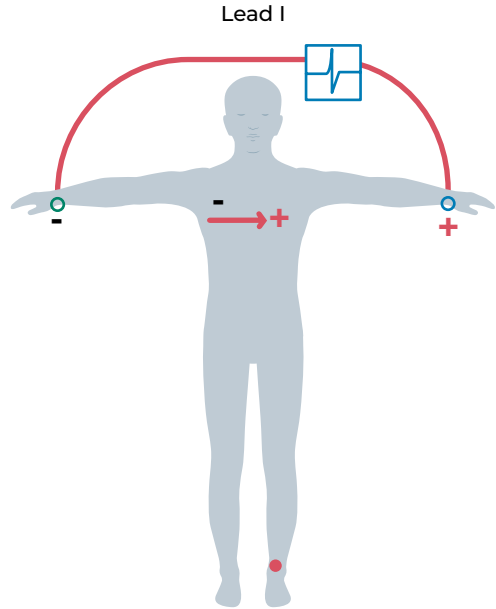
Frontal plane



1.1. Classic or bipolar ECG leads

For the detection of the electrical current there is a negative pole and a positive pole.

- Lead I: positive left upper extremity and negative right upper extremity.
- Lead II: positive left lower extremity and negative right upper extremity.
- Lead III: positive left lower extremity and negative left upper extremity.

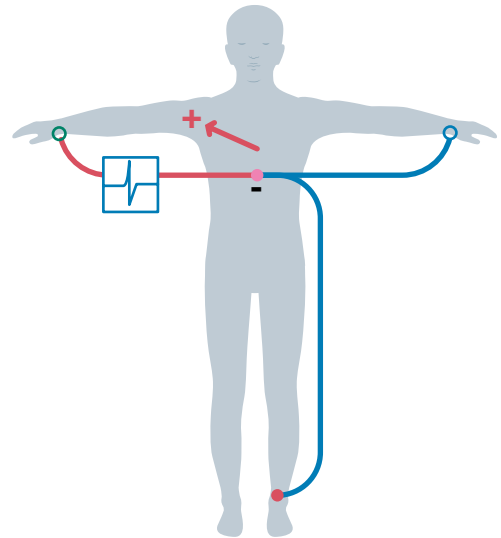


1.2. Augmented unipolar ECG leads

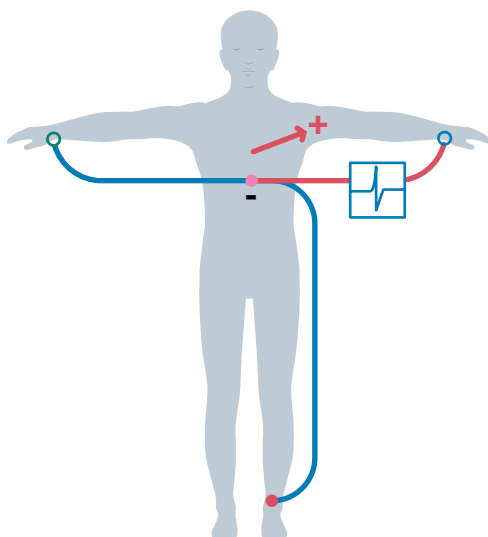
There is a single **positive electrical pole** and a reference point (with 0 electrical potential) located in the center of the cardiac electric field.

- aVR: positive right upper extremity.
- aVL: positive left upper extremity.
- aVF: positive lower extremities.

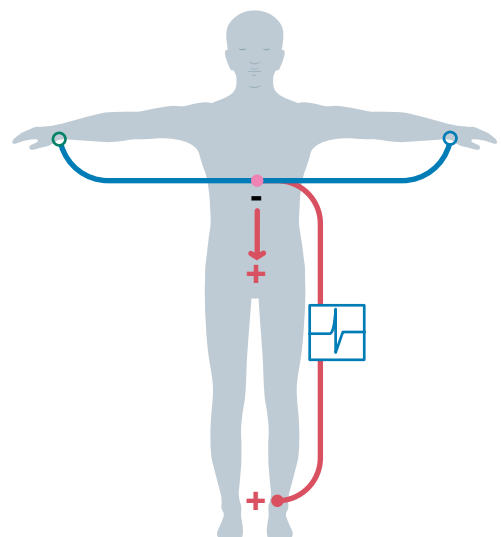
Lead aVR



Lead aVL



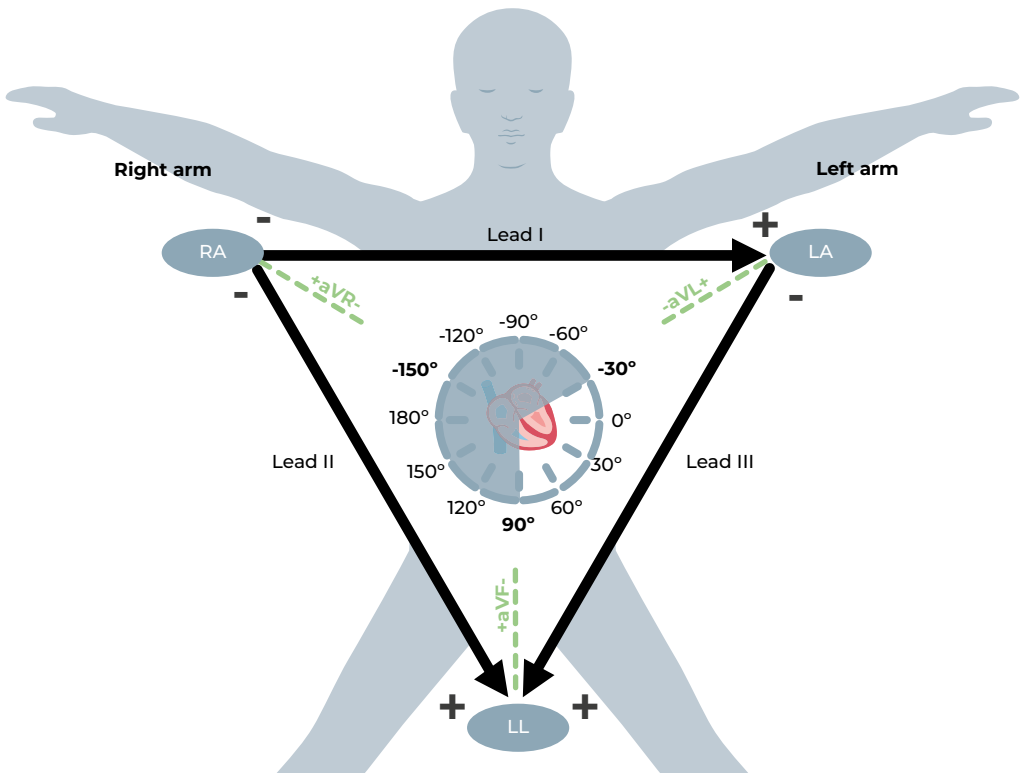
Lead aVF



1.3. Einthoven's Triangle

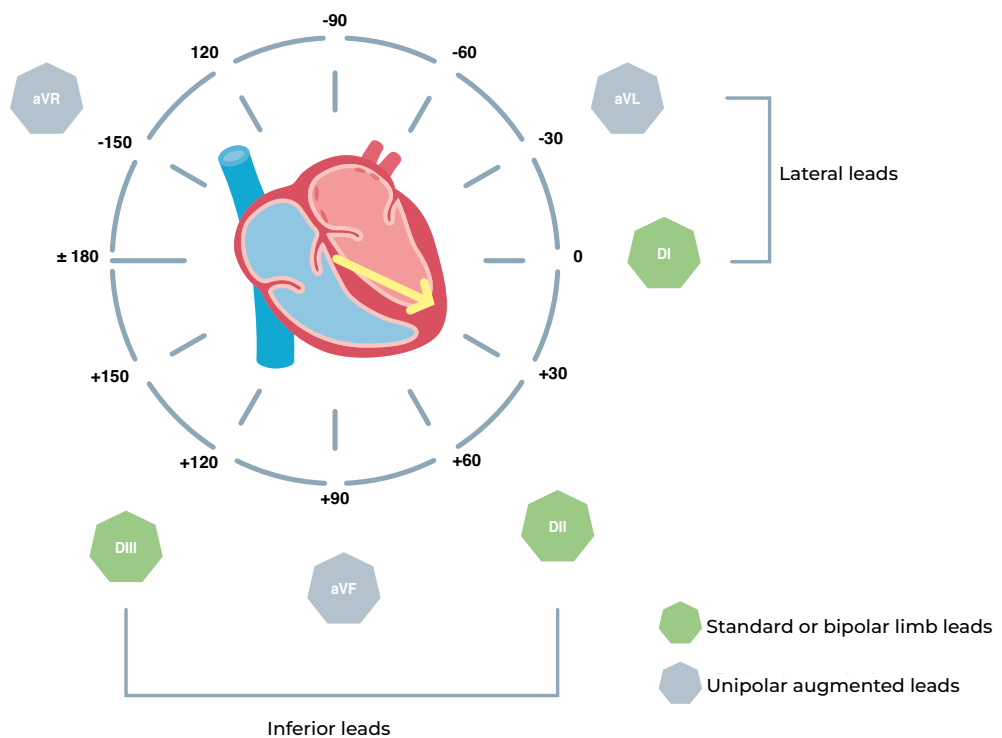
The axes of the **three classic or bipolar ECG leads** (I, II, and III) form the Einthoven triangle.

Since the electrodes are at the same distance from the heart (approximately), the triangle is equilateral.



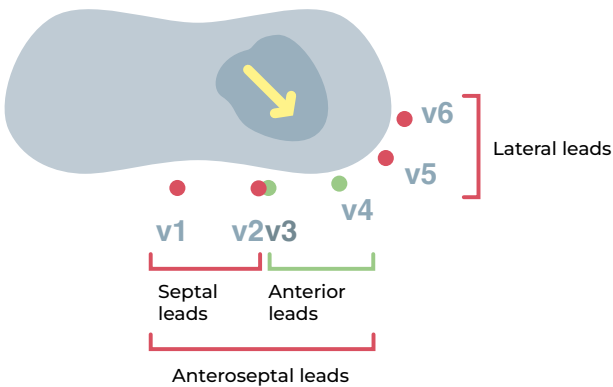
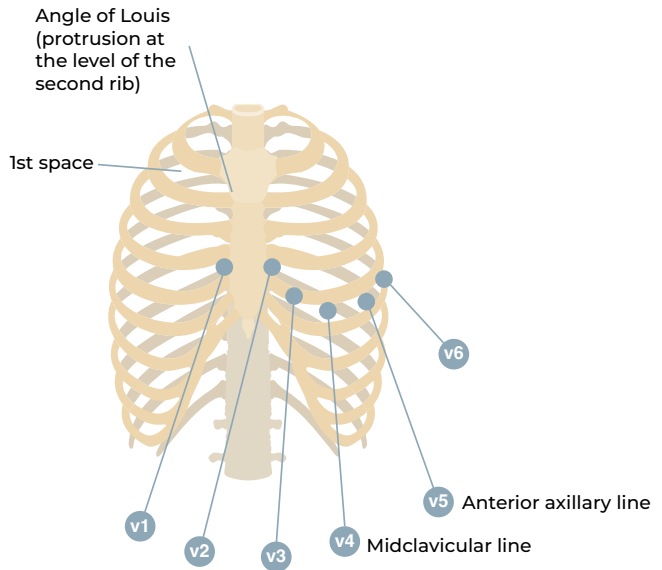
1.4. ECG leads in the frontal plane

In the frontal plane the electrocardiogram it is interpreted with 6 ECG leads.



1.5. Precordial ECG leads

- V1: 4th intercostal space to the right of the sternum.
- V2: 4th intercostal space to the left of the sternum.
- V3: between V2 and V4.
- V4: 5th intercostal space, midclavicular line.
- V5: level with V4 at left anterior axillary line.
- V6: level with V5 at the midaxillary line.



1.6. Regions of the heart analyzed by the different leads

The wall of the right ventricle and the posterior wall of the left ventricle are not well visualized with 6 precordial leads.

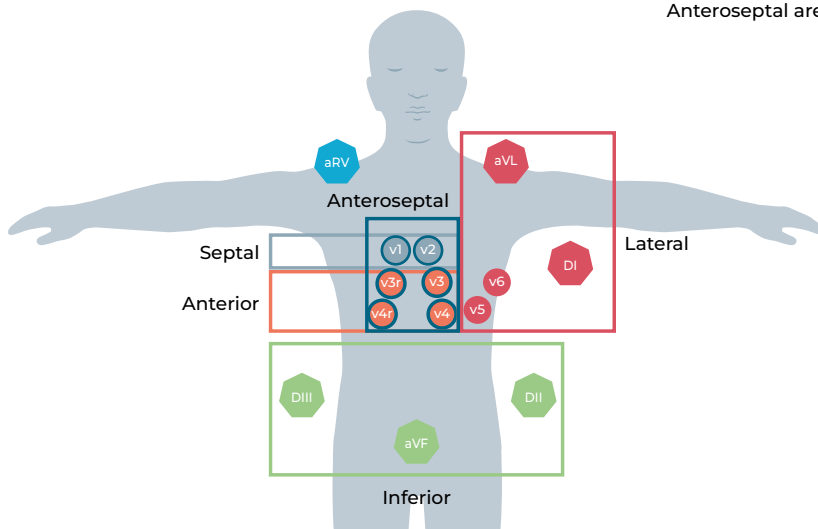
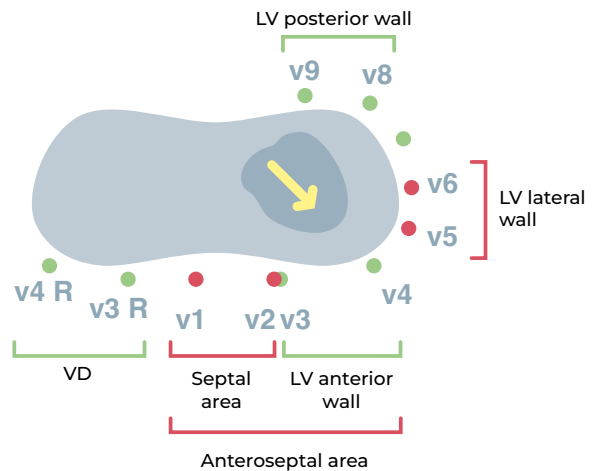
To visualize these areas, additional leads can be added: **V3R, V4R, V7, V8, V9**.

To visualize the right ventricle:

- **V3R**: Between V1 and V4R.
- **V4R**: 5th intercostal space in the right midclavicular line.

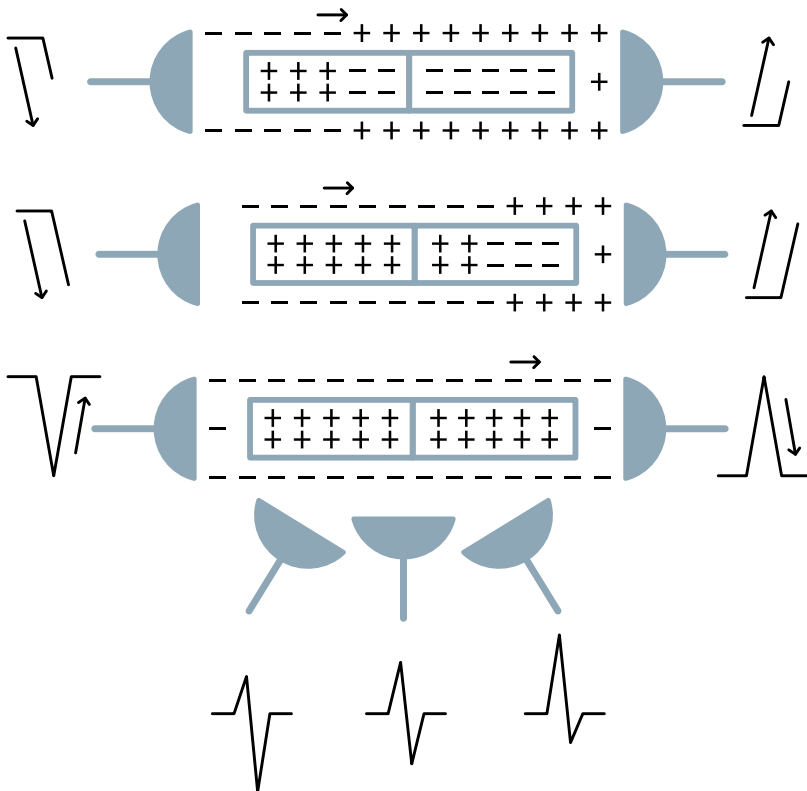
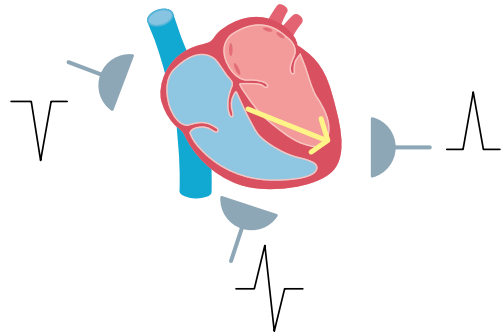
To visualize the posterior wall of the left ventricle:

- **V7**: 5th intercostal space, posterior axillary line.
- **V8**: 5th intercostal space, posterior mid scapular line.
- **V9**: 5th intercostal space, between V8 and the vertebral column.



2. Depolarization

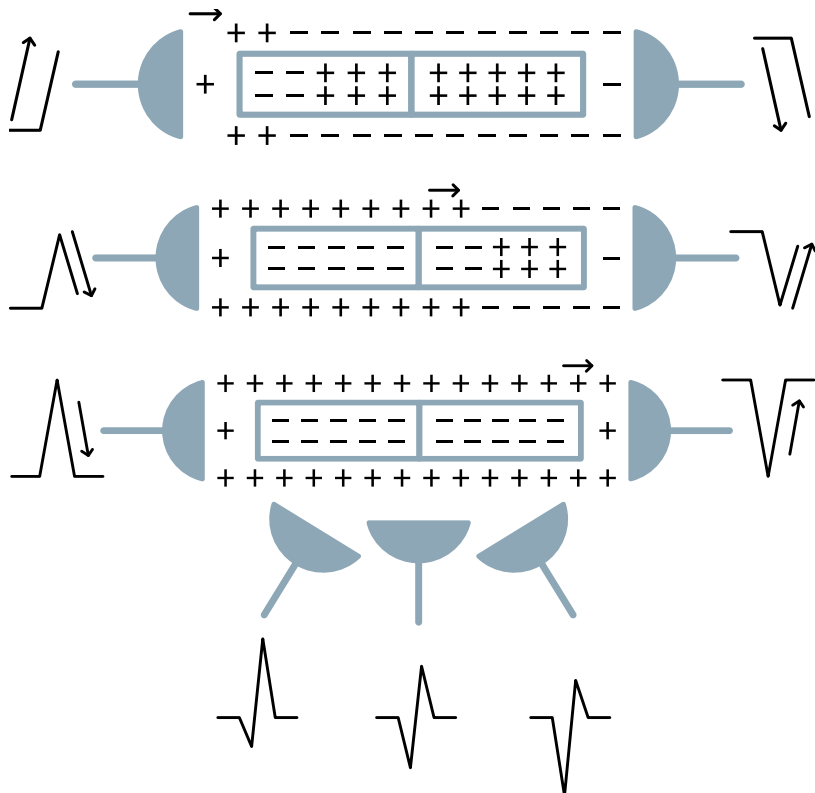
- A **depolarization wave**, positive charges, moving towards the positive electrode will generate a positive wave.
- If it moves away from the positive electrode it will generate a negative wave.
- If the electrical current is perpendicular to the line that joins the positive and negative electrodes, the wave will disappear or will be diphasic.



3. Repolarization

In repolarization the effects are similar but the electrical charges are reversed:

- A **repolarization wave**, negative charges, moving towards the positive electrode will generate a negative wave.
- If it moves away from the positive electrode, it will generate a positive wave.
- If the electrical current is perpendicular to the line that joins the positive and negative electrodes, the wave will disappear or will be diphasic.



THE NORMAL ELECTROCARDIOGRAM



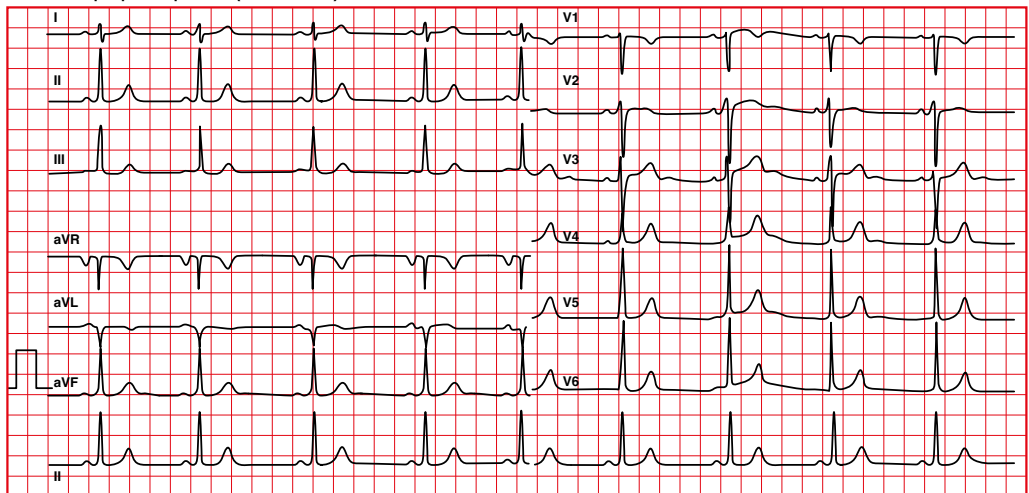
1. Recording

1.1. Paper speed

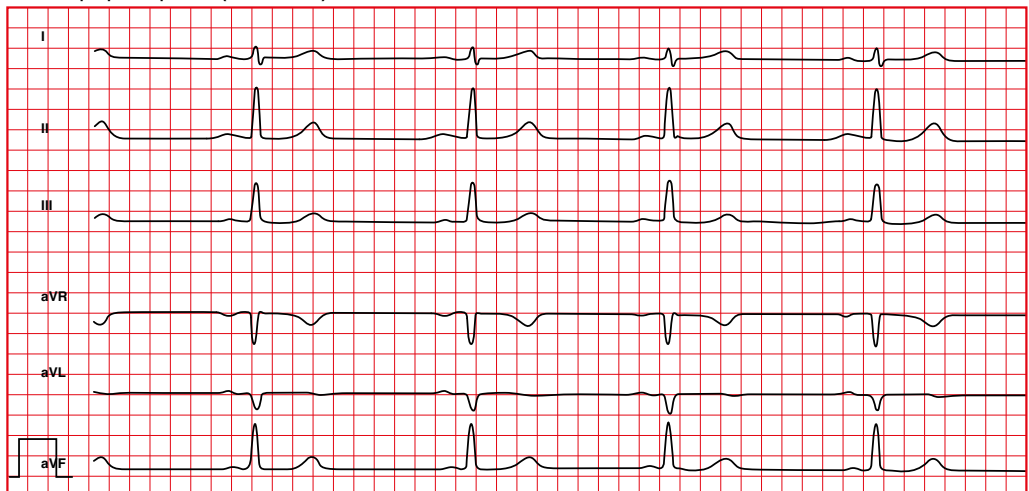
To record a standard electrocardiogram, the paper advances to a pre-established speed of 25 mm/s.

When the speed is not 25 mm/s, all parameters must be corrected.

Normal paper speed (25 mm/s)



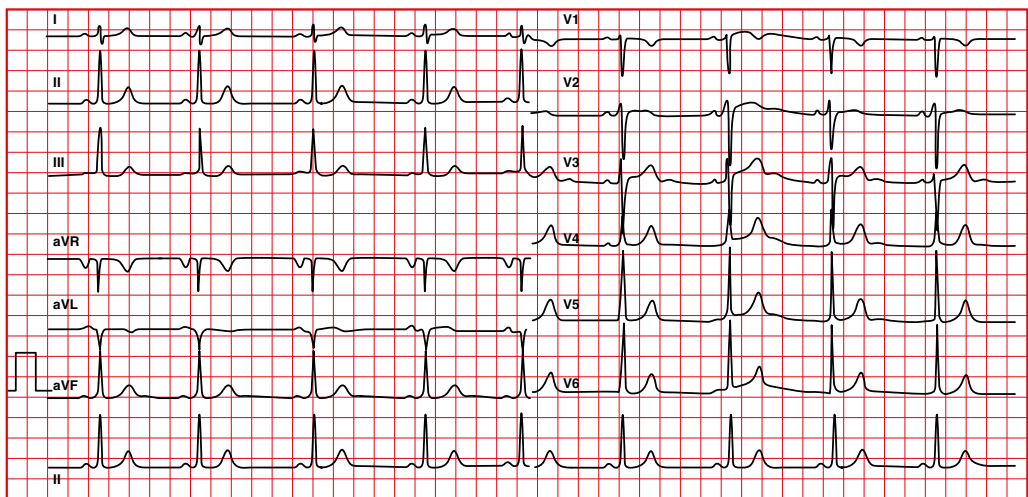
Faster paper speed (50 mm/s)



The normal electrocardiogram

An electrocardiogram usually records the electrical activity during 10 seconds (A to B).

This detail is important to be able to calculate the heart rate when a regular rhythm is not present, as we will see later on.



↑
A

50 large squares
250 mm
10 seconds

↑
B

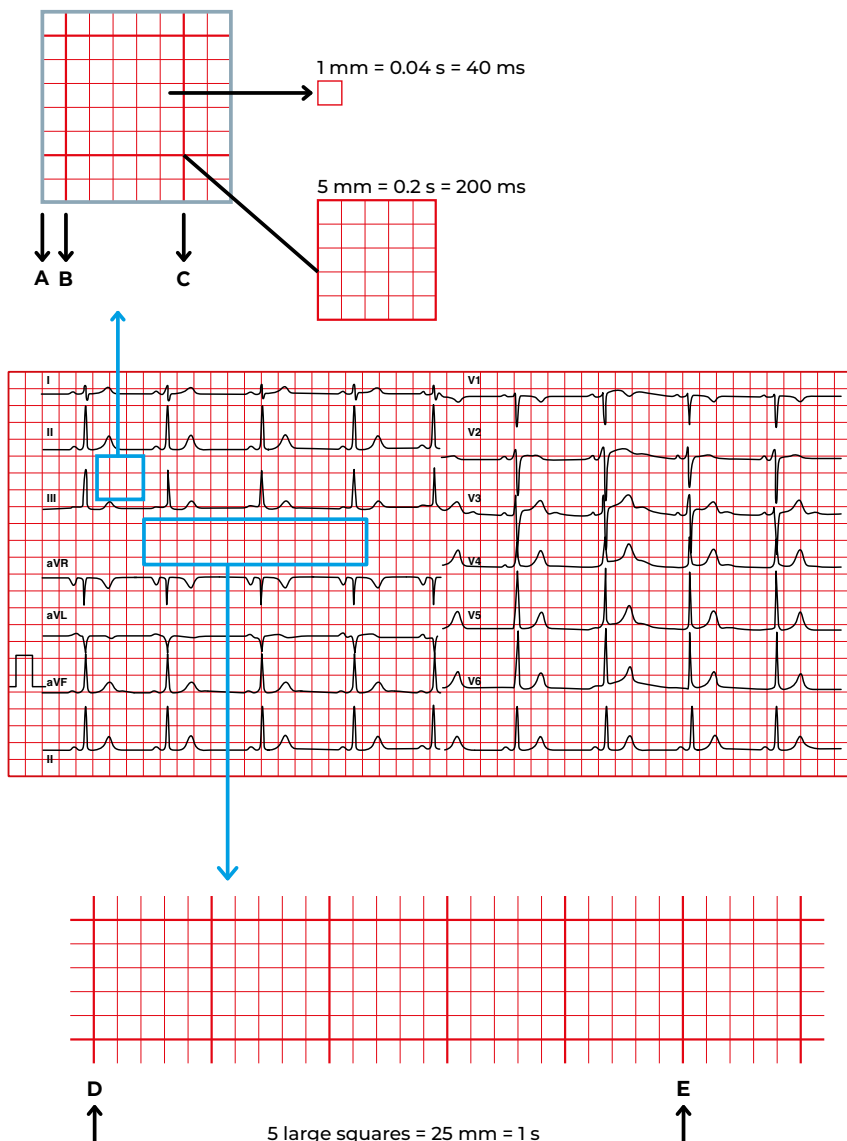
The paper grid of the electrocardiogram allows the calculation of the heart rate.

At a speed of 25 mm/s:

- Each small square (A-B) corresponds to 0.04 seconds (40 milliseconds).

- Each large square (B-C) corresponds to 0.2 seconds (200 milliseconds).

- Every 5 large squares (D-E) correspond to 1 second.



1.2. Continuous or discontinuous recording?

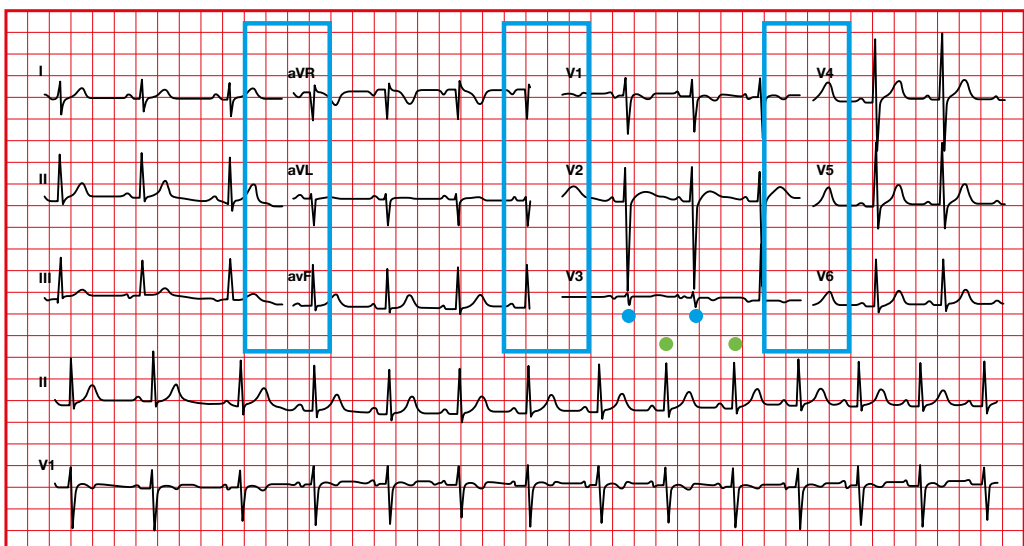
- An electrocardiogram is not necessarily recorded for 10 seconds. It is possible that all leads are recorded, separate or in group, only for a few seconds and placed side by side.
- It can be detected by assessing whether there is solution of continuity in the ecg tracing.

Discontinuous layout

In this electrocardiogram you can see solution of continuity.

The rhythm strip complexes do not match the electrocardiogram complexes (blue and green dots).

Therefore this is an electrocardiogram recorded in groups of 3 leads.



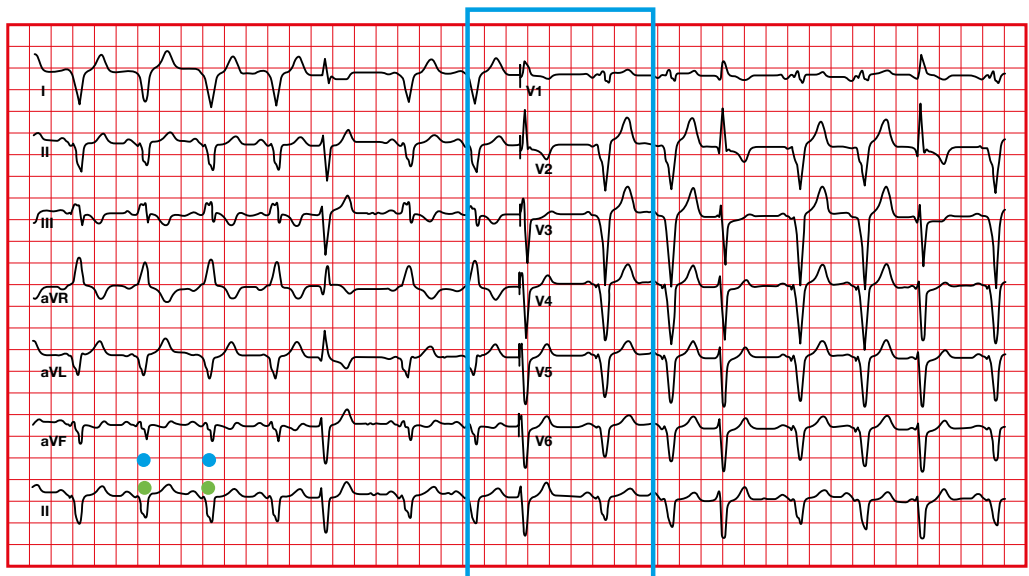
When the rhythm is not regular, either a continuous-wave electrocardiogram or the rhythm strip on a discontinuous-wave electrocardiogram (usually available on the recorded electrocardiogram) should be used to calculate heart rate.

Continuous layout

In this electrocardiogram you can see no solution of continuity.

The rhythm strip complexes match the electrocardiogram complexes (blue and green dots).

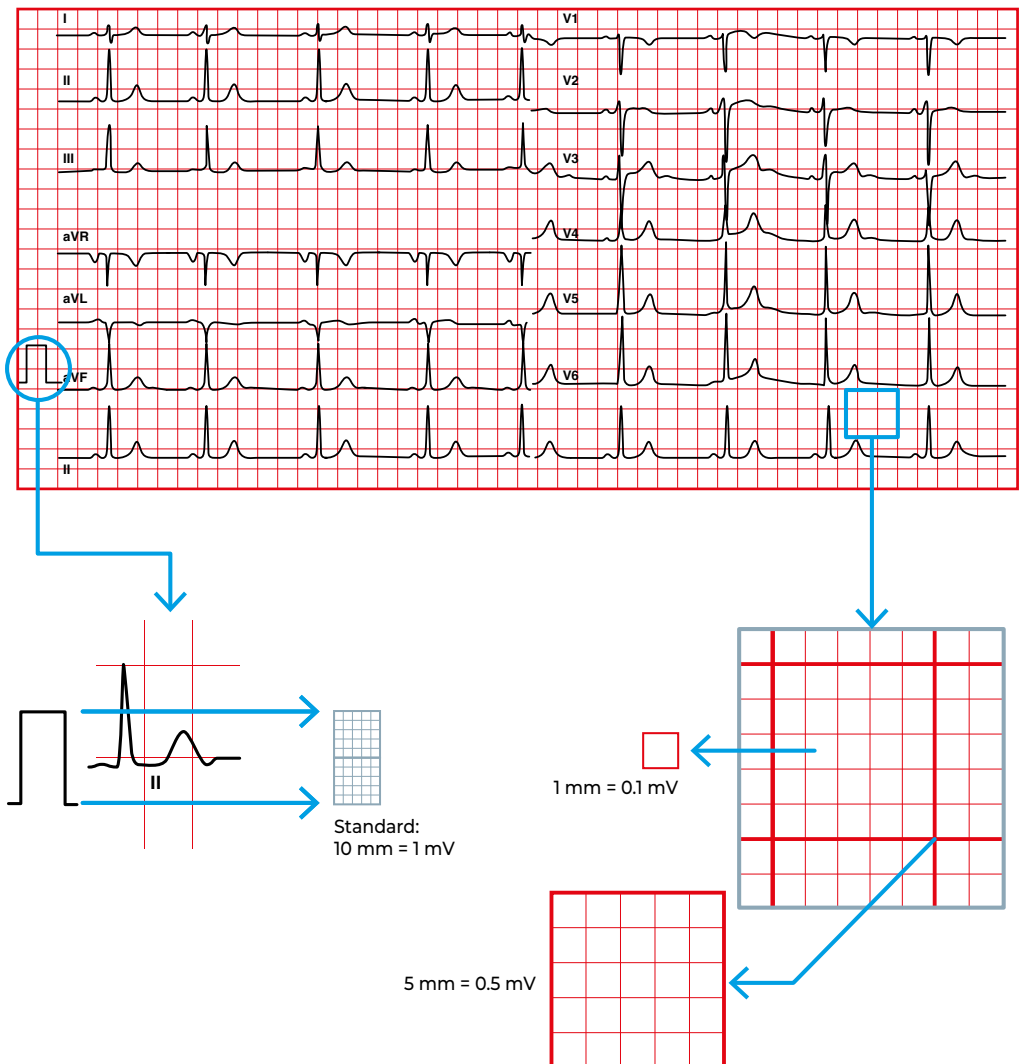
Therefore, this is a continuous electrocardiogram for 10 seconds.



1.3. Calibration

The horizontal lines of the electrocardiogram allow the determination of the amplitude or voltage of the waves.

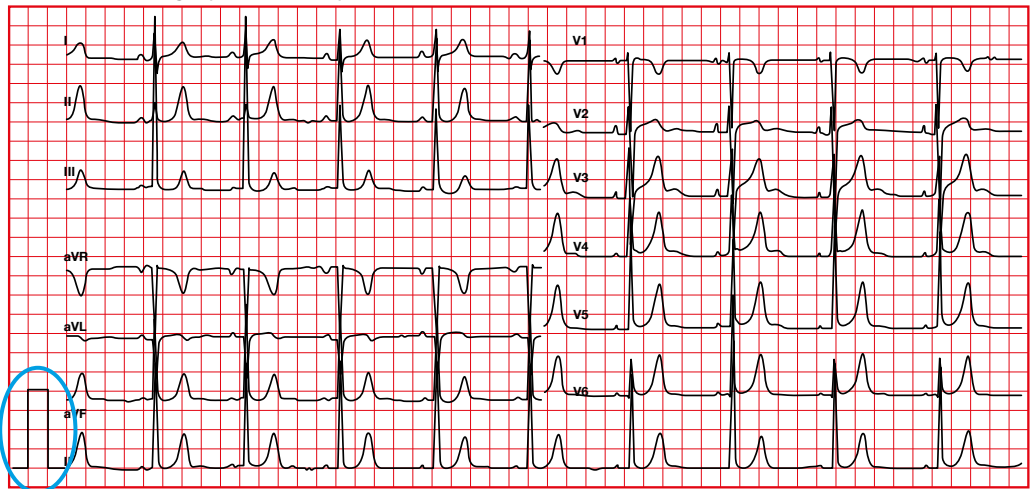
At the standard 10 mm/mV calibration (as shown in the image), each thin line (1 mm) corresponds to 0.1 mV.



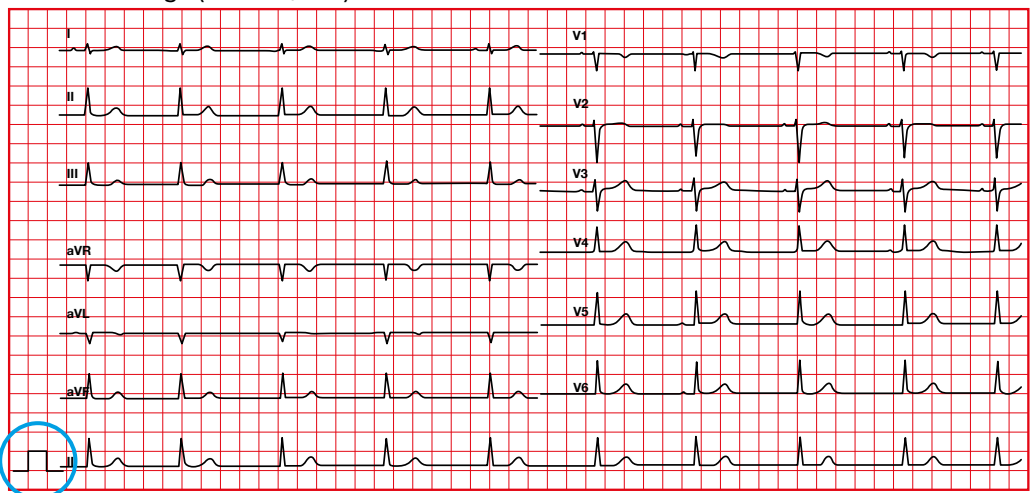
Calibration is used to modulate the amplitude of the ECG waves and complexes.

When the calibration is not 0.1 mV/mm, all parameters must be corrected.

Increased voltage (0.2 mV/mm)



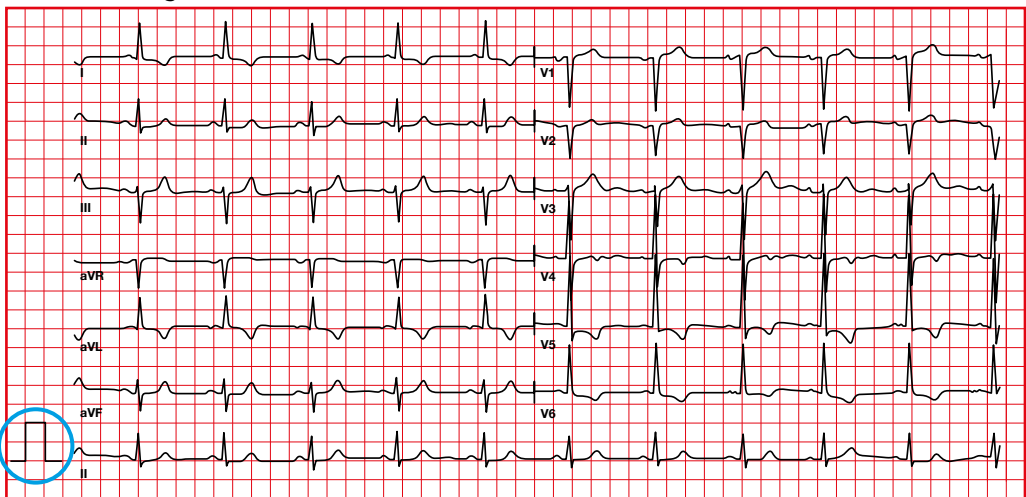
Reduced voltage (0.05 mV/mm)



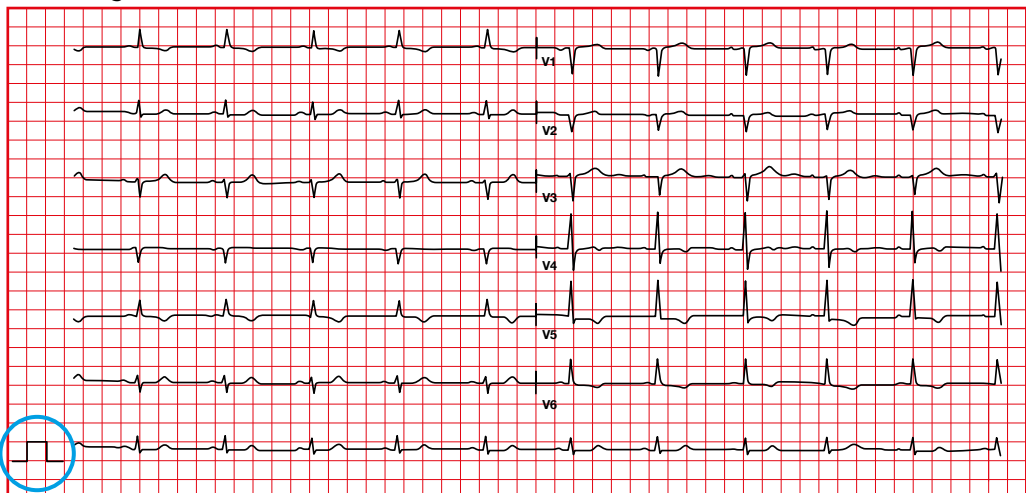
The normal electrocardiogram

The change in calibration is used when the QRS complexes are too high and interfere with the evaluation of the electrocardiogram (for example in cardiac hypertrophy).

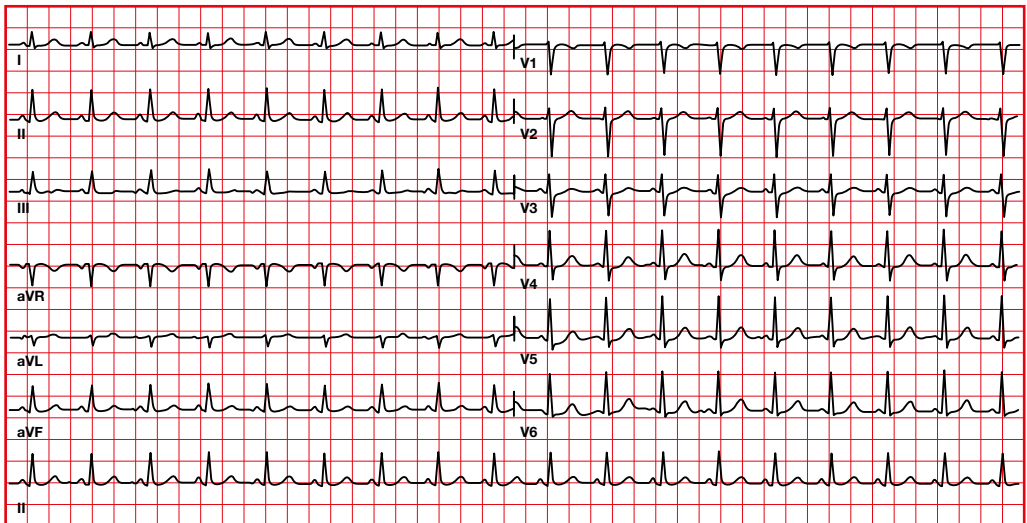
Standard voltage calibration



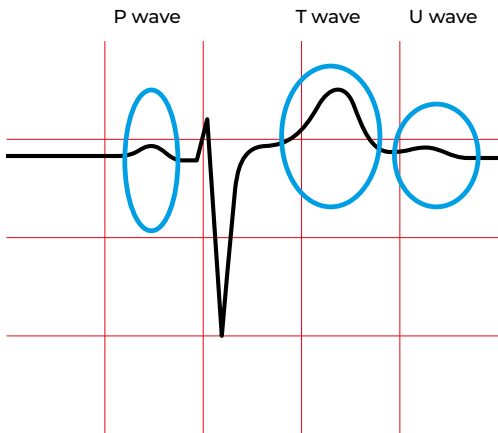
Low voltage calibration



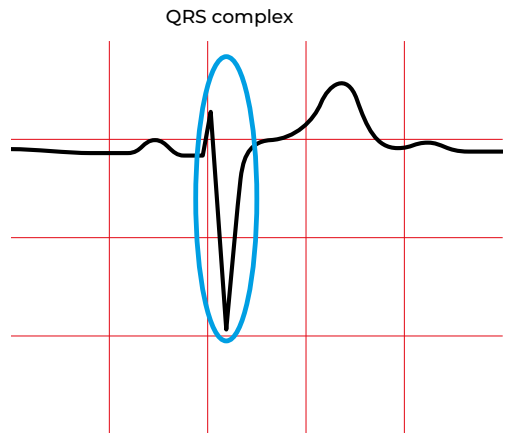2. The electrocardiogram: waves, complexes, segments and intervals



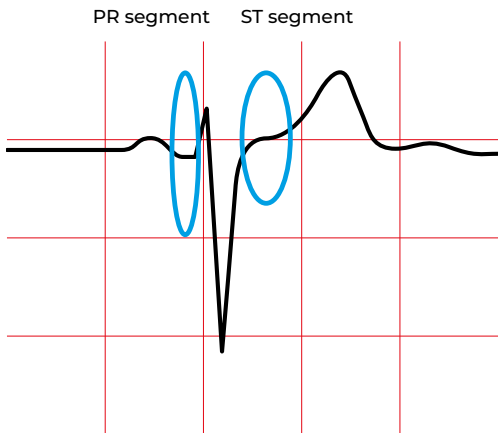The normal electrocardiogram



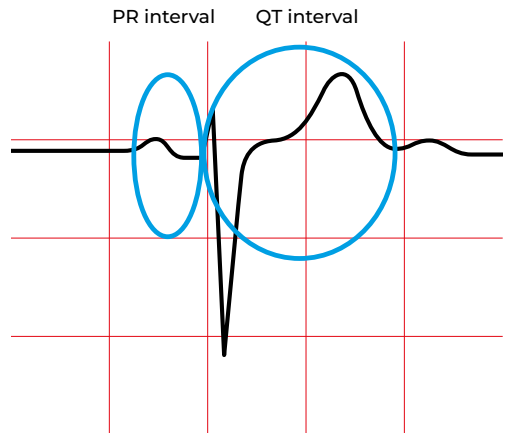
Wave: positive or negative deflection in the electrocardiogram



Complex: several waves



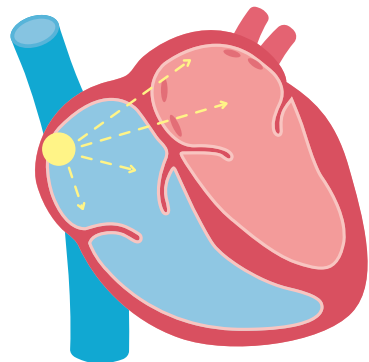
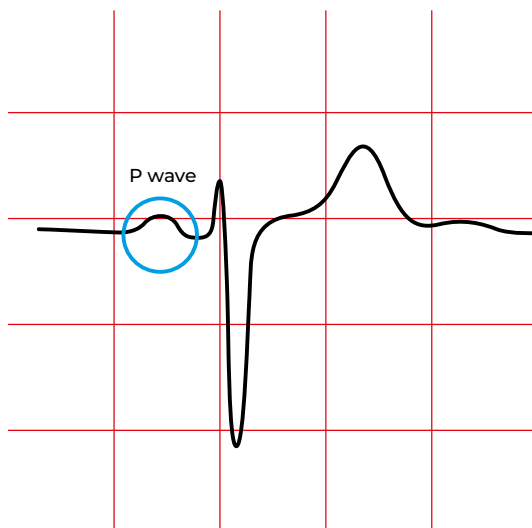
Segment: lines between waves and complexes



Interval: it contains segments, waves and complexes

2.1. P wave

- The P wave of the ECG represents **depolarization of the atria** (not of the sinus node).
- Under normal conditions it starts in the sinus node, located in the upper part of the right atrium. Thus, we have a **sinus P** wave.

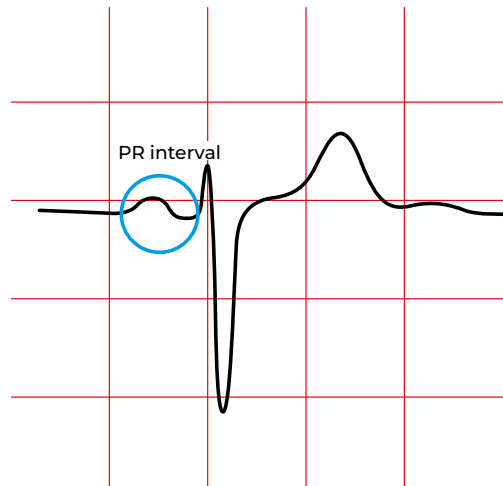
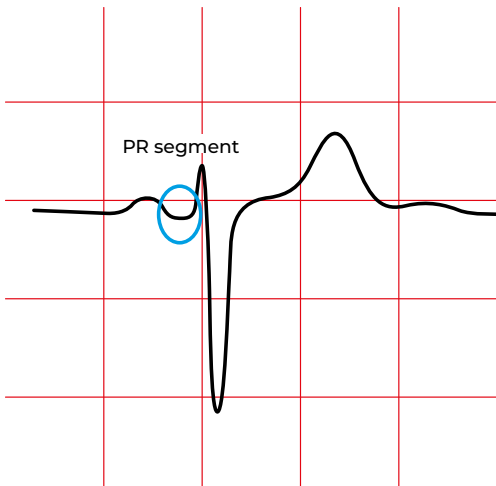


2.2. PR Segment

- From the end of the P wave to the beginning of the QRS.
- Time since the end of the **atrial depolarization** up to the beginning of **ventricular depolarization**.
- The PR segment is usually isoelectric, with an elevation < 0.5 mm and a depression < 0.8 mm.

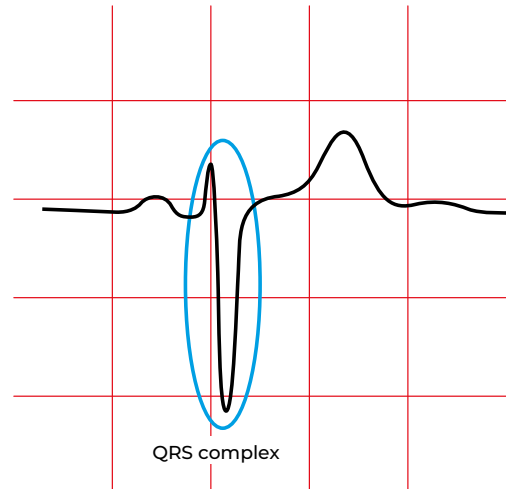
2.3. PR Interval

- From the beginning of the P wave to the beginning of the QRS.
- Time since the start of the **atrial depolarization** up to the start of **ventricular depolarization**.
- It is the time necessary for the impulse to go from the myocardium adjacent to the sinus node up to the Purkinje fibers at the ventricular level.
- An important portion of the PR interval corresponds to the slow conduction through the atrioventricular node.
- The PR interval changes with cardiac frequency, becoming shorter at higher frequencies.

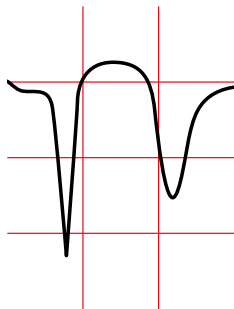


2.4. QRS complex

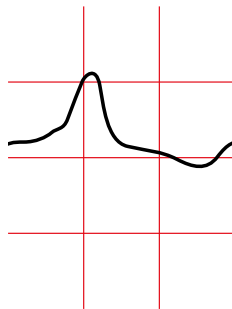
On the electrocardiogram, the QRS complex represents **ventricular depolarization**.



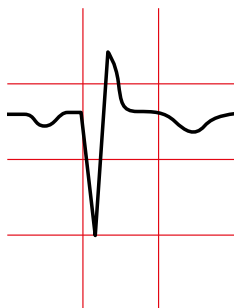QS (all negative)



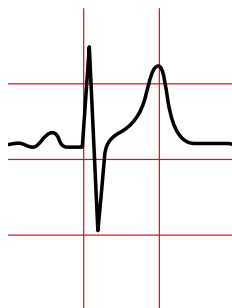R (all positive)



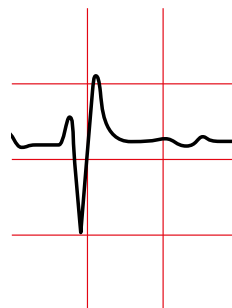
QR (biphasic)



RS (isodiphasic)

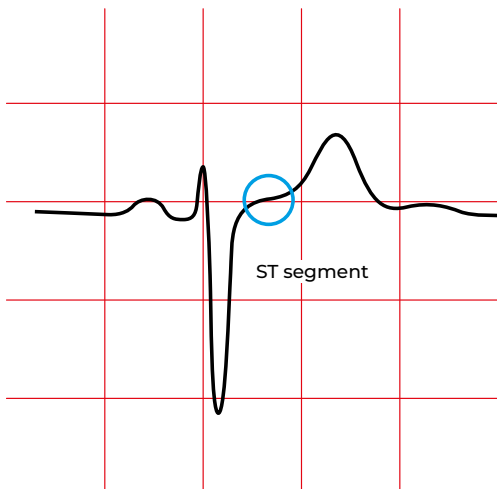


rSR' (triphasic)



2.5. ST segment

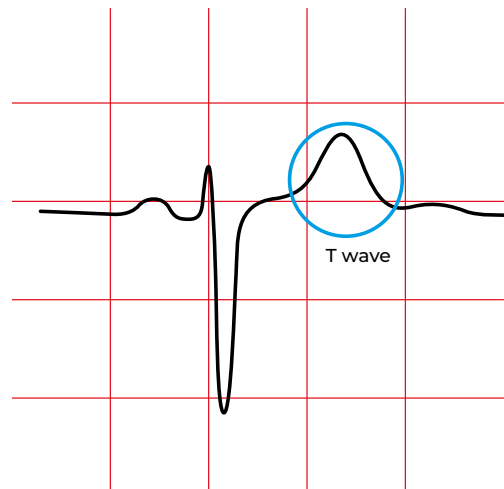
The ST segment represents time since the end of **ventricular depolarization** (J point) until the onset of the T wave.



2.6. T wave

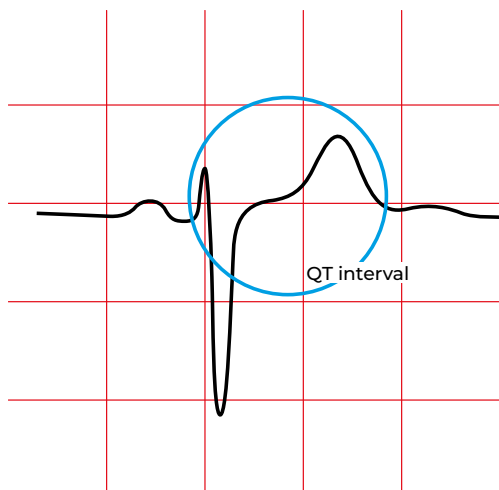
The T wave represents the **repolarization of the ventricles**.

(The atrial repolarization wave is hidden within the QRS.)



2.7. QT interval

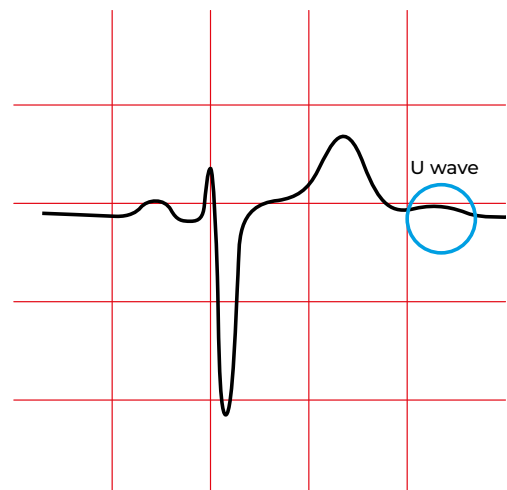
The QT interval measures the duration of ventricular myocardium activation and recovery. Therefore, it spans from the beginning of **ventricular depolarization** until the end of **ventricular repolarization**.



2.8. U wave

There is controversy about what the U wave represents .

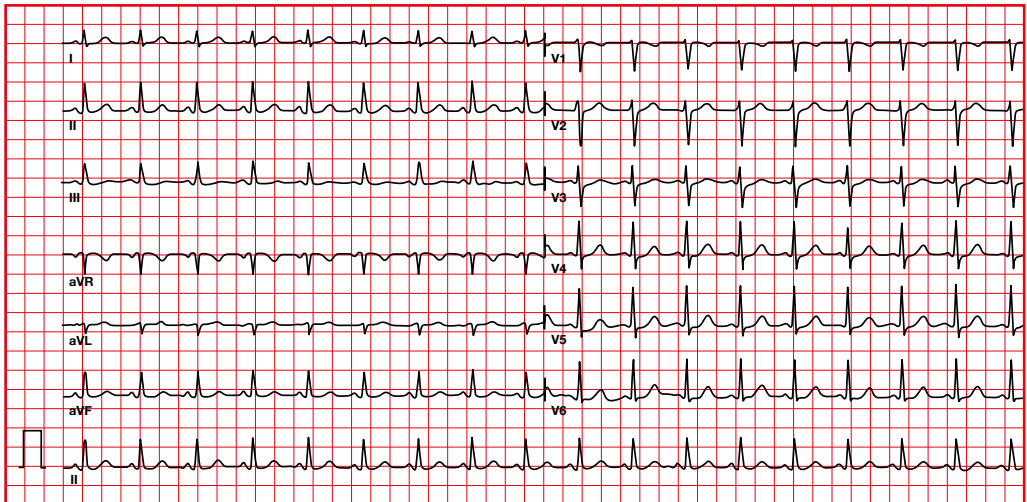
It is believed to represent either the **repolarization of the papillary muscle** or of the **Purkinje fibers**.



SYSTEMATIC ASSESSMENT OF THE ELECTROCARDIOGRAM

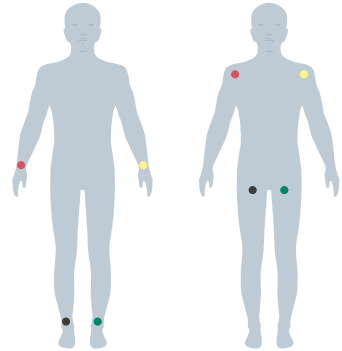


1. Alterations in the recording

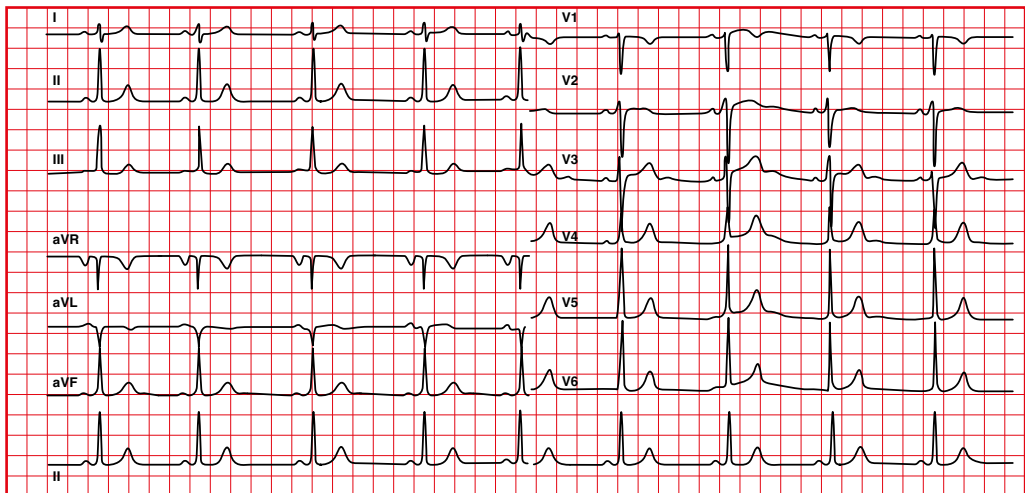


1.1. Electrode lead placement using Mason-Likar system (limb leads shifted to the torso)

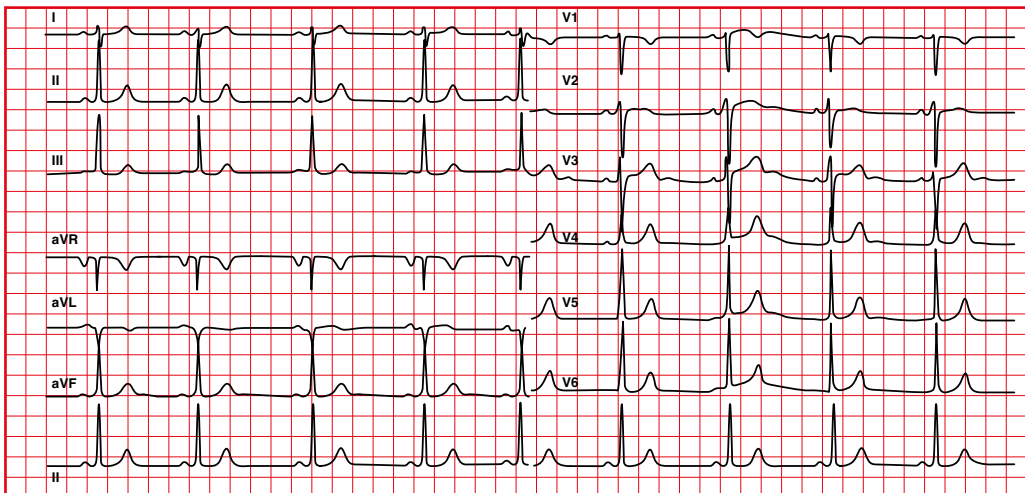
- Deviation of the axis to the right, with loss of R in I and aVL and increase of R in II, III and aVF.
- Normal progression in precordial leads.



At the limbs

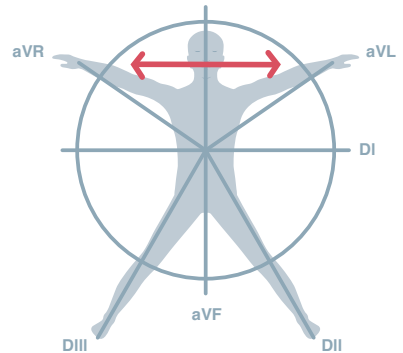


At the torso

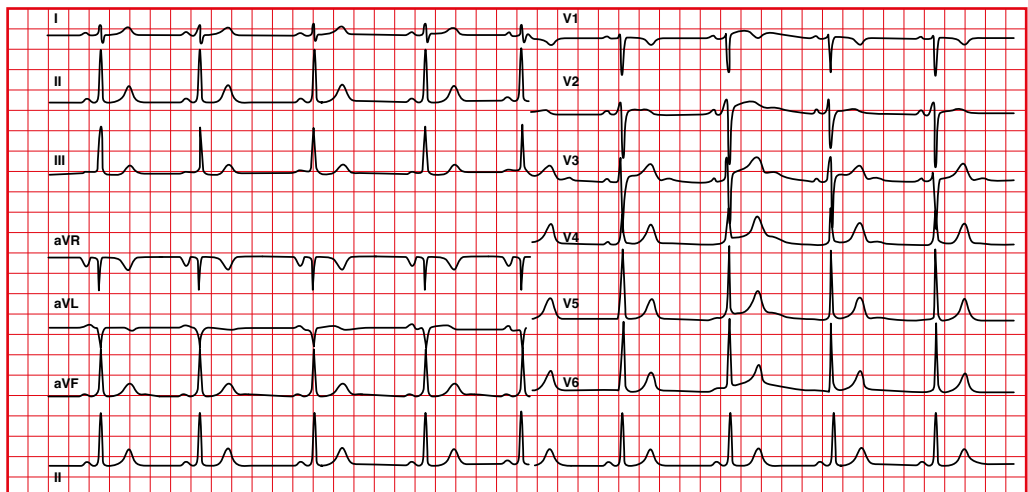


1.2. Right arm to left arm lead reversal

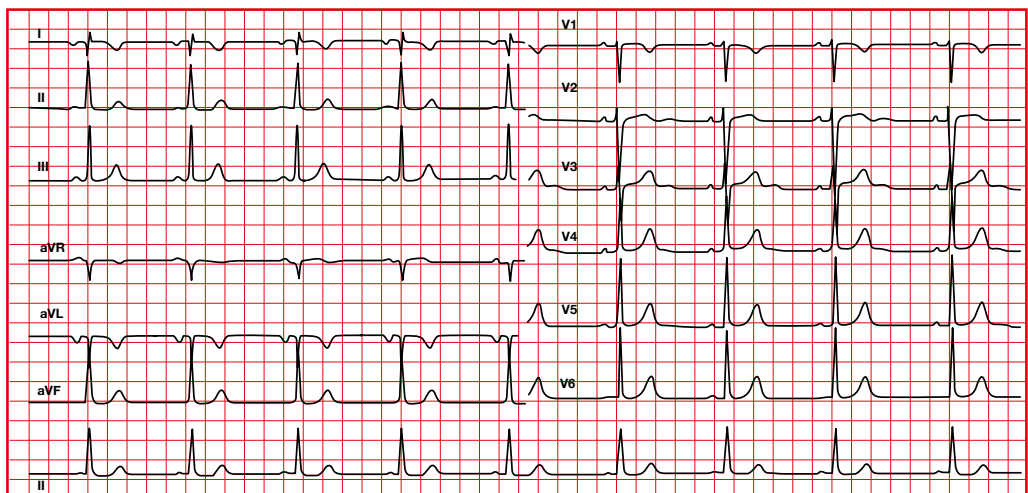
- Deviation of the axis to the right, with negative P, QRS and T in lead I.
- Normal progression in precordial leads.



Normal

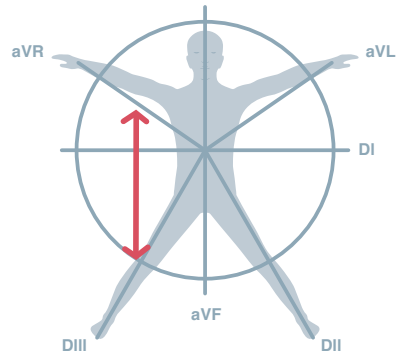


RA-LA

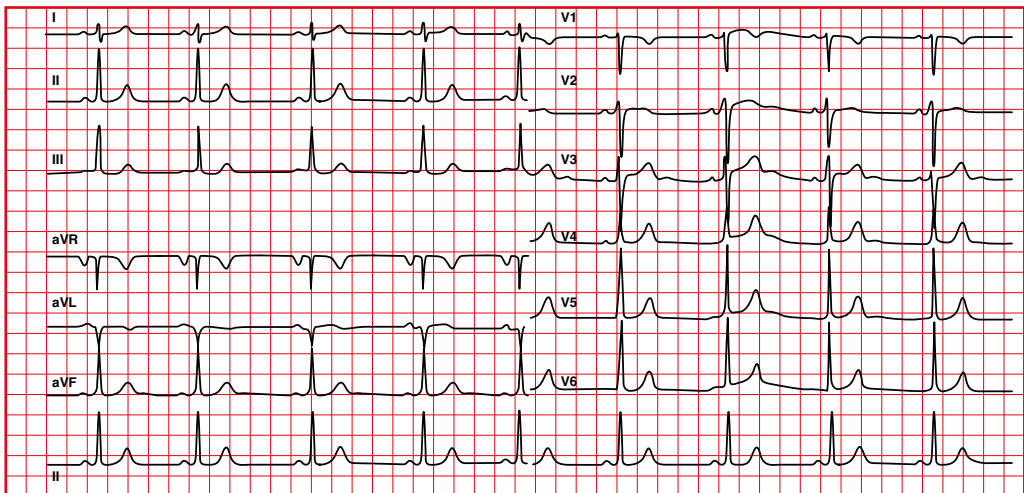


1.3. Right arm to right leg lead reversal

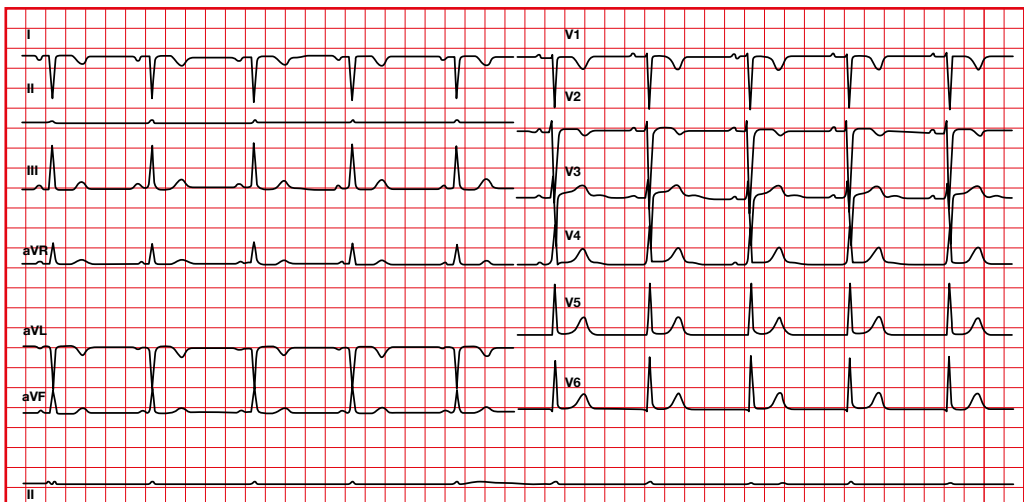
- Right axis deviation, with negative QRS in I.
- Minimum voltage in II.
- Precordials a little altered.



Normal

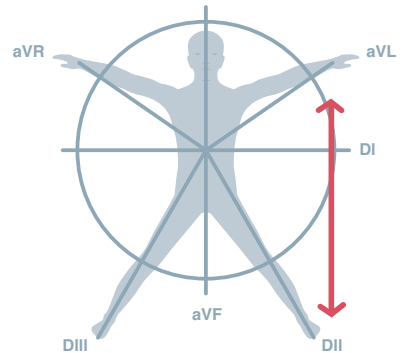


RA-RL

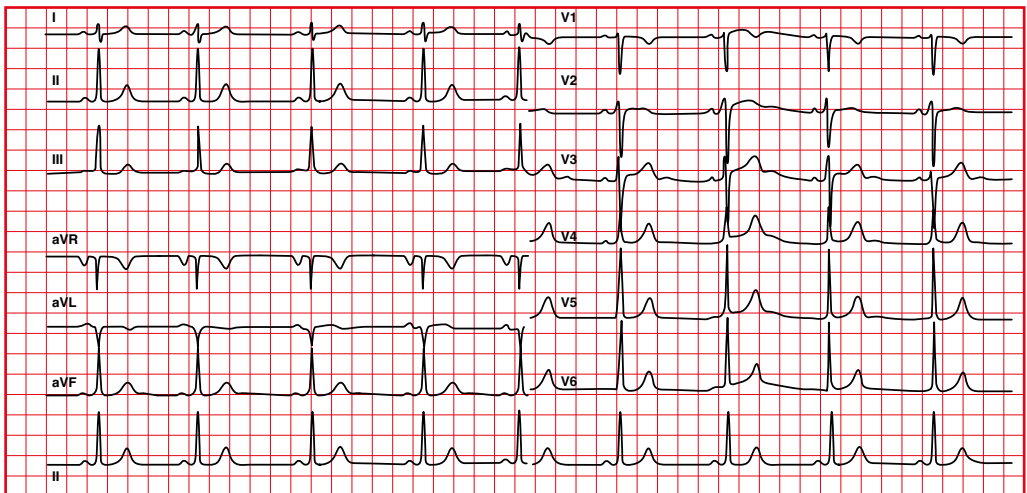


1.4. Left arm to left leg lead reversal

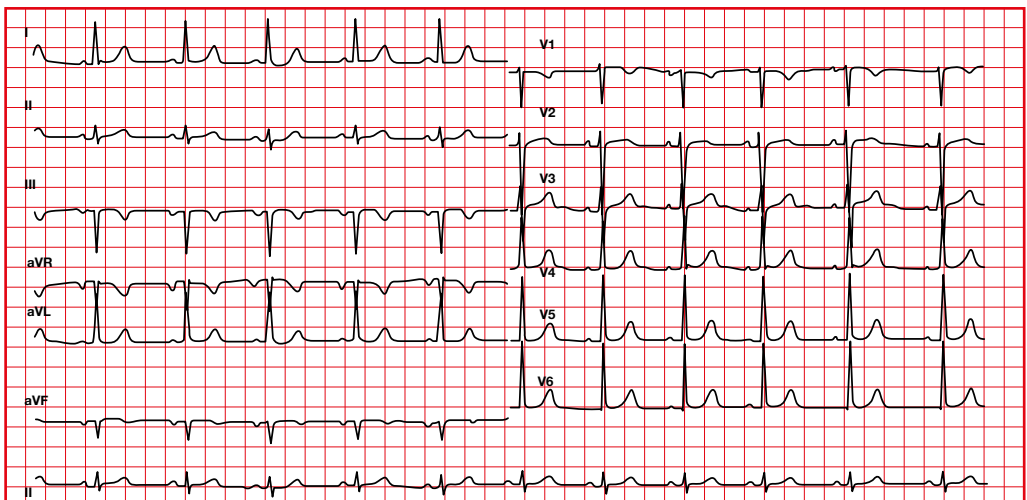
- III and aVF become negative.
- aVL becomes positive.



Normal

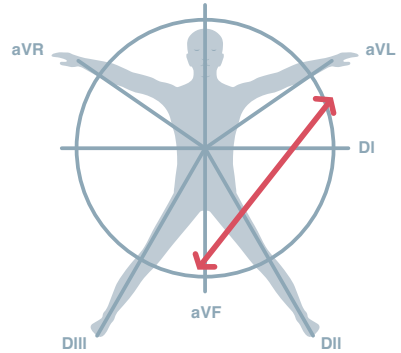


LA-LL

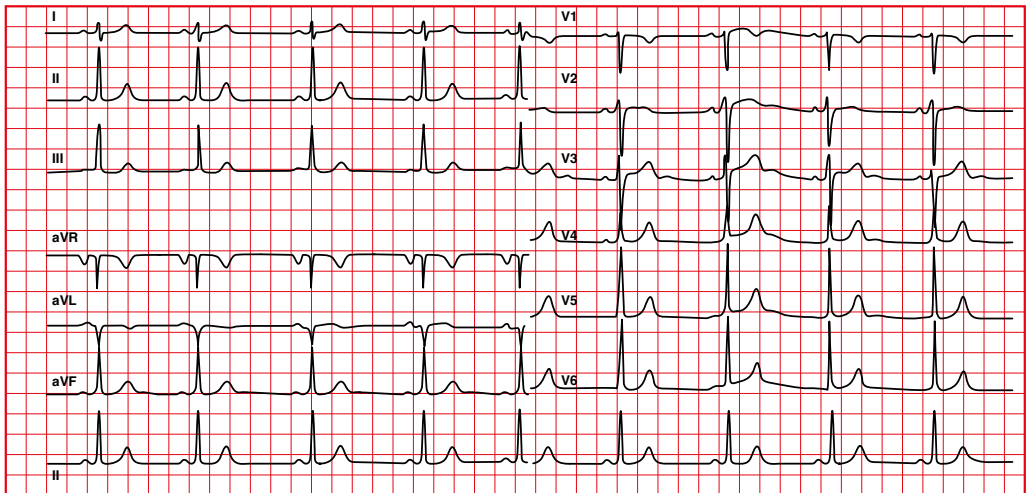


1.5. Right leg to left arm lead reversal

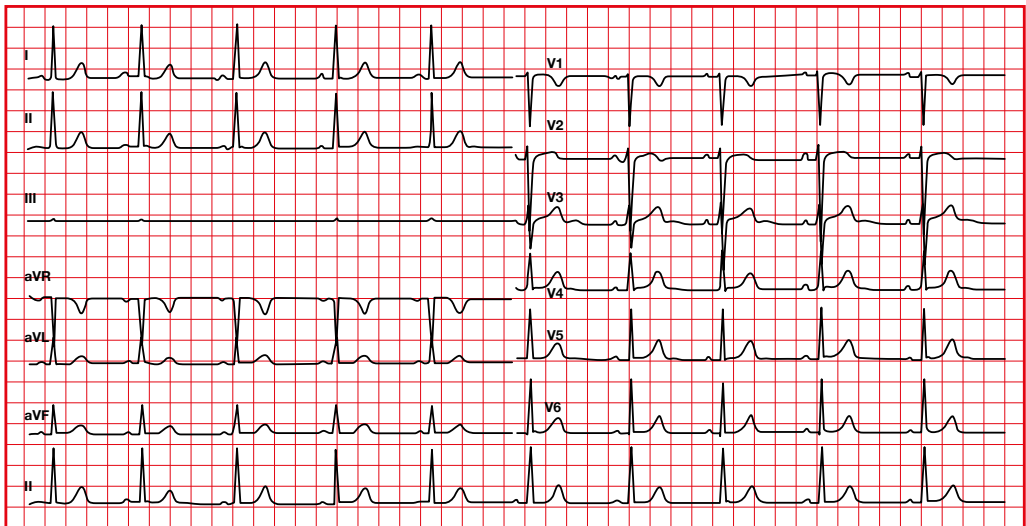
Minimal voltage in III.



Normal

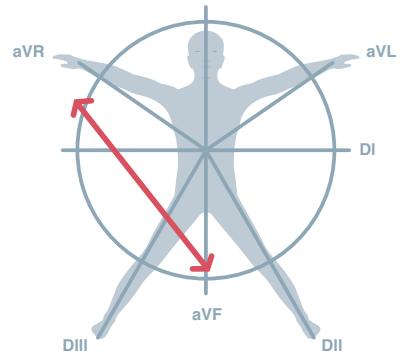


RL-LA

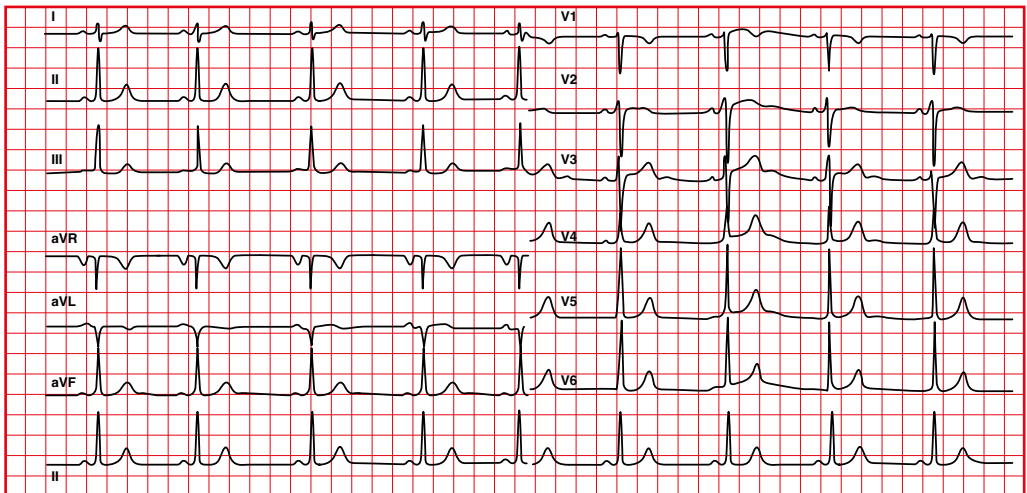


1.6. Right arm to left leg lead reversal

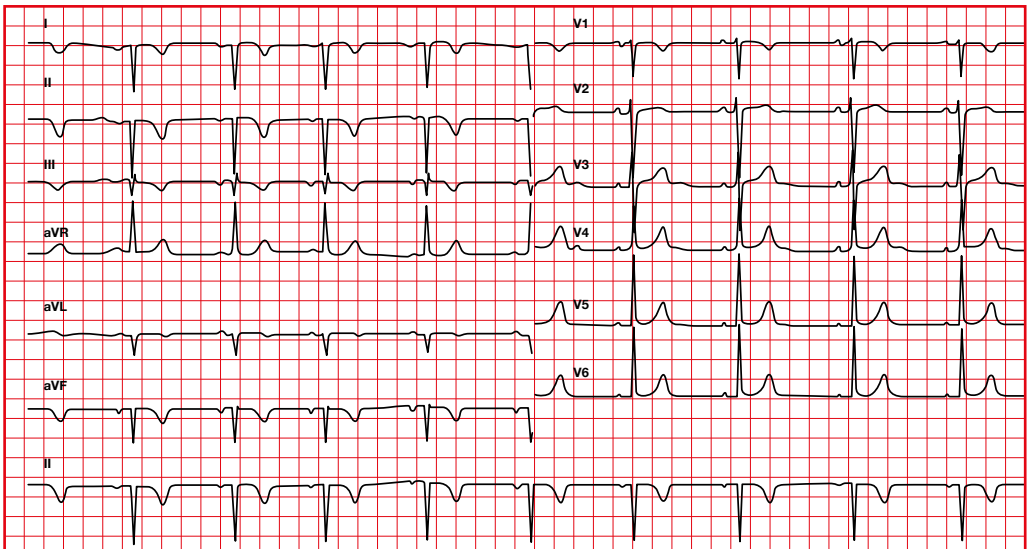
I, II, III, aVR and aVF are inverted.



Normal

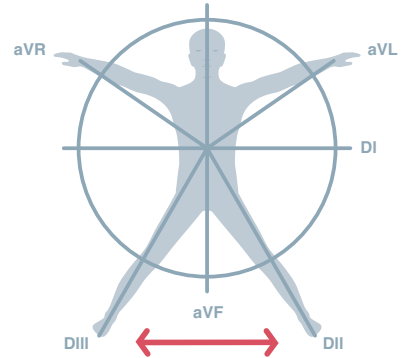


RA-LL

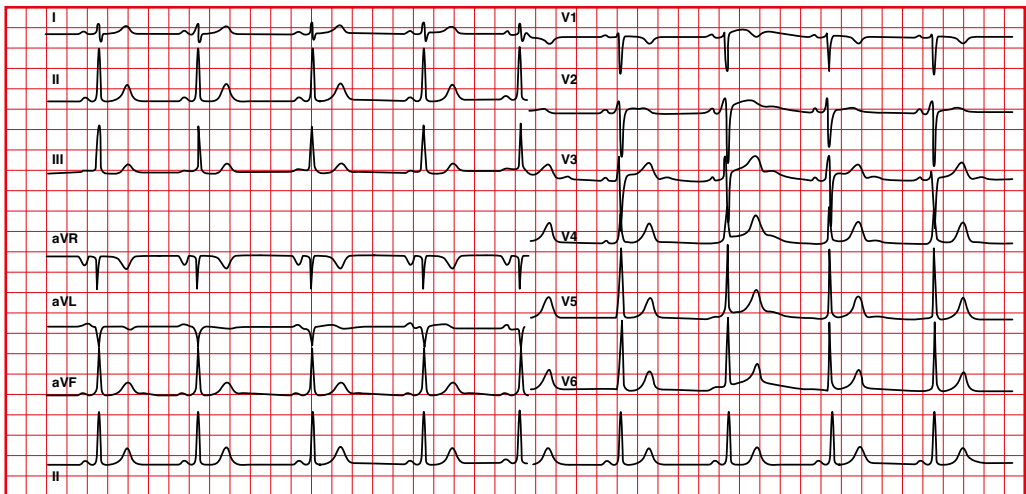


1.7. Right leg to left leg lead reversal

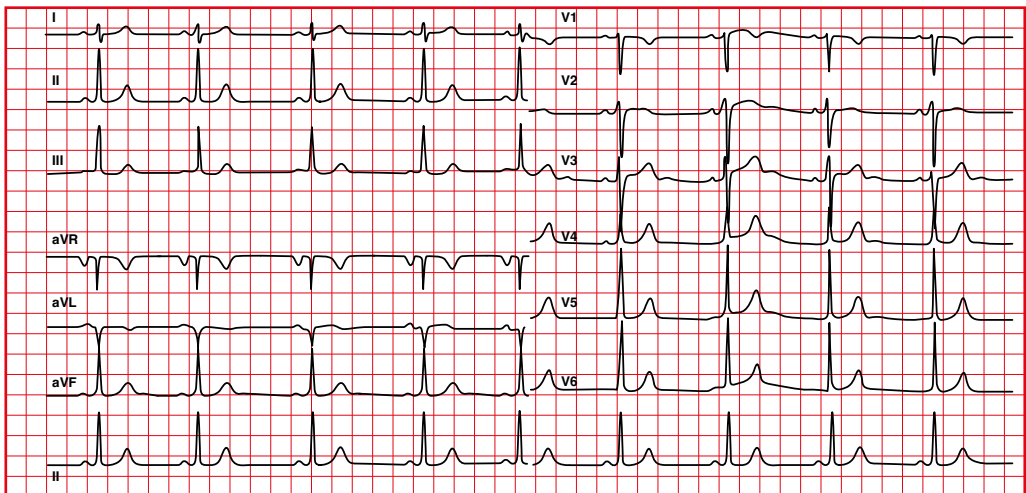
No changes.



Normal



RL-LL

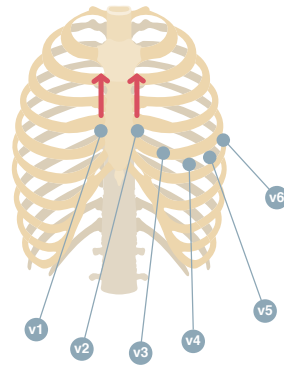


1.8. Higher precordial lead placement

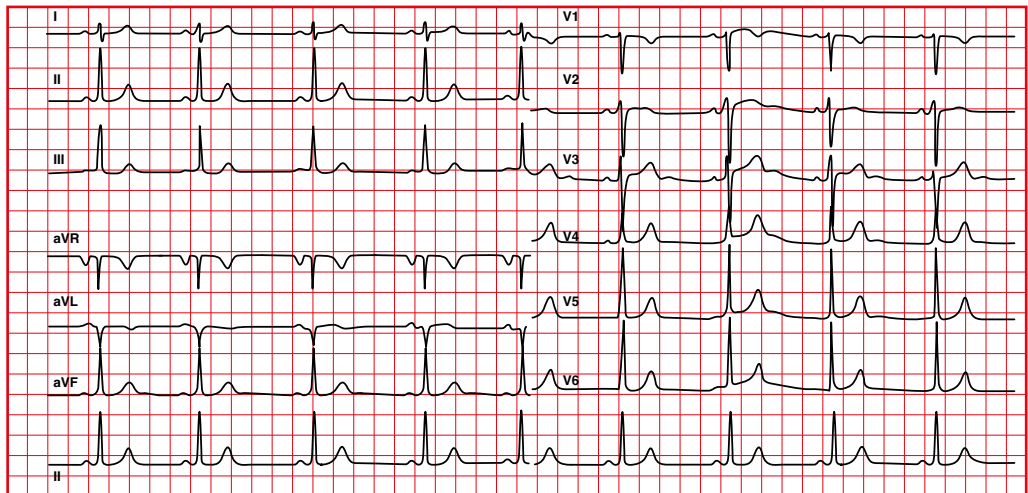
In the normal position, in V1 the P wave is positive or biphasic.

Too high placement of V1, V2.

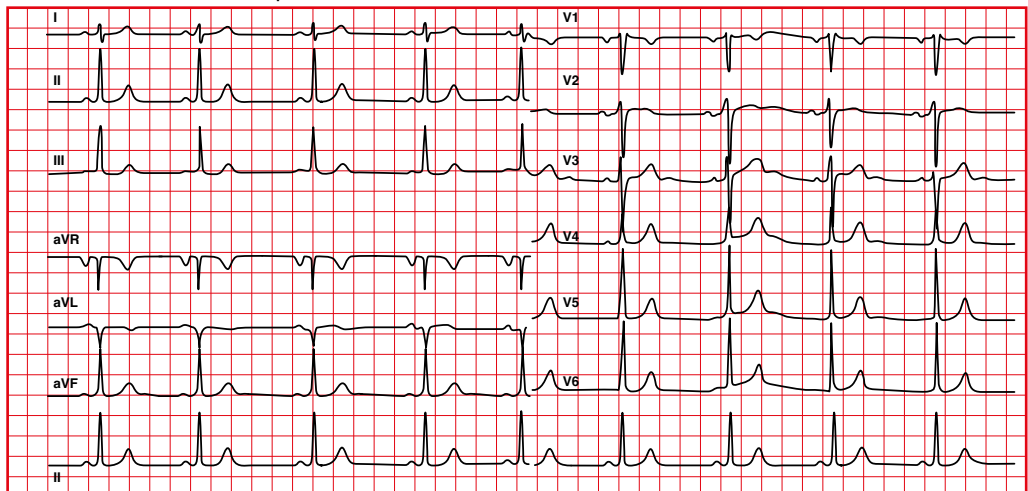
- V1: an only negative P wave, often with RSR'.
- V2: P wave with a negative final portion.



Normal



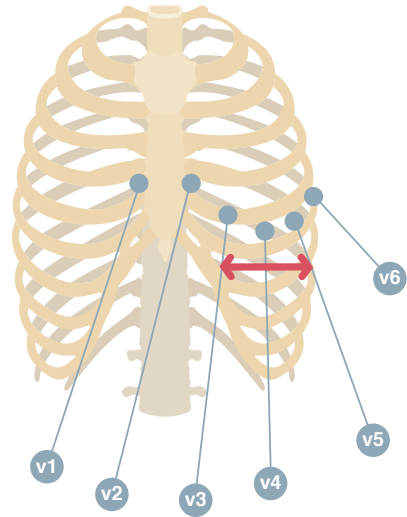
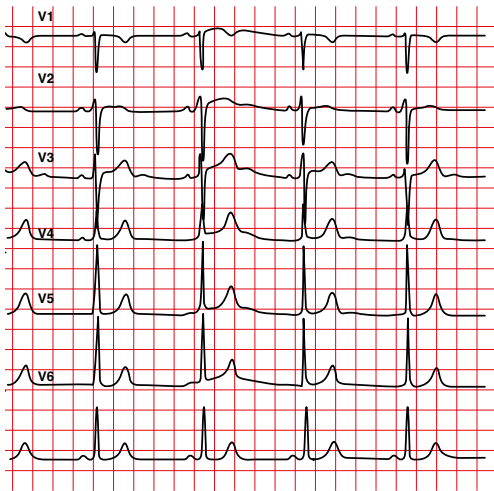
V1-V2 in 2nd intercostal space



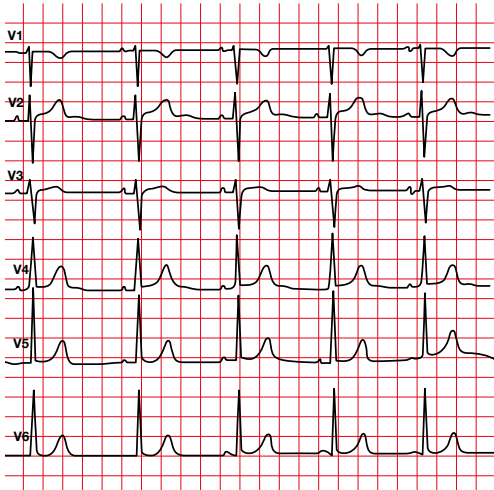
1.9. Precordial lead reversal

R wave progression is lost.

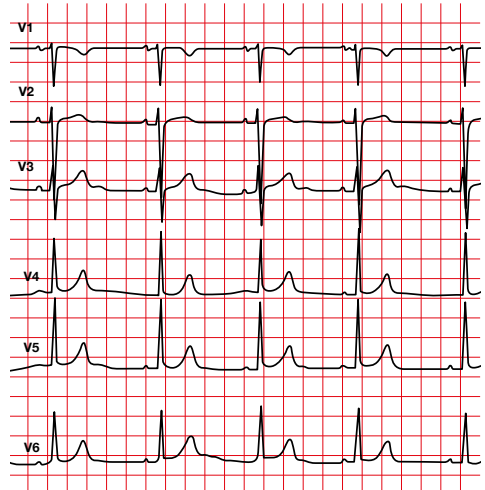
Normal



V2-V3 reversal



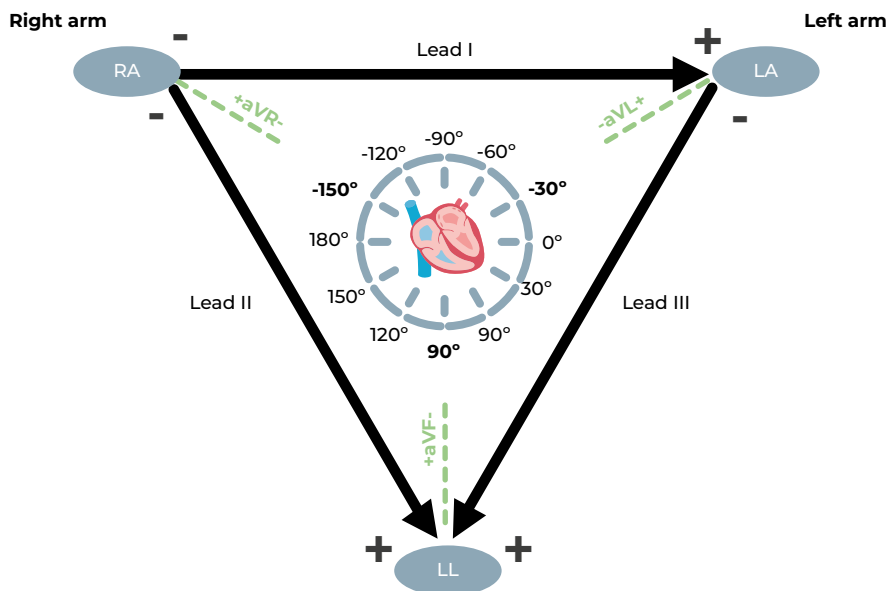
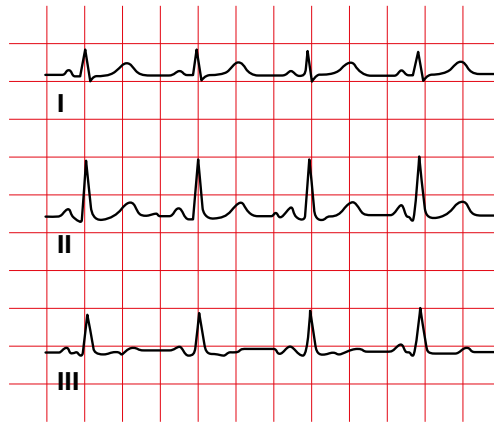
V4-V6 reversal



1.10. According to Einthoven's law:

$$I + III = II$$

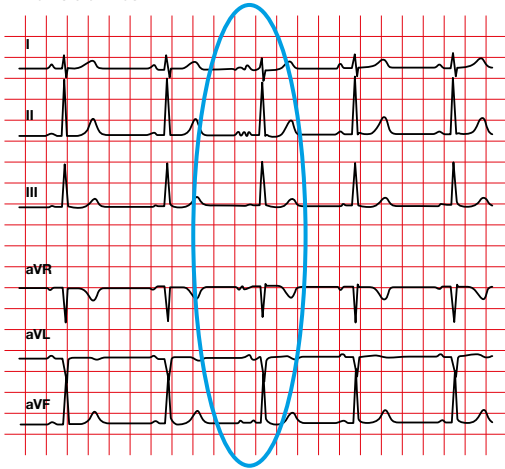
It is used to assess that there is no error in lead placement.



1.11. Electrocardiogram without filter

The baseline is not clean.

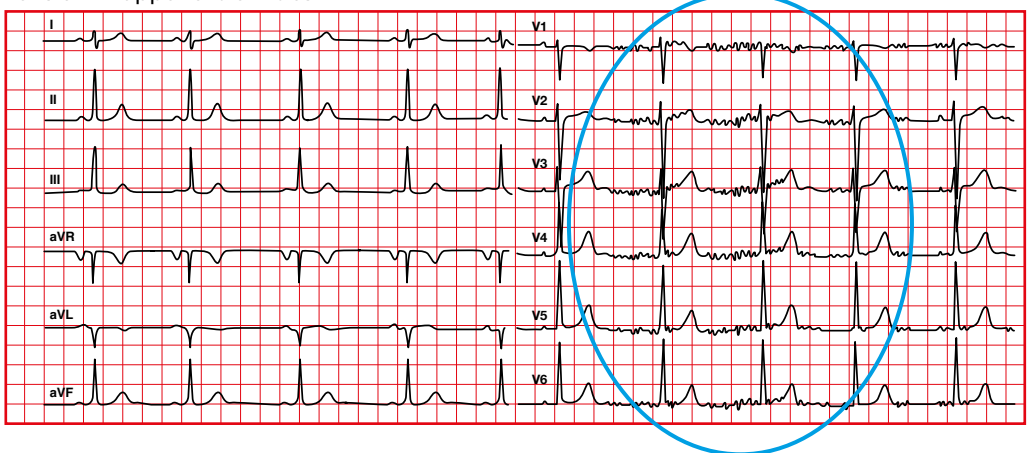
Without filter



1.12. Upper extremity tension

- The baseline does not look clean.
- To solve it, you can use the Mason-Likar system position.

Tension in upper extremities



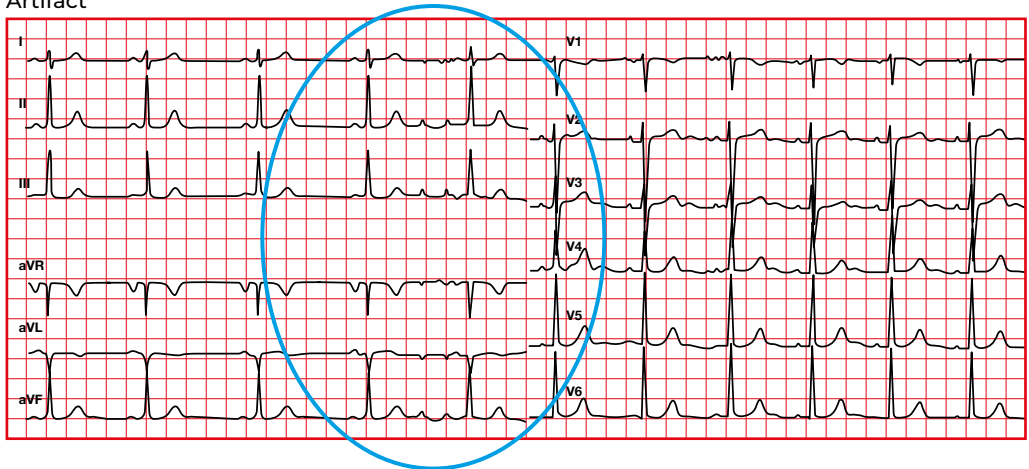
1.13. Artifact

The baseline is not clean.

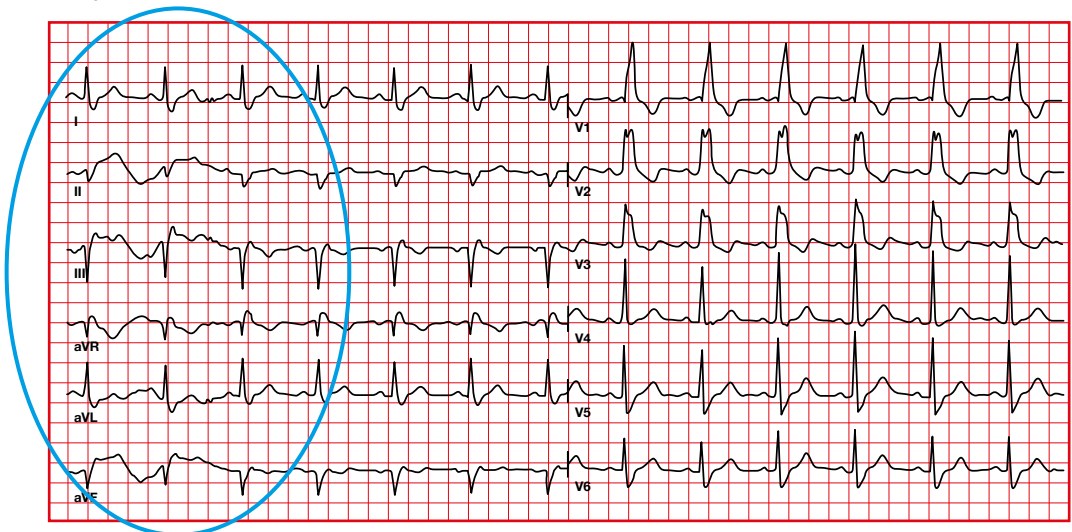
1.14. Body movement

There are variations in the baseline.

Artifact

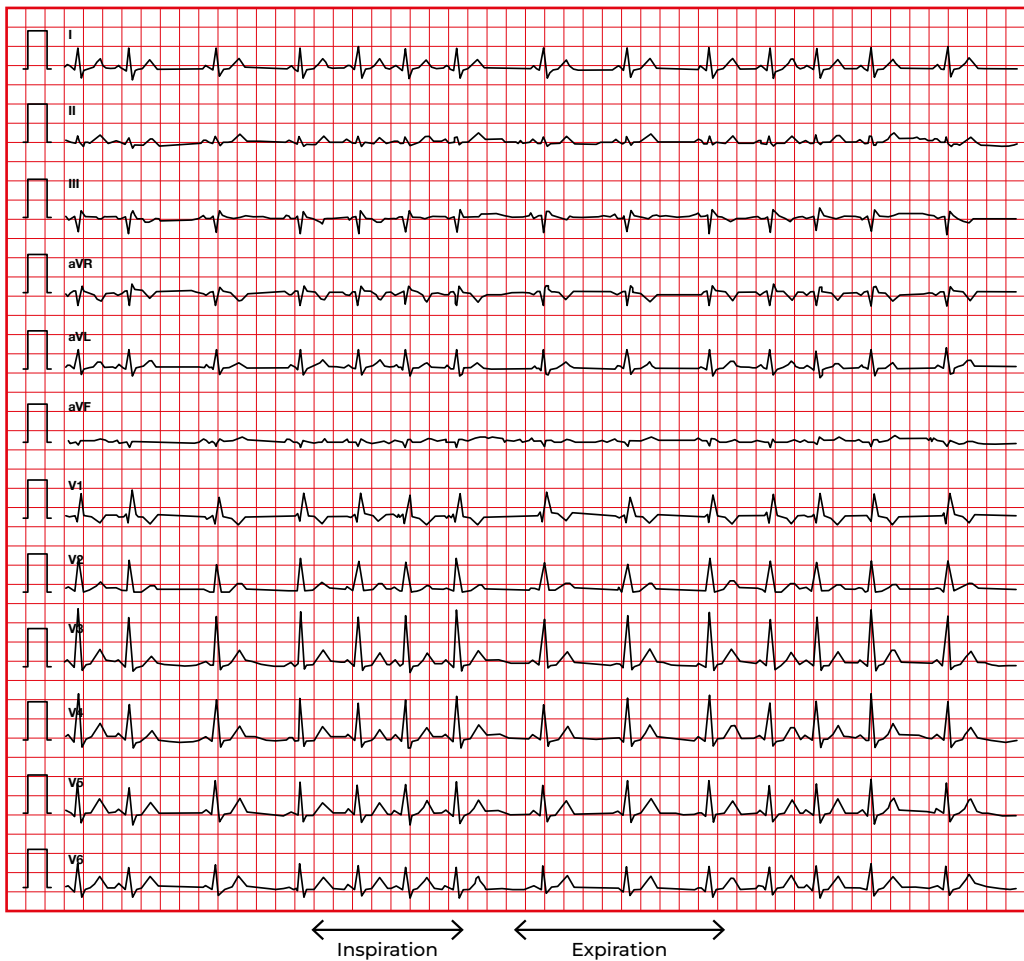


Body movement

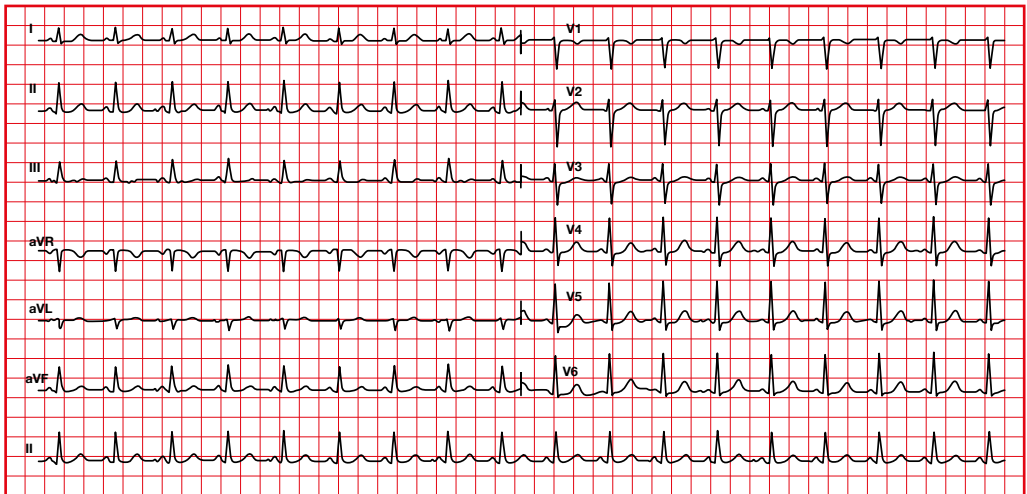


1.15. Physiological respiratory variation

There is a physiological acceleration of the heart rate during inspiration and a slowing during expiration.

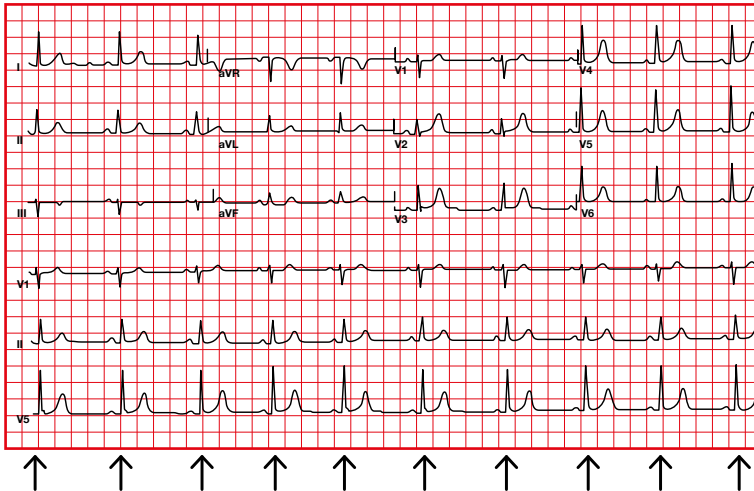


2. Rhythm



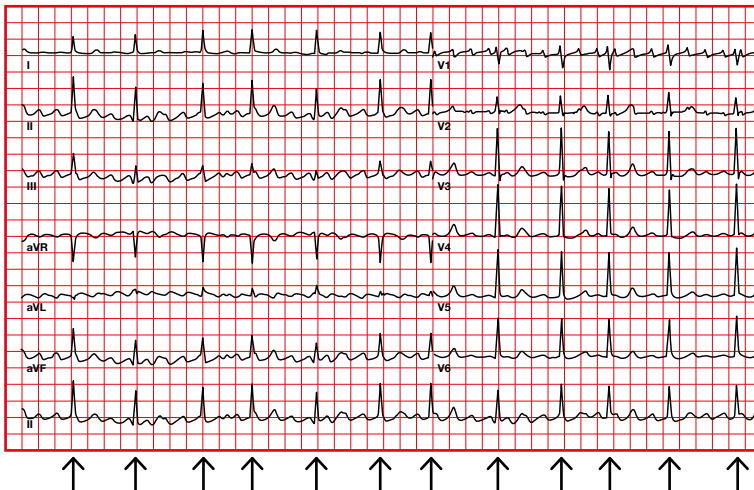
Systematic assessment of the electrocardiogram

The rhythm can be regular or irregular.



Regular: there is not much variability in the distance between the QRS complexes.

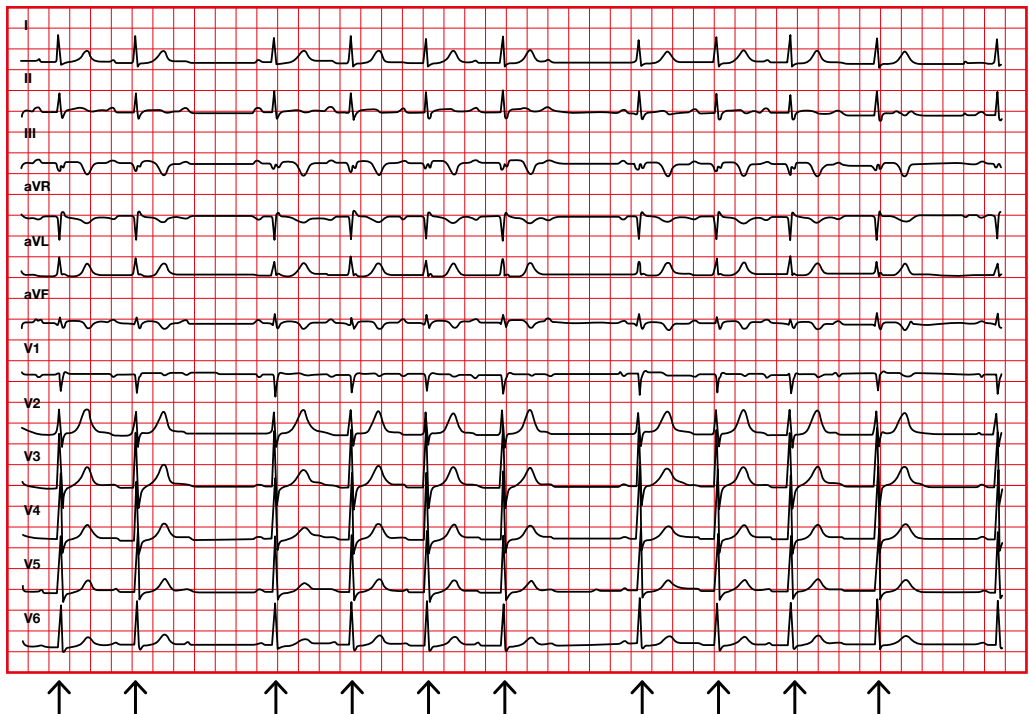
The difference between the longest and the shortest PP is less than 0.16 seconds (4 small squares).



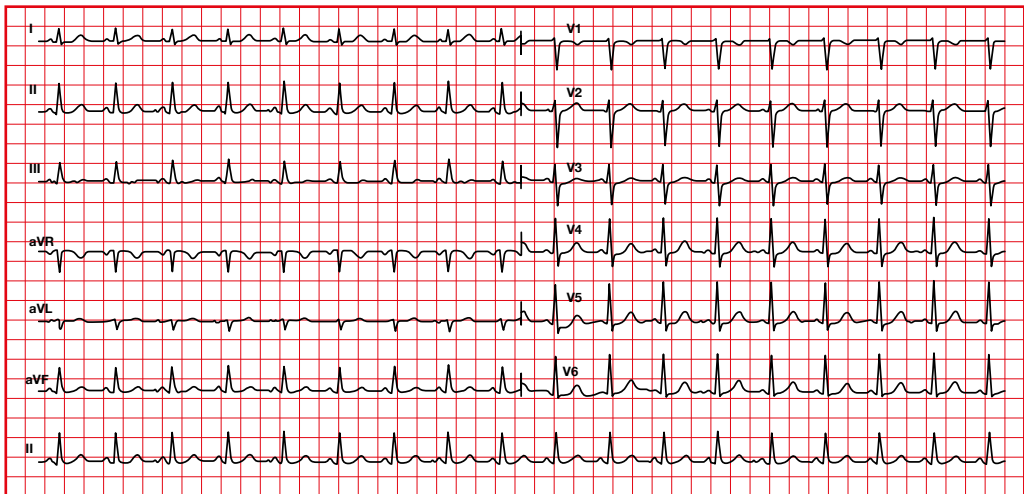
Irregular: there is variability in the duration between the QRS complexes.

2.1. Regularly irregular rhythm

Although it is an irregular rhythm, it follows a pattern.



3. Cardiac frequency

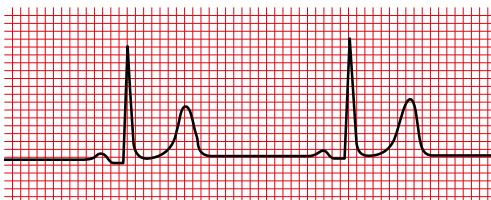
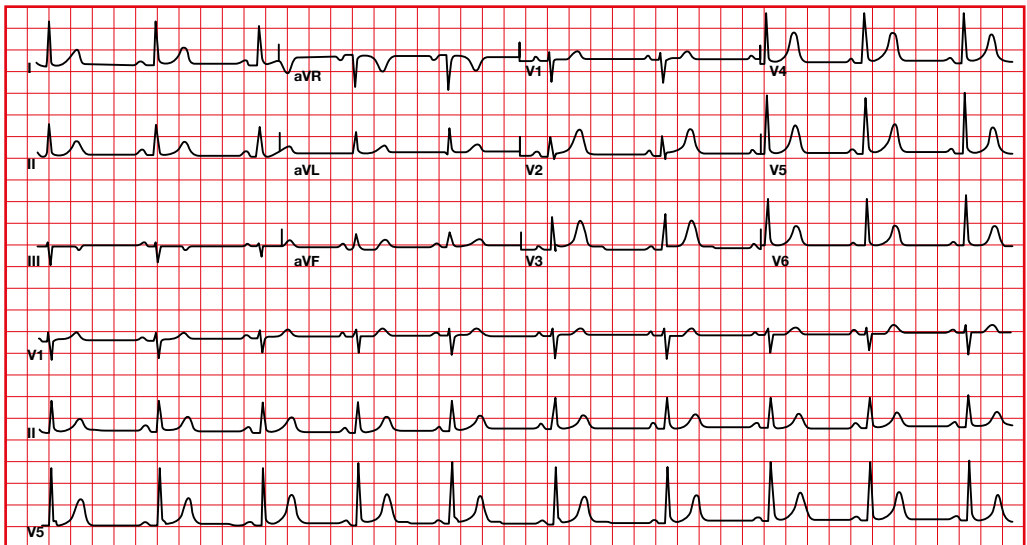


3.1. Frequency calculation

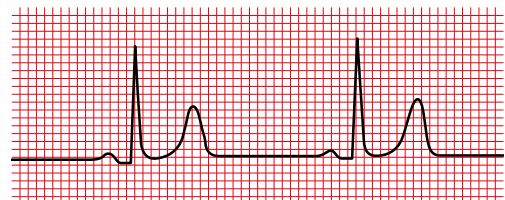
The large squares between two QRS complexes are numbered following the indicated sequence.

It can also be measured by dividing 1500 by the number of small squares between two QRS.

- **Normal heart rate.** 60-100 beats per minute.
- **Bradycardia.** Heart rate lower than 60 beats per minute.
- **Tachycardia.** Heart rate greater than 100 beats per minute.

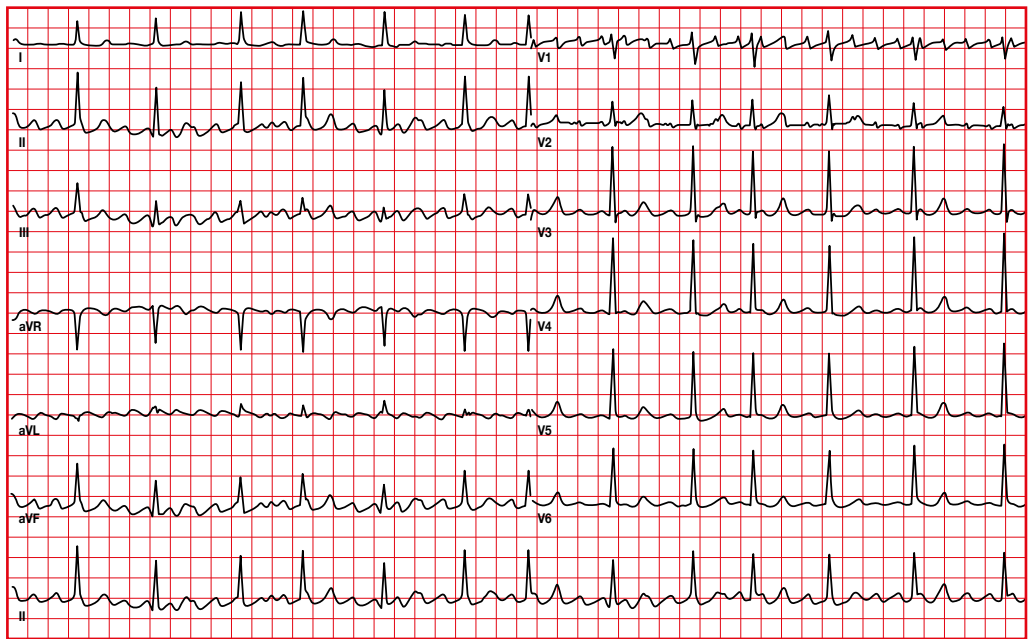


↑ ↑ ↑ ↑ ↑ ↑ ↑
300 150 100 75 60 50



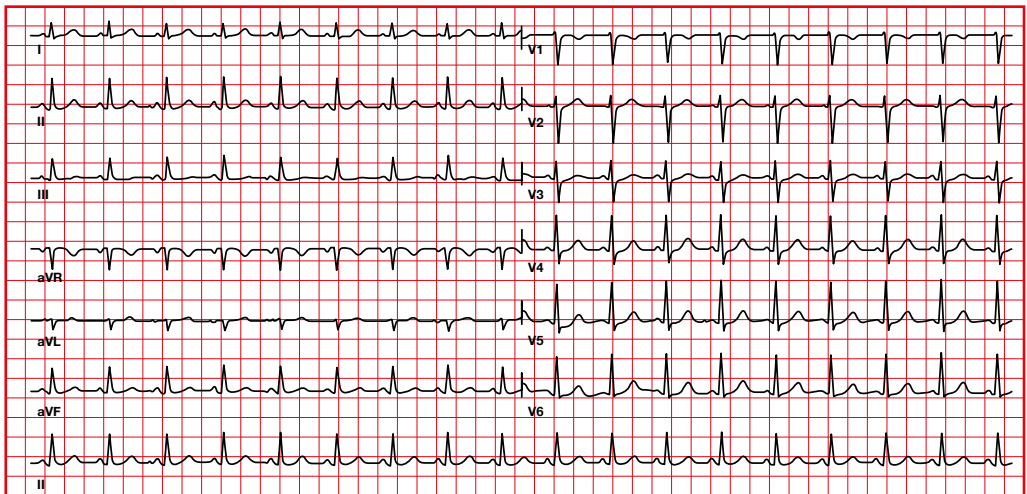
↑ 27 small squares ↑
 $1.500 / 27 = 55$

When the rhythm is not regular (the duration between QRS changes), you can calculate the number of QRS complexes present in 10 seconds (the normal duration of an electrocardiogram) and multiply the result by 6.



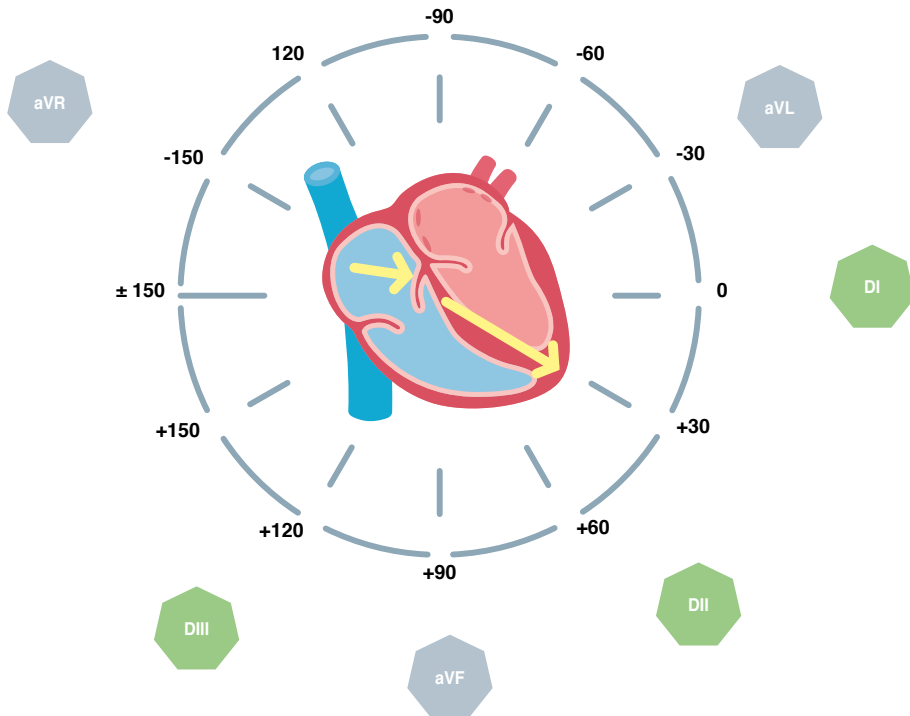
10 seconds
13 QRS complexes × 6 = 78

4. Axis



4.1. Axis calculation

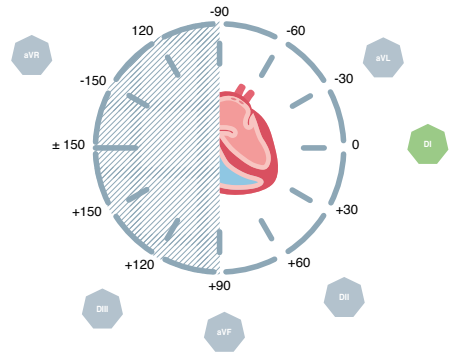
To calculate the axis we must define the positive and negative hemifields of each lead according to an axis passing through the center of the heart.



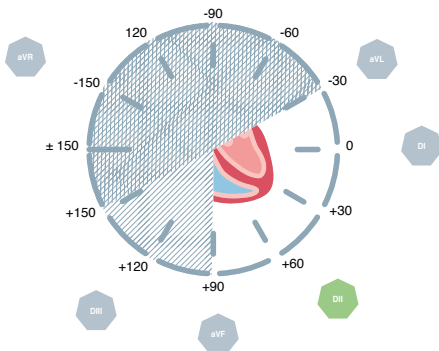
4.2. QRS axis calculation

The normal ventricular depolarization vector runs inferiorly and from right to left.

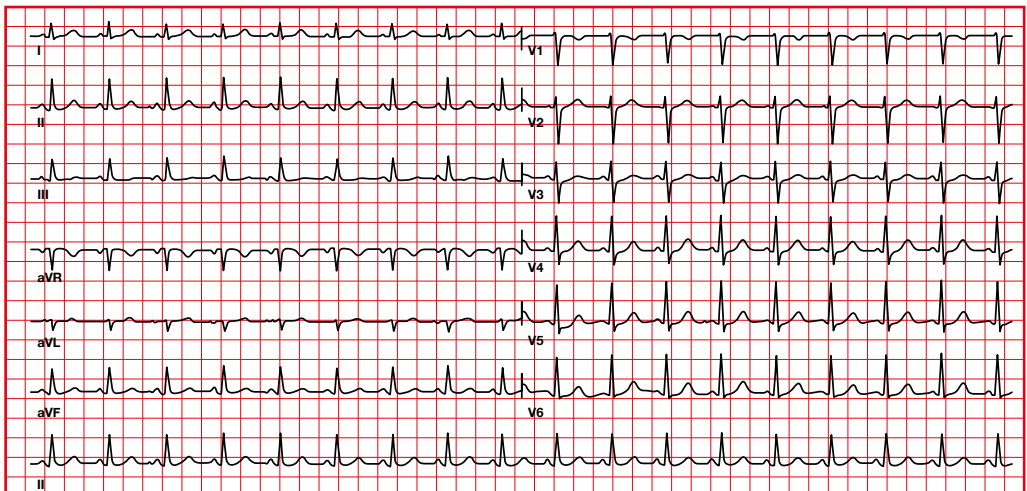
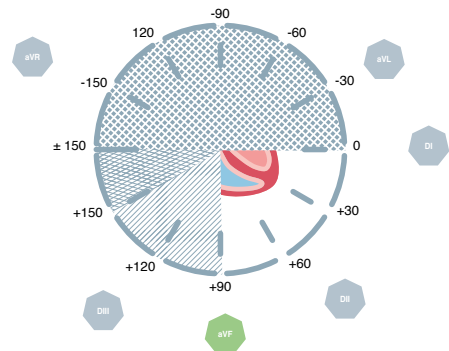
Positive in I



Positive in II

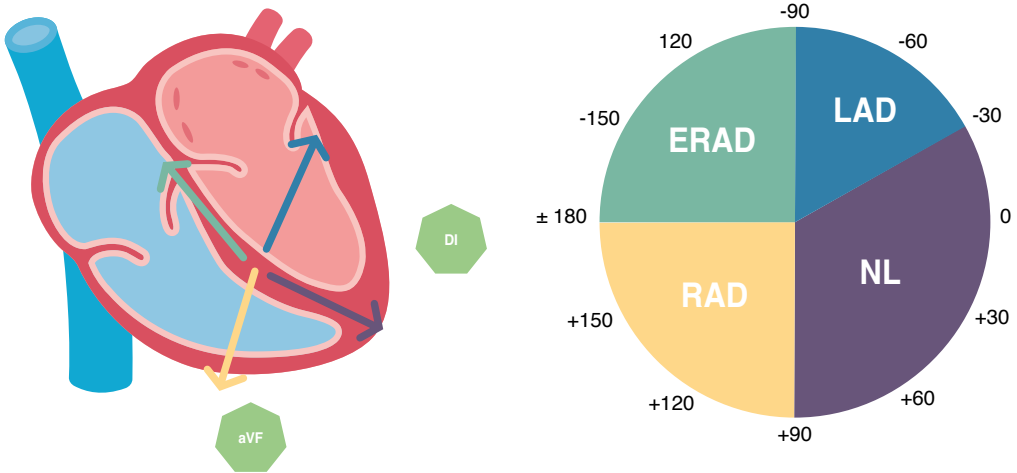


Positive in aVF



4.3. QRS complex axis

The cardiac axis determines the direction of the depolarization vector or activation of the ventricular cells.



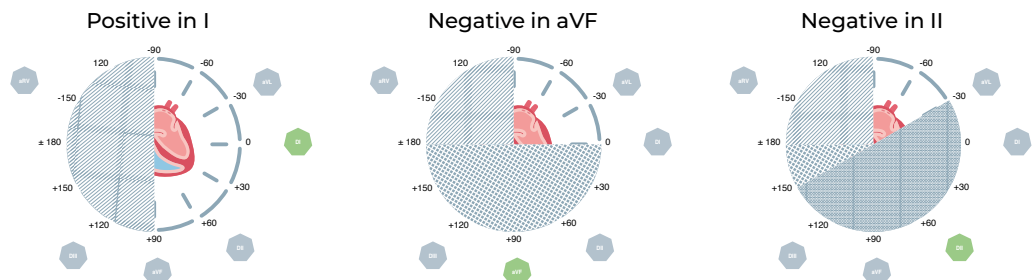
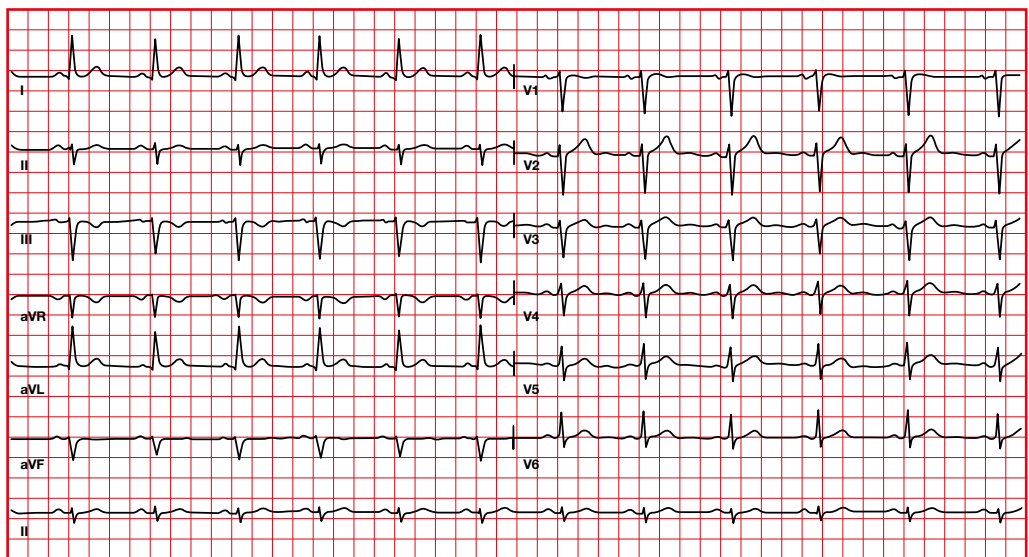
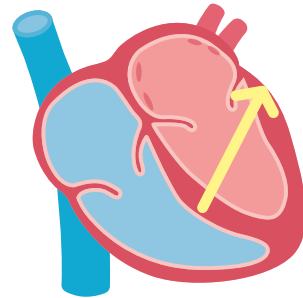
Axis	Lead I	Lead aVF
Normal axis (NL)	Positive	Positive
Left axis deviation (LAD)	Positive	Negative
Right axis deviation (RAD)	Negative	Positive
Extreme right axis deviation (ERAD)	Negative	Negative

4.4. Left axis deviation

QRS axis -30 to -90.

Causes

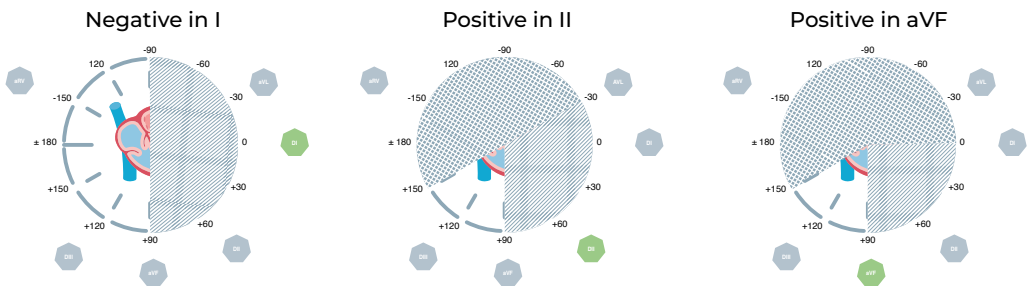
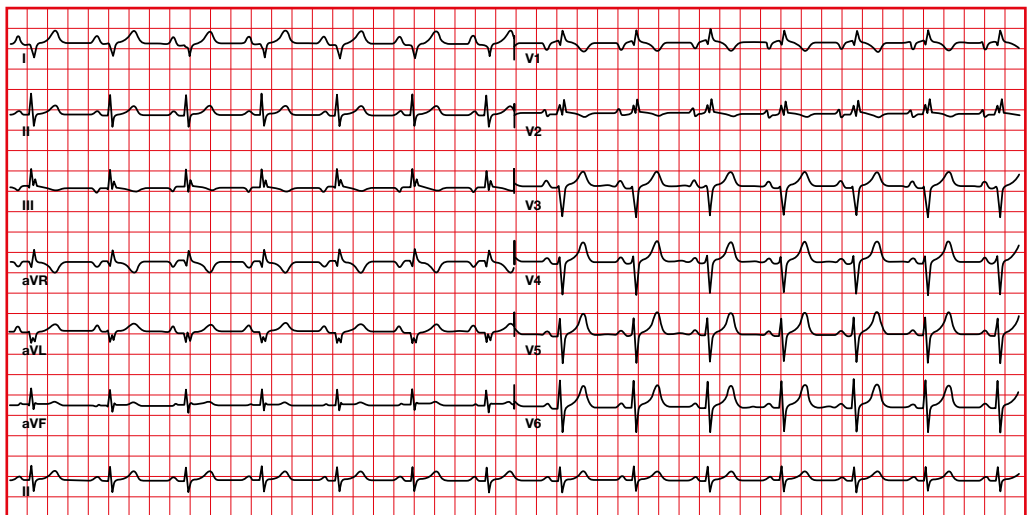
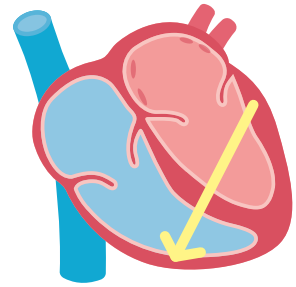
- Left anterior hemiblock.
- Inferior infarction.
- Left bundle branch block.
- Left ventricular hypertrophy.
- Atrial septal defect (*ostium primum*).
- Pacemaker rhythm.
- Hyperkalemia.
- Pre-excitation syndromes.
- Ventricular rhythms.



4.5. Right axis deviation

From +90 to +180.

- Causes**
- Right ventricular hypertrophy.
 - Vertical heart.
 - Right bundle branch block.
 - Pulmonary embolism
 - Left posterior fascicular block.
 - Lateral infarction.
 - Dextroposition.
 - ECG lead misplacement
 - Atrial septal defect (*ostium secundum*).
 - Chronic obstructive pulmonary disease.
 - Pre-excitation syndromes.
 - Ventricular rhythms.

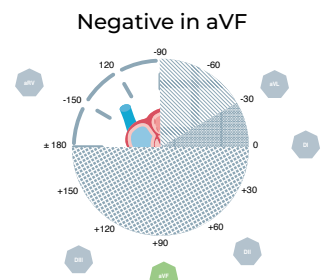
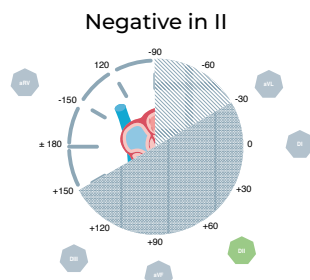
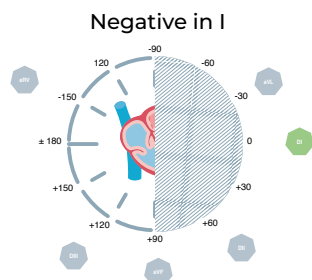
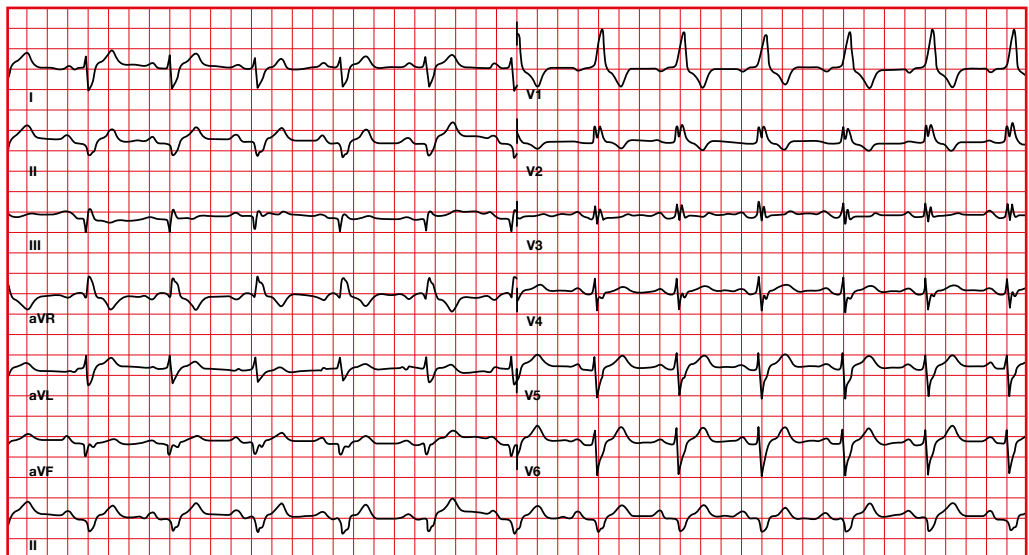
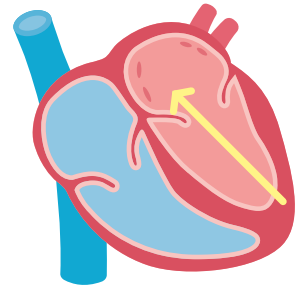


4.6. Extreme right axis deviation

From -90 to -180 .

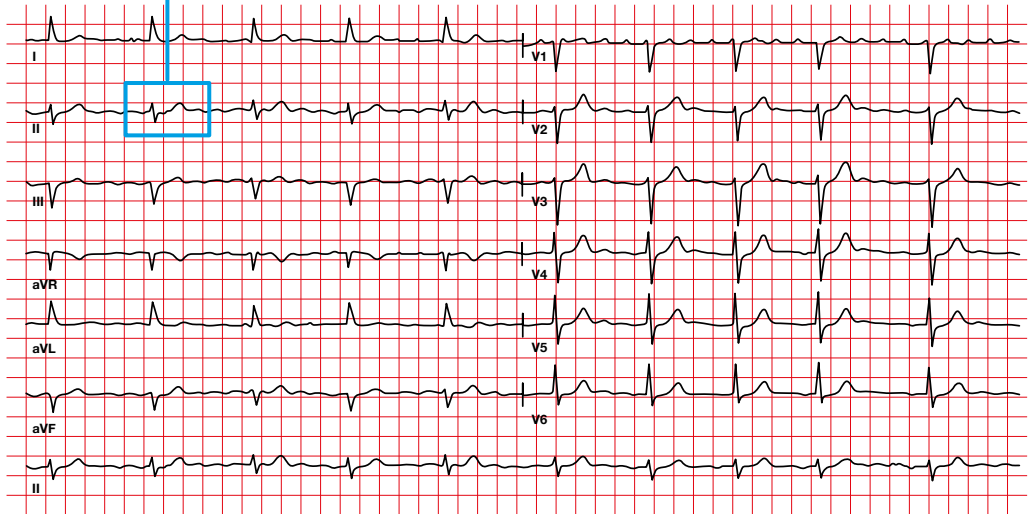
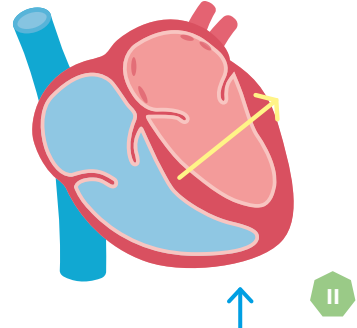
Causes

- ECG lead reversal (right arm for left leg).
- Hyperkalemia.
- Emphysema.
- Ventricular rhythm: ventricular tachycardia, accelerated idioventricular rhythm, ventricular escape rhythm.
- Ventricular pacemaker.

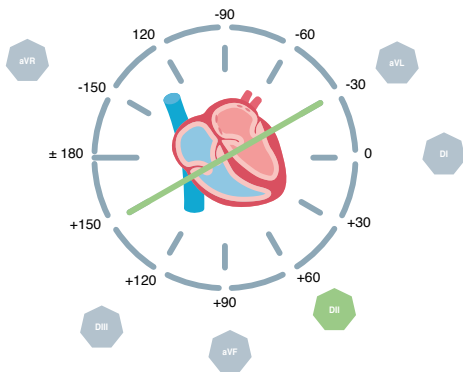


4.7. Calculation of the QRS axis when there is an isodiphasic QRS complex

In this situation, the axis will be perpendicular to the lead.

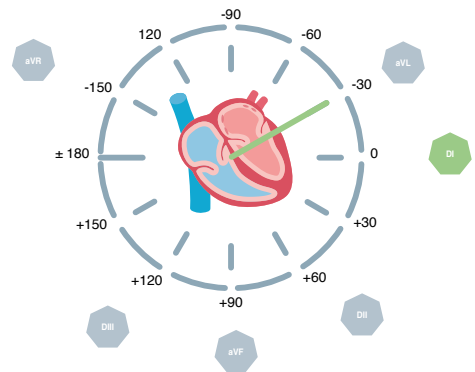


Isodiphasic in II



Being isodiphasic in II; the axis will be either +150 or -30

Positive in I

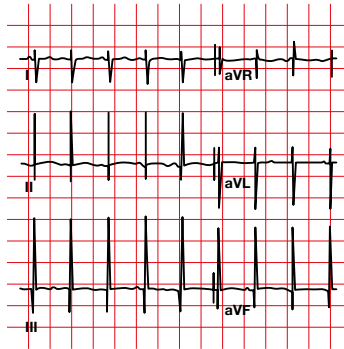
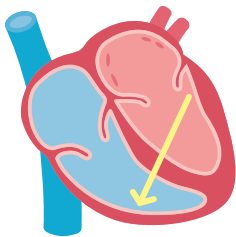


Because it is positive in I, the axis will be -30

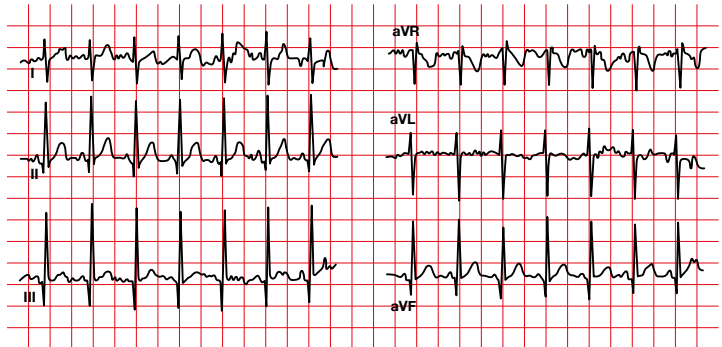
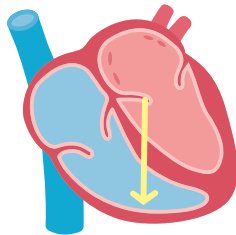
4.8. Progression of the QRS complex axis with age

With ageing the QRS axis shifts to the left.

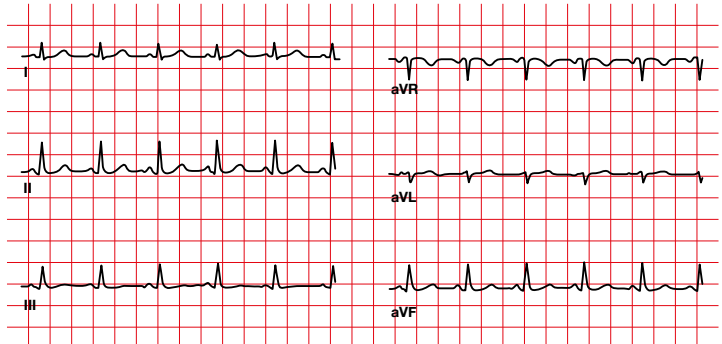
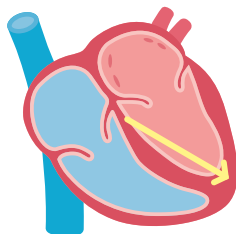
Newborn



Child

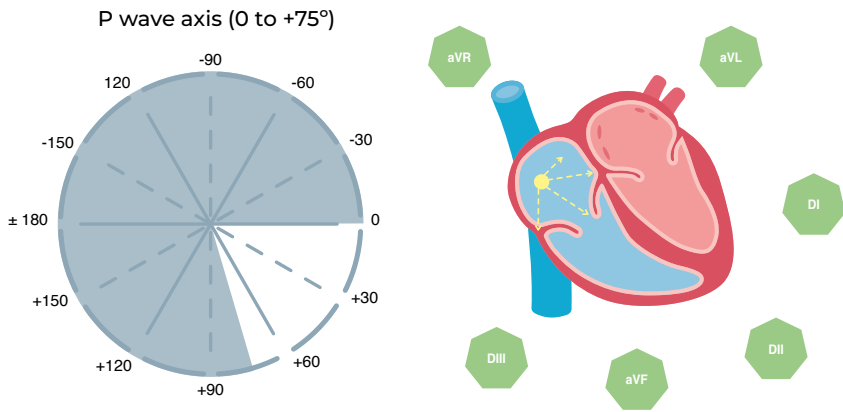


Adult

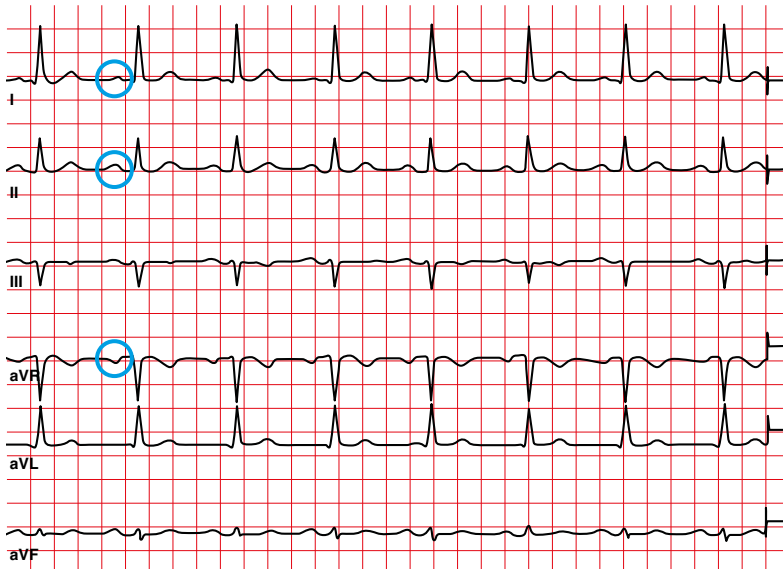


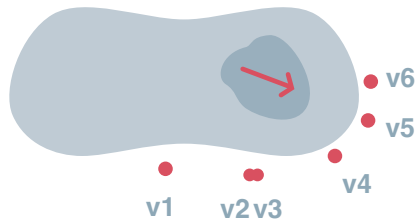
4.9. Calculation of the P wave axis

The atrial depolarization vector is directed downward and from right to left.

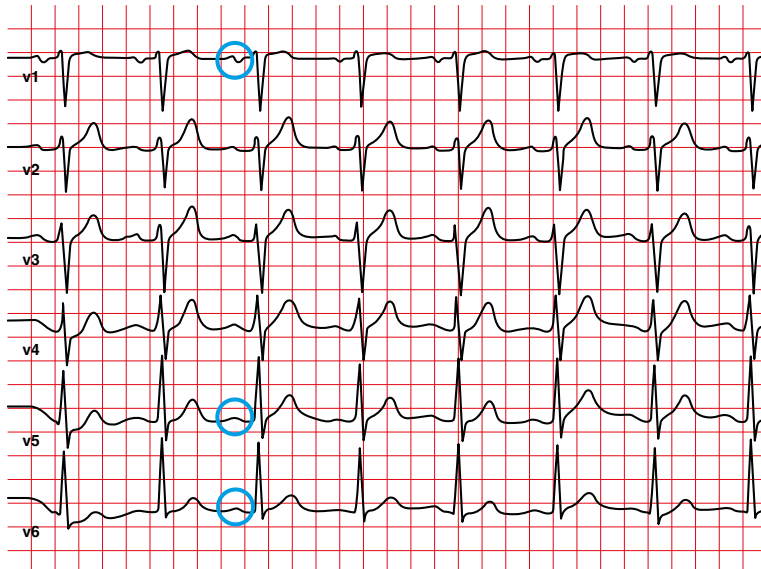


Positive P in I, II — Negative P in aVR

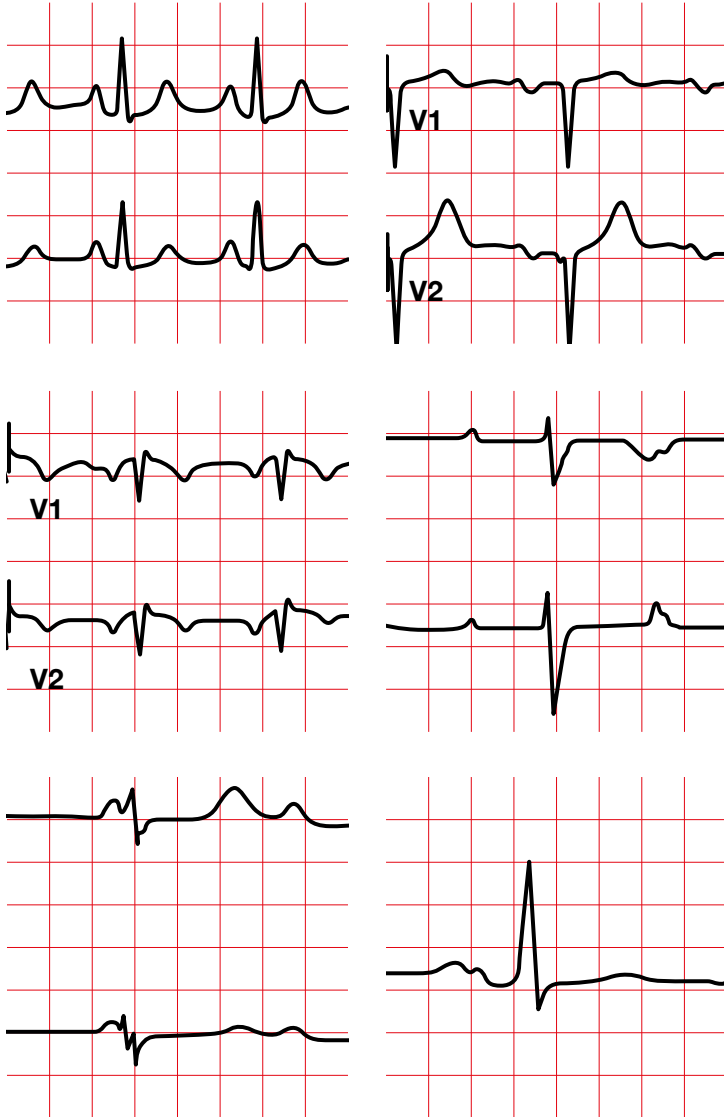




Positive P in V5, V6 — V1 usually biphasic

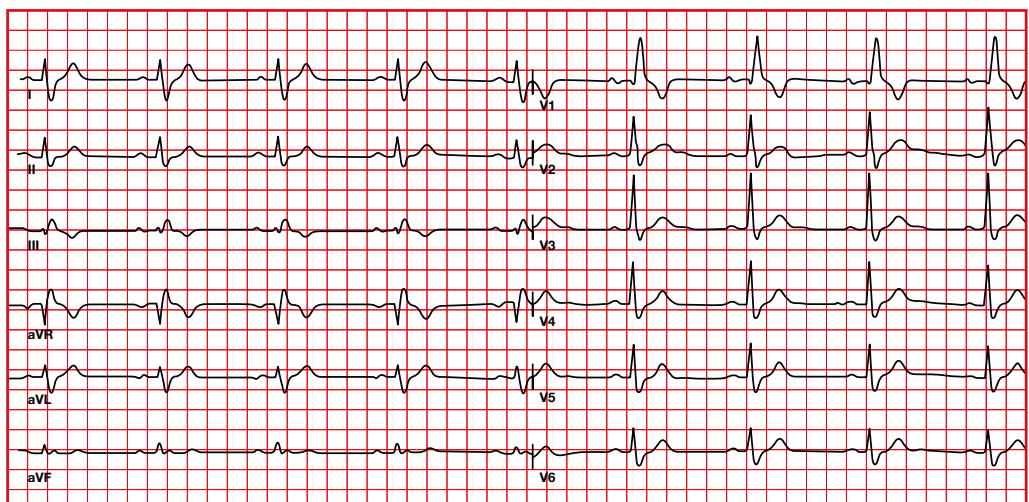
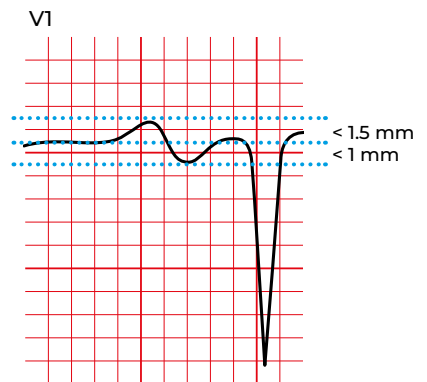
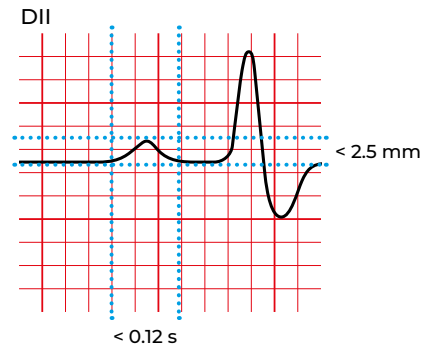


5. P wave



5.1. Sinus P wave

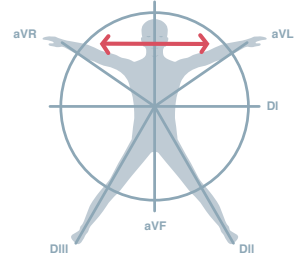
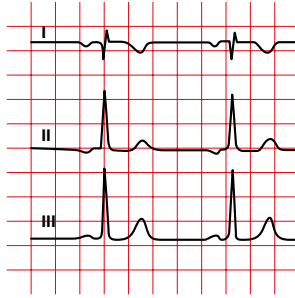
- P wave axis: 0-75°.
- Morphology:
 - Positive in I and II.
 - Negative in aVR.
 - Inverted or biphasic in V1 and V2 (there may be a small indentation).
- Amplitude:
 - Bipolar leads: less than 0.25 mV (2.5 mm with normal calibration) in all leads.
 - Lead V1: positive deflection less than 1.5 mm and negative less than 1 mm.
- Duration:
 - 0.08 to 0.11 seconds.



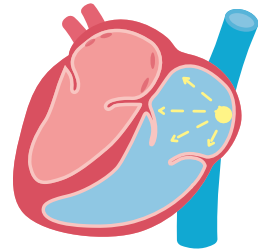
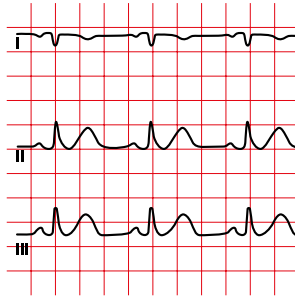
5.2. P wave abnormalities

There are typically 4 scenarios in which the P wave axis will not be normal.

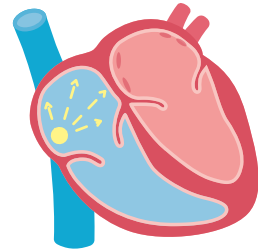
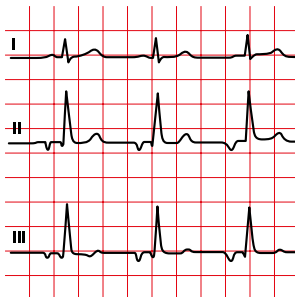
Lead reversal



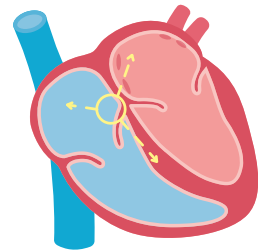
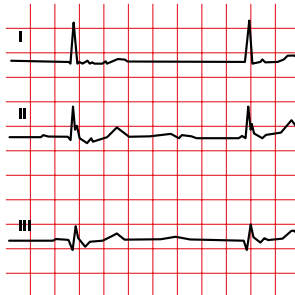
Dextrocardia



Atrial rhythm



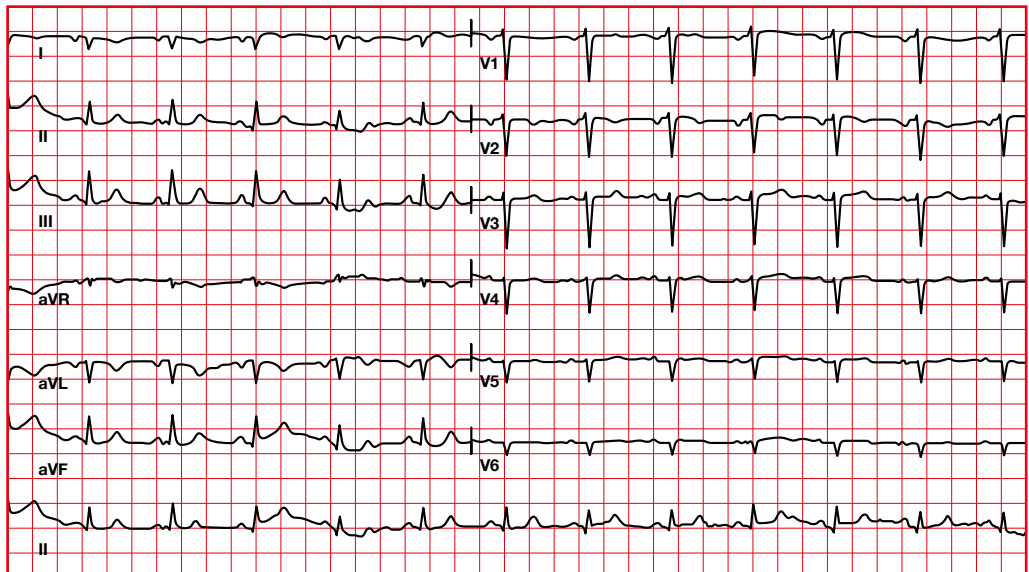
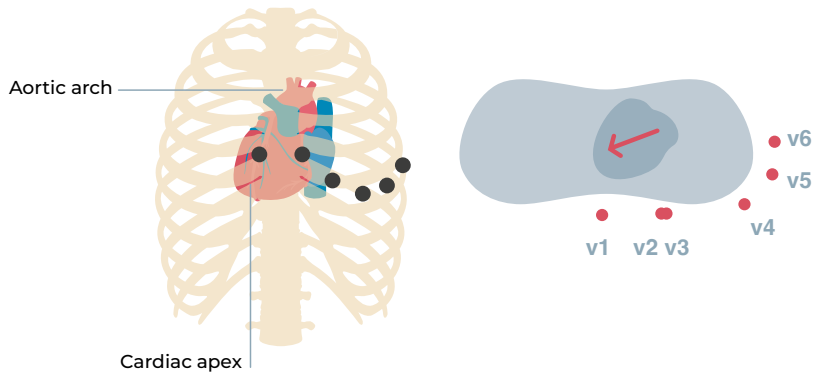
Junctional rhythm



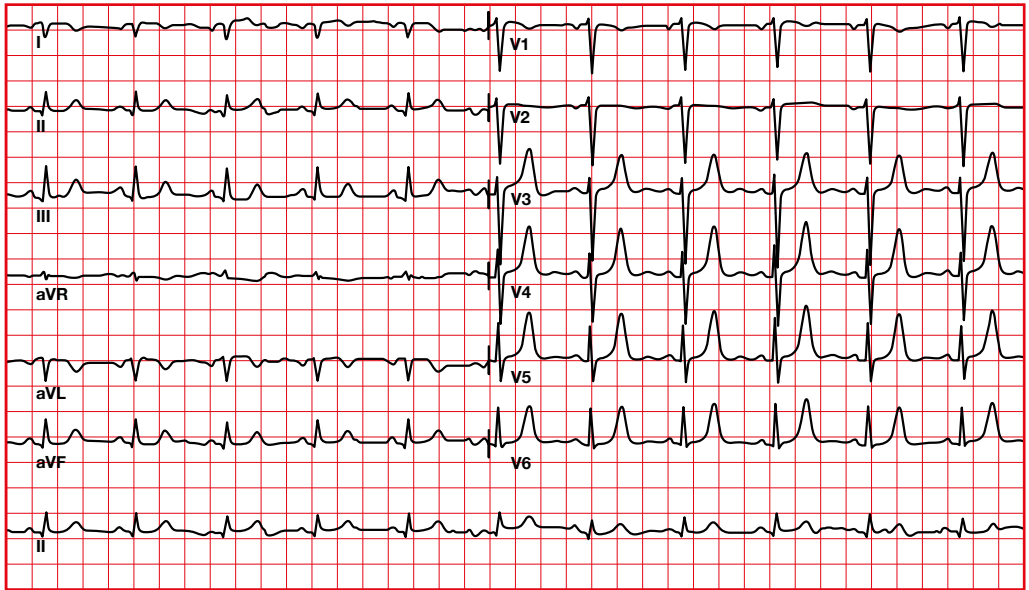
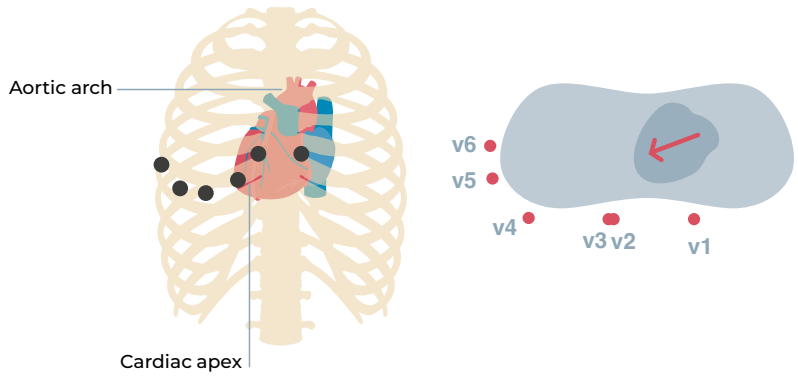
5.3. P wave in dextrocardia

We will see an inversion of the P wave in I and in aVL (also of the QRS complex and of the T wave).

Dextrocardia



Dextrocardia with corrected precordial leads



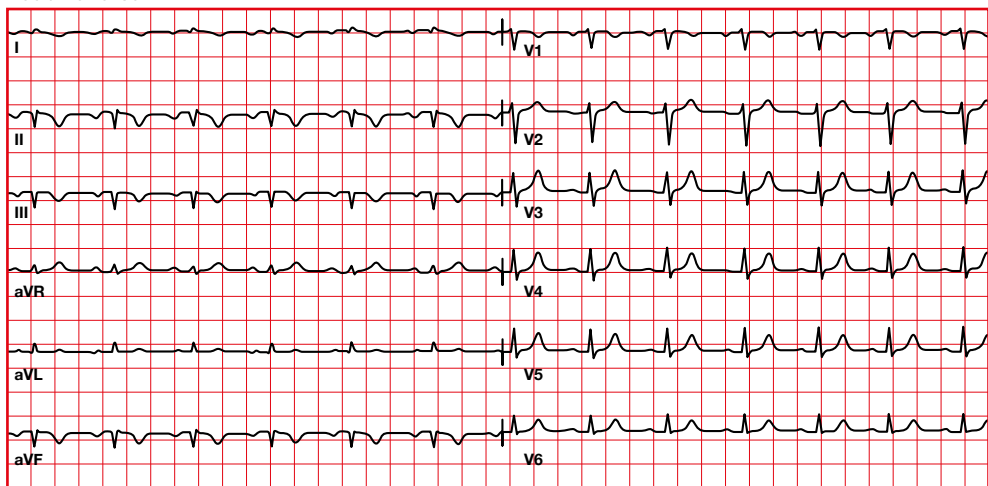
5.4. P wave axis abnormalities

To distinguish dextrocardia from lead reversal, it is necessary to look at the precordial leads:

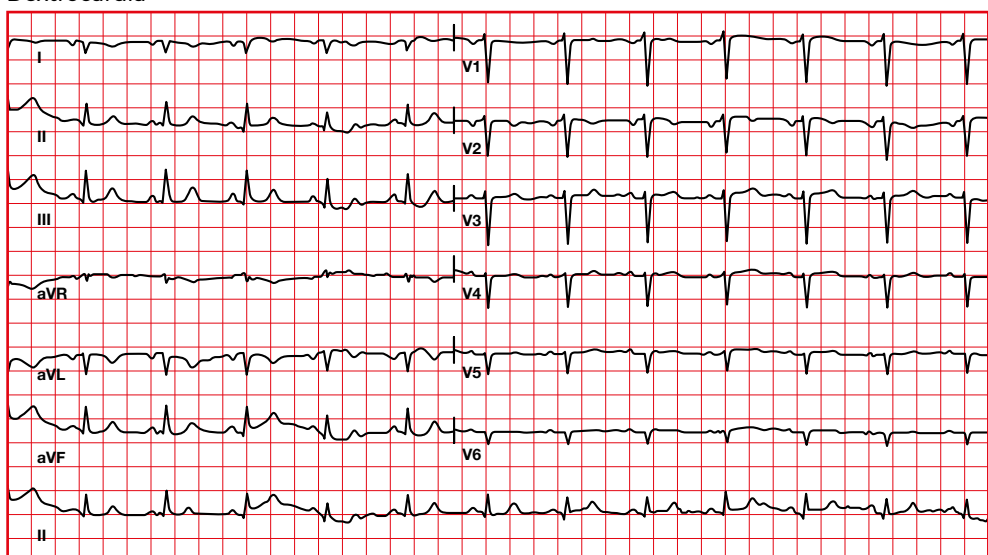
- In dextrocardia the R wave becomes smaller as it progresses in the precordial leads.

- In lead reversal, the R wave progresses normally in the precordial leads.

Lead reversal

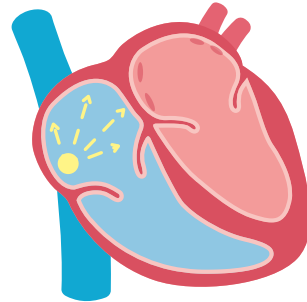


Dextrocardia

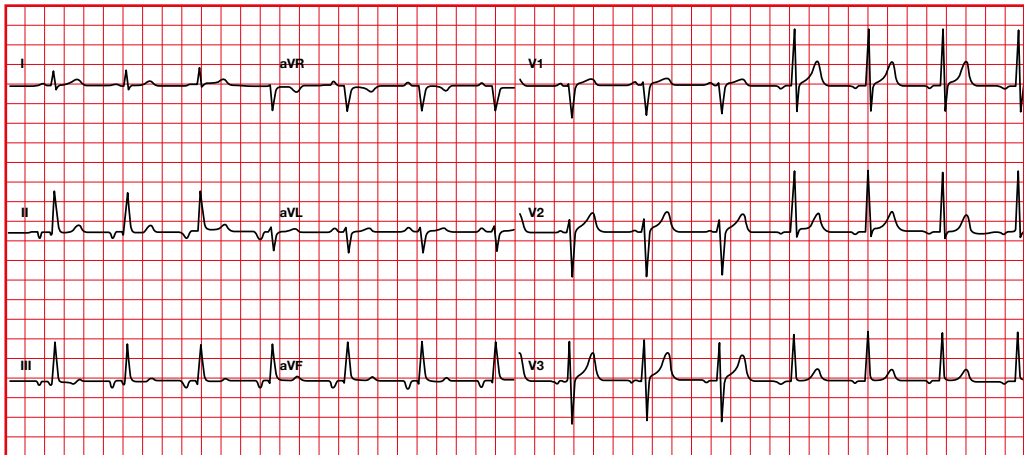


5.5. P wave axis abnormalities. Ectopic atrial rhythm

- P wave axis and morphology is different from a sinus P wave.
- HR less than 100 beats per minute.
If the HR > 100, then it is an ectopic atrial tachycardia.

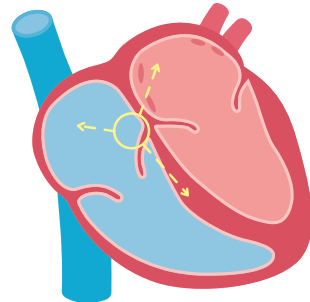


Atrial rhythm (negative P wave in lead II, positive in lead aVR)

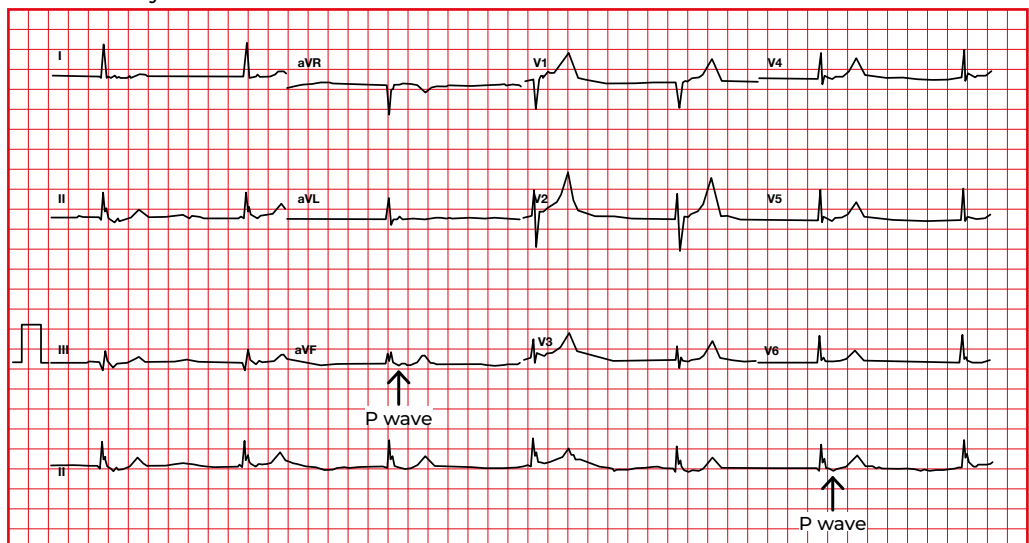


5.6. P wave axis abnormalities. Junctional rhythm

- P wave morphology: there is a retrograde P wave. Therefore it will be negative in II, III, aVF and positive in aVR.
- The P can precede the QRS, be within the QRS, or be behind the QRS.



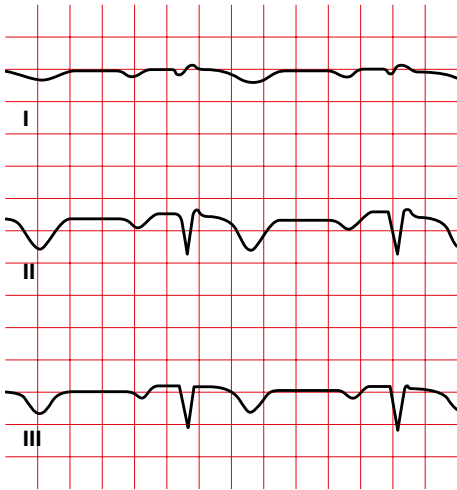
Junctional rhythm



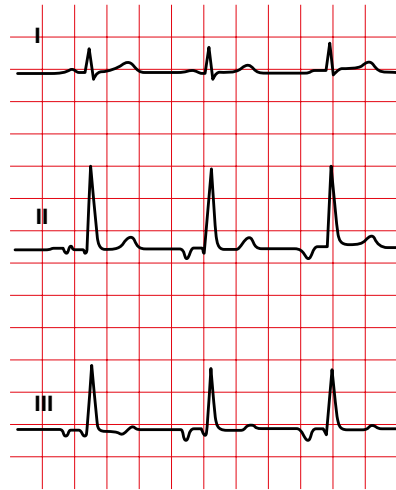5.7. Einthoven's law

$$I + III = II.$$

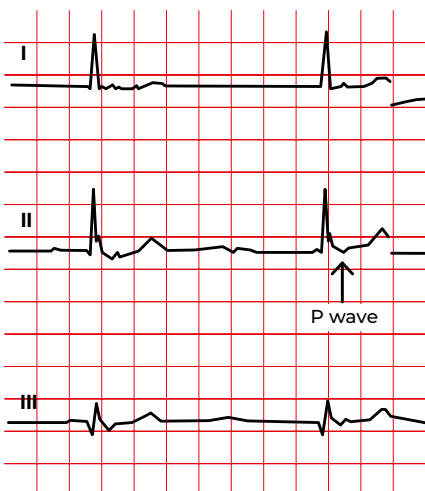
Lead reversal,
it does not meet Einthoven's law



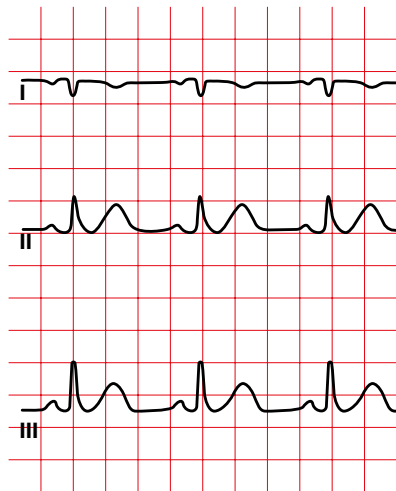
Atrial rhythm,
it does meet Einthoven's law



Junctional rhythm,
it does meet Einthoven's law

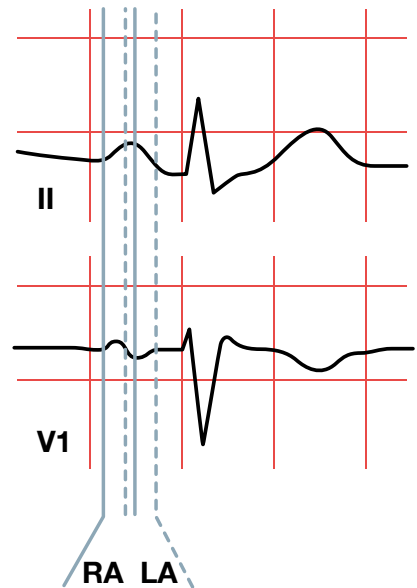


Dextrocardia,
it does meet Einthoven's law



5.8. Abnormal P-wave morphology

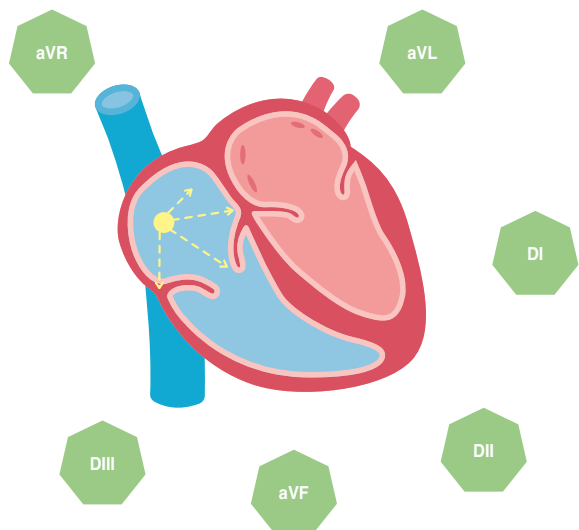
- The P wave is best seen in leads II and V1.
- The first part of the P wave represents the activation of the right atrium and the second part, the activation of the left atrium.



The sinus node is located in the right atrium. This is activated first, with activation progressing in an inferior and anterior direction.

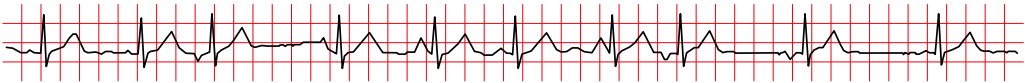
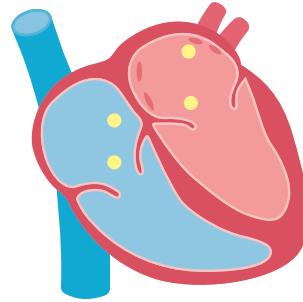
Therefore, there will be a positive deflection in II and V1.

This is followed by activation of the left atrium progressing in an inferior and posterior direction, causing a positive deflection in II and a negative deflection in V1.



5.9. Abnormal P-Wave morphology. Multifocal atrial rhythm (wandering pacemaker)

- P with three or more morphologies in a same lead.
- Heart rate less than 100 beats per minute. If HR > 100 then it is named multifocal atrial tachycardia.
- Irregular rhythm. Varying PR, RR and RP intervals.



It is very common in patients with COPD (chronic obstructive pulmonary disease).

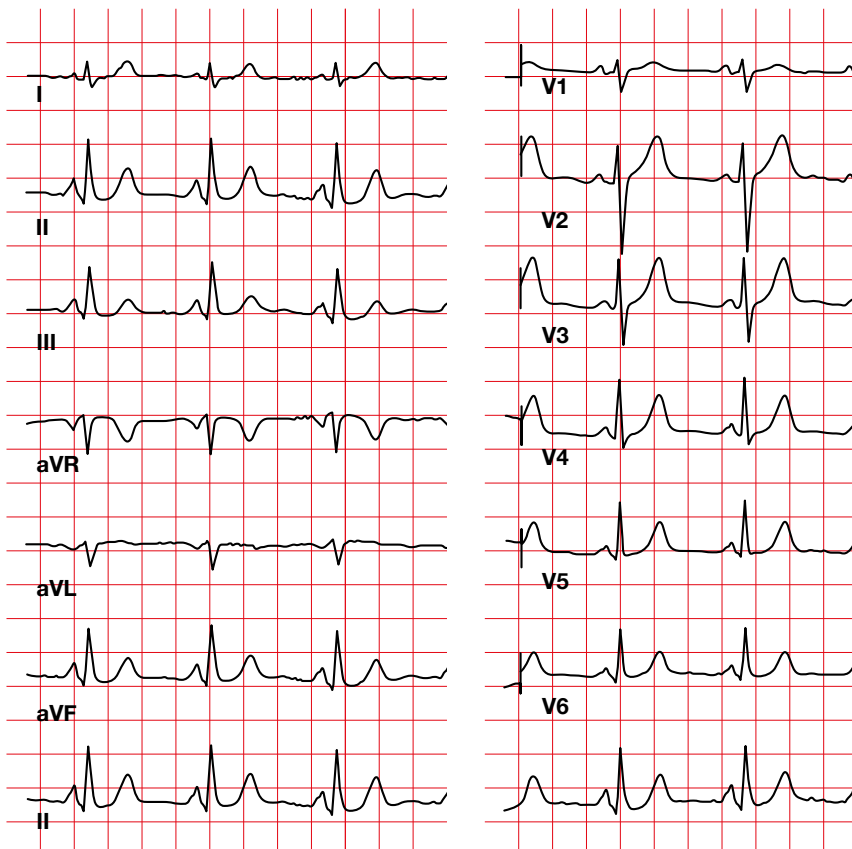
It can be misinterpreted as sinus rhythm with premature multifocal complexes (but, in this case, there

would be an atrial pacemaker with a dominant P wave).

It can be misinterpreted as flutter/FA. You have to find the isoelectric line, present in multifocal atrial rhythm.

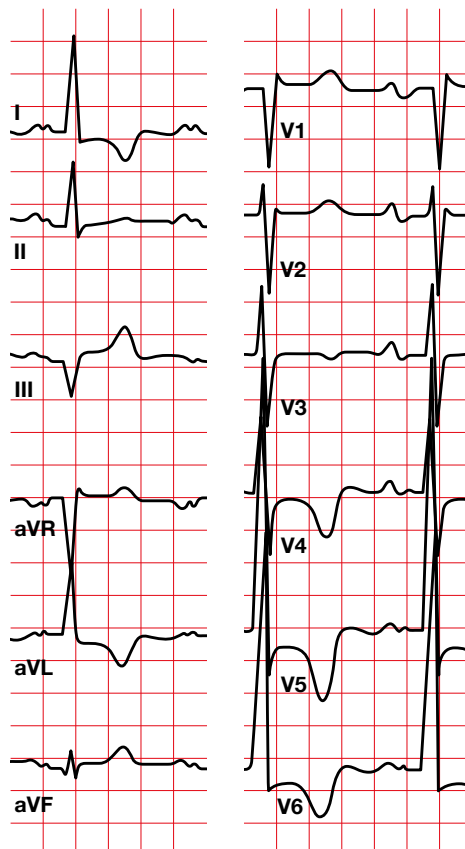
5.10. Abnormal P-Wave morphology. Right atrial enlargement (P pulmonale)

- The duration of P is not lengthened (< 0.12 seconds).
- Positive P > 2.5 mm in II, III, aVF.
- Positive P > 1.5 mm in V1, V2.



5.11. Abnormal P-Wave morphology. Left atrial enlargement (*P mitrale*)

- P with notch in I, II, aVL, with duration ≥ 0.12 seconds.
- In V1 there will be a terminal P ≥ 1 mm, negative and ≥ 0.04 seconds (Morris index).



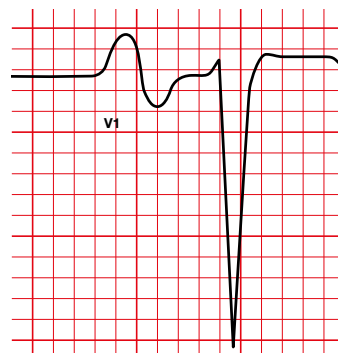
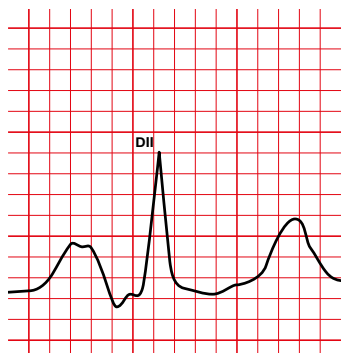
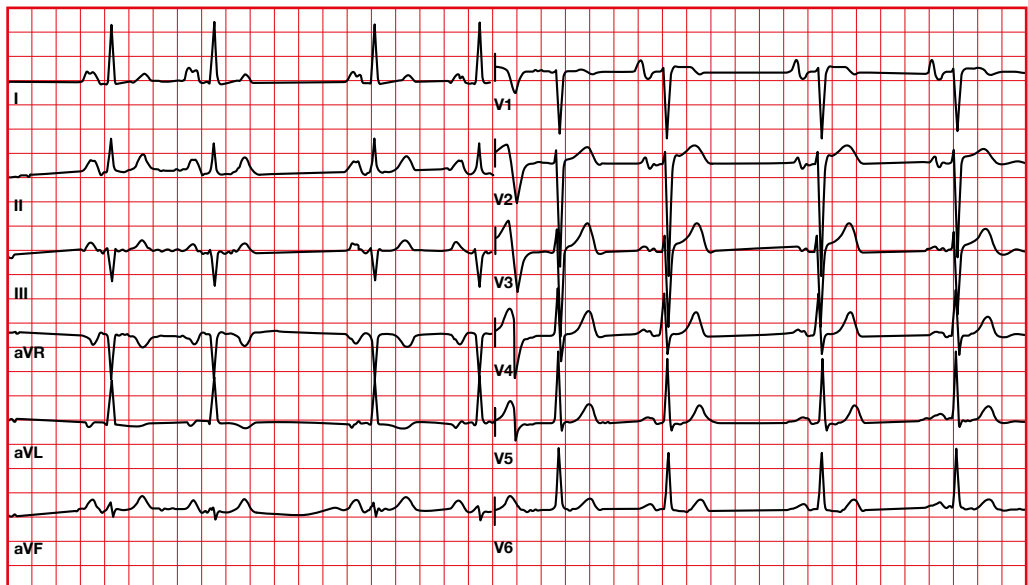
5.12. Abnormal P-Wave morphology. Biatrial enlargement

Lead VI:

- Biphasic P wave.
- Initial positive amplitude > 1.5 mm.
- Terminal negative amplitude ≥ 1 mm with a duration of 0.04 seconds.

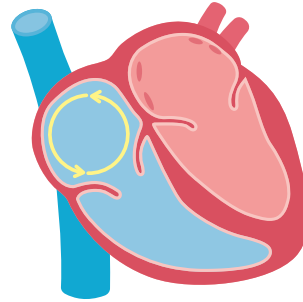
Lead II:

- P wave with a duration of ≥ 0.12 seconds.

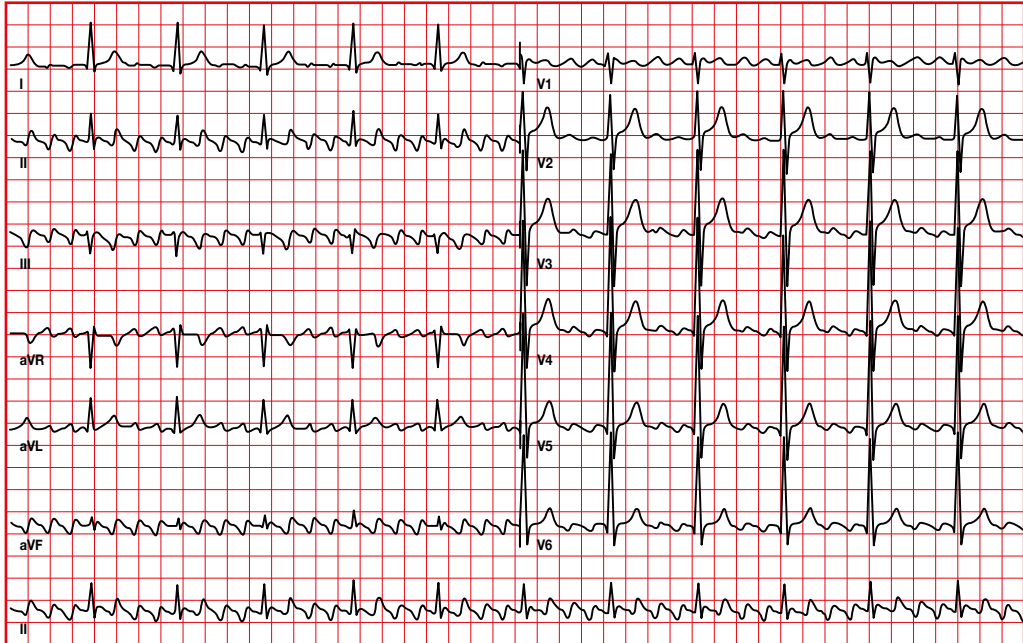


5.13. Absence of P wave. Flutter

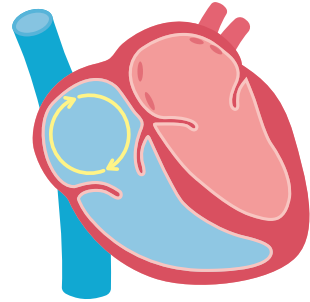
- Flutter: fast auricular waves are detected (250-300 per minute), F waves (flutter waves).
- In the typical flutter, the circuit uses the cavotricuspid isthmus.
- Suspect flutter when the cardiac frequency is 150 per minute (2:1 block).



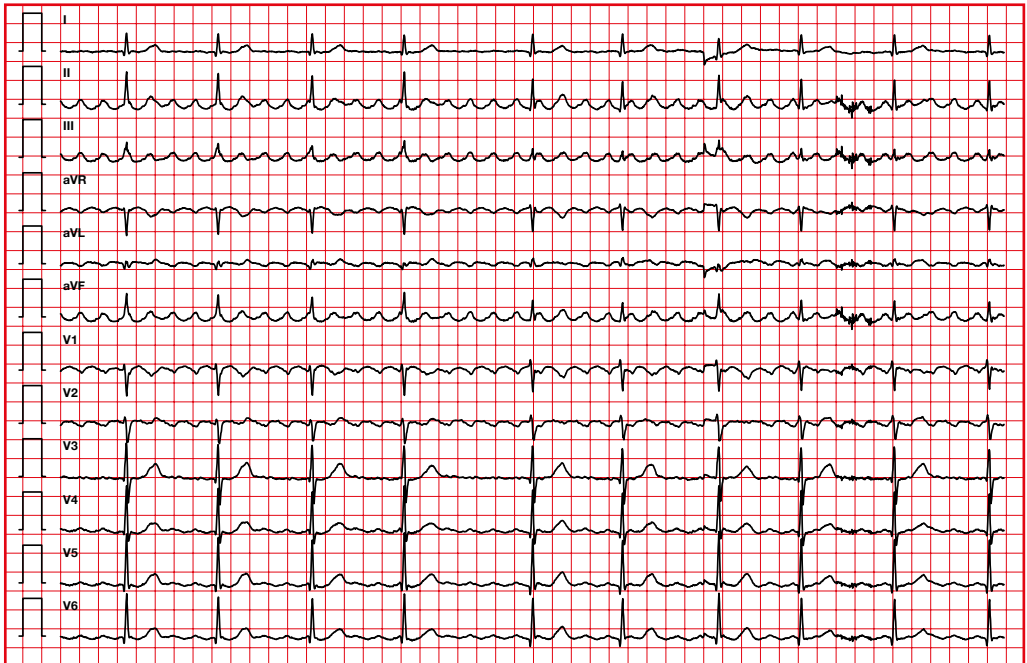
Typical flutter



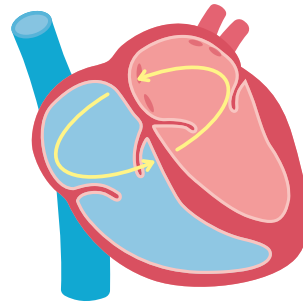
Negative F waves in II, III and aVF. Counterclockwise circuit.



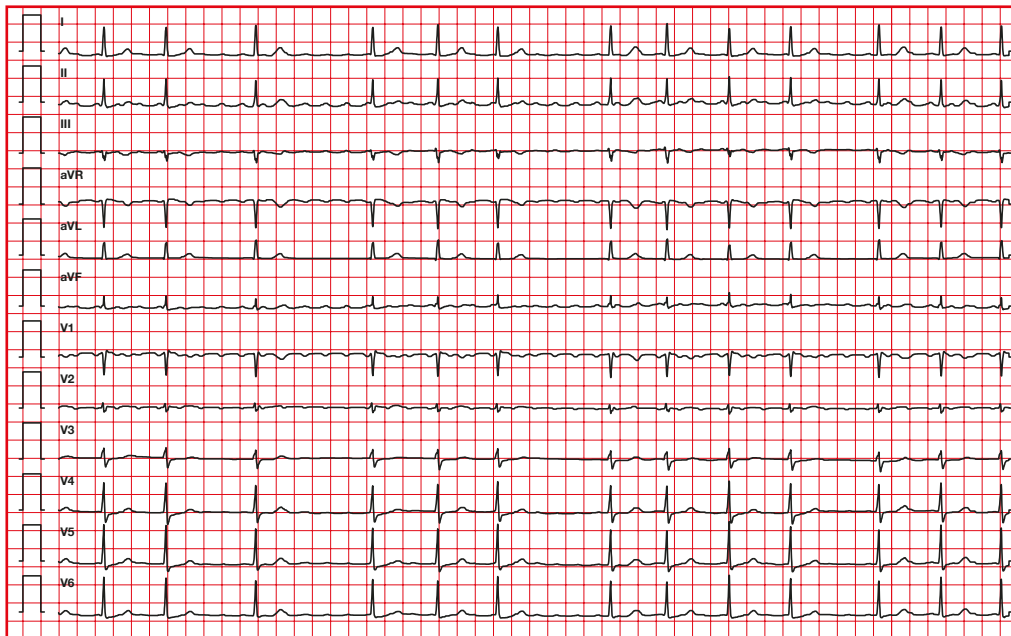
Typical atrial flutter with variable AV conduction



- The term atypical flutter applies to rapid atrial tachycardias with ECG patterns that differ from the typical flutter described above, and also to reentry tachycardias with circuit configuration different from the typical flutter circuit.
- Atypical flutter is often associated with structural heart disease, especially in patients who have undergone heart surgery or extensive catheter ablation for AF treatment.



Atypical flutter

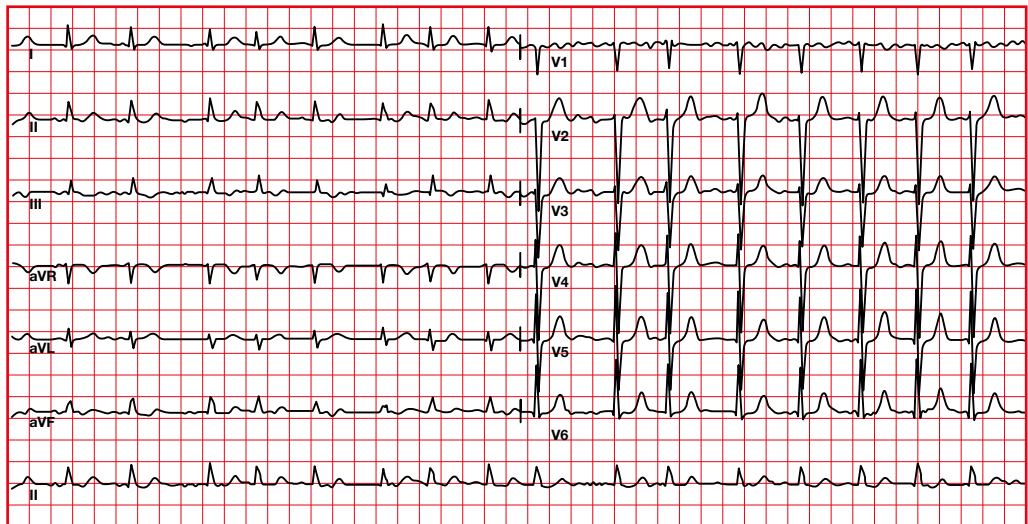
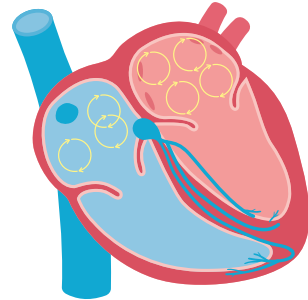


The circuit does not use the cavotricuspid isthmus.

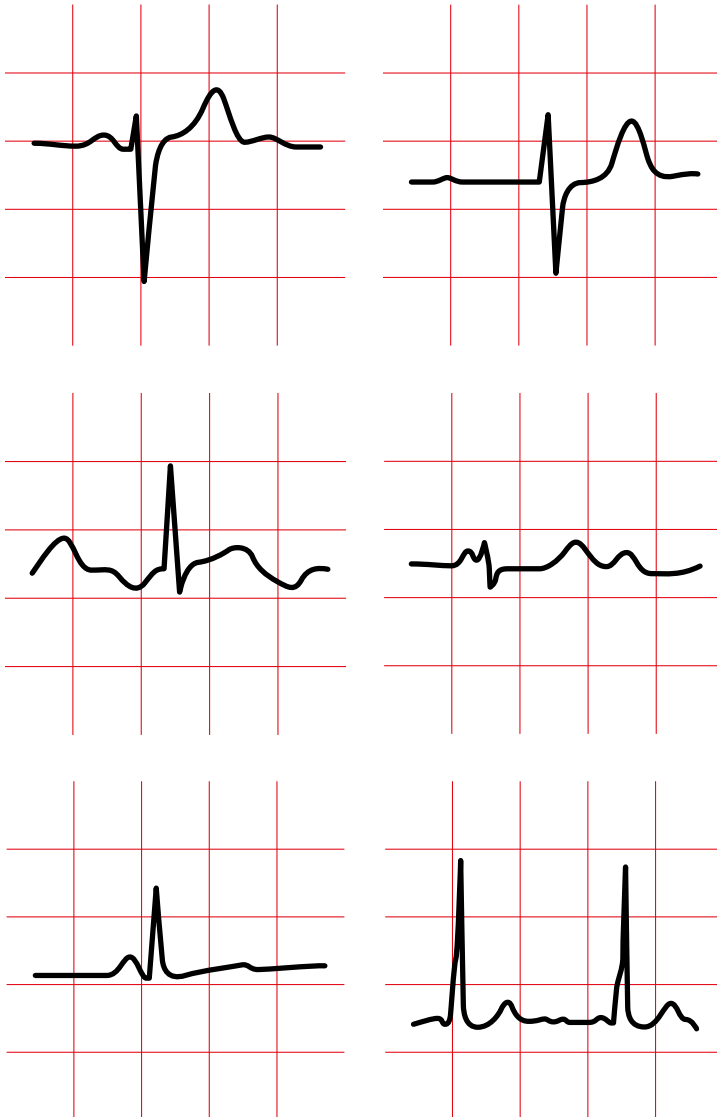5.14. Absence of P wave.

Atrial fibrillation

- Fast atrial rate (between 400 and 700 per minute). It is a disorganized rhythm, without the ability to generate atrial contraction.
- We will observe the presence of f waves (atrial fibrillation waves).
- The ventricular rhythm is irregular (except in complete AV block).

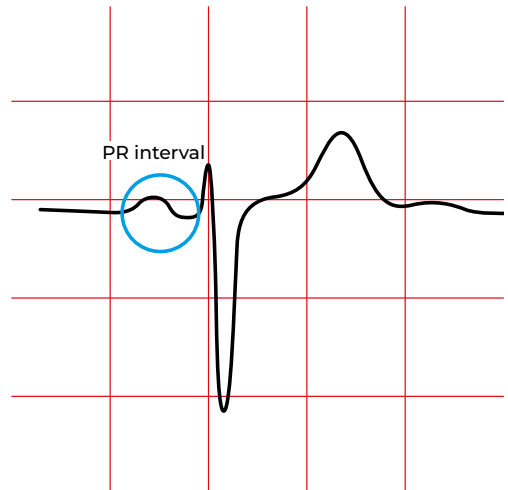


6. PR interval and segment

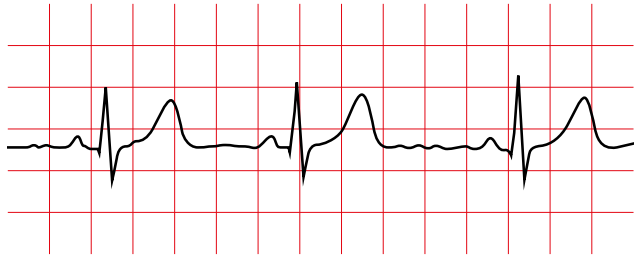


6.1. PR Interval

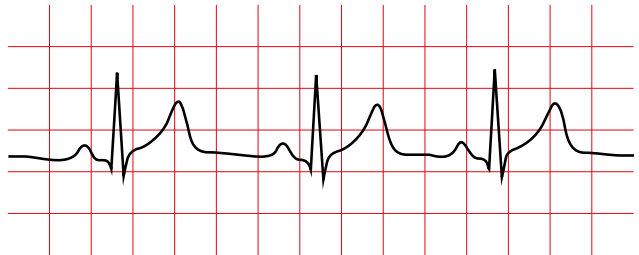
The normal PR is shorter during childhood and lengthens in adulthood.



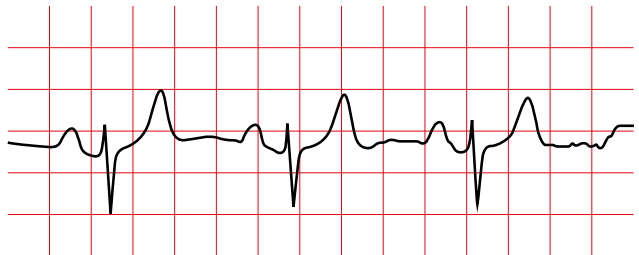
Children
0.10 - 0.12



Teenagers
0.12 - 0.16



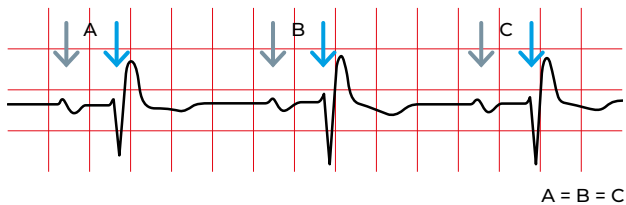
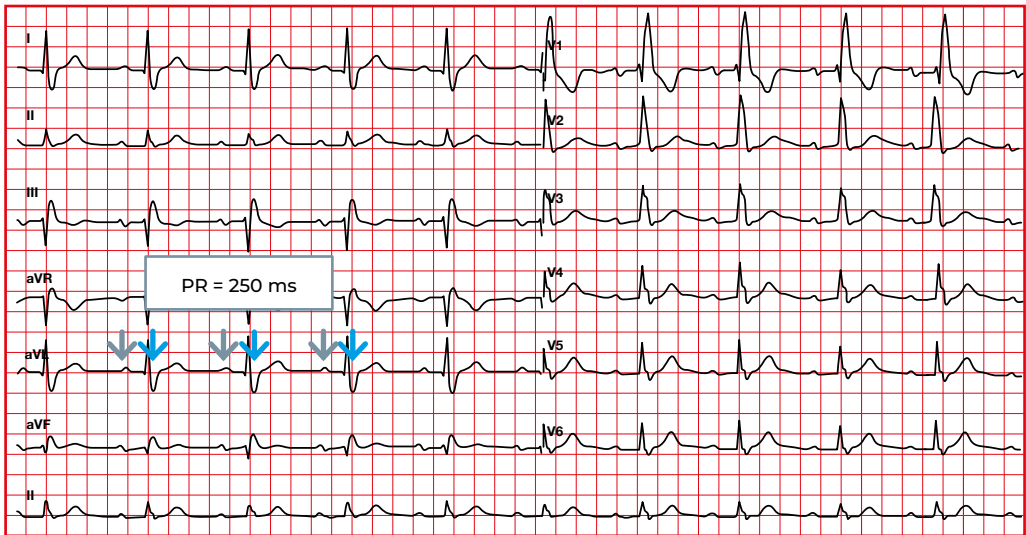
Adults
0.12 - 0.20



Normal PR

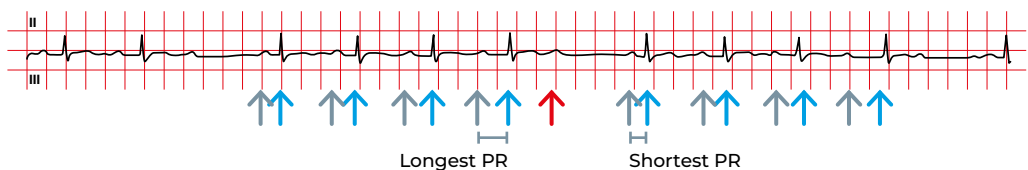
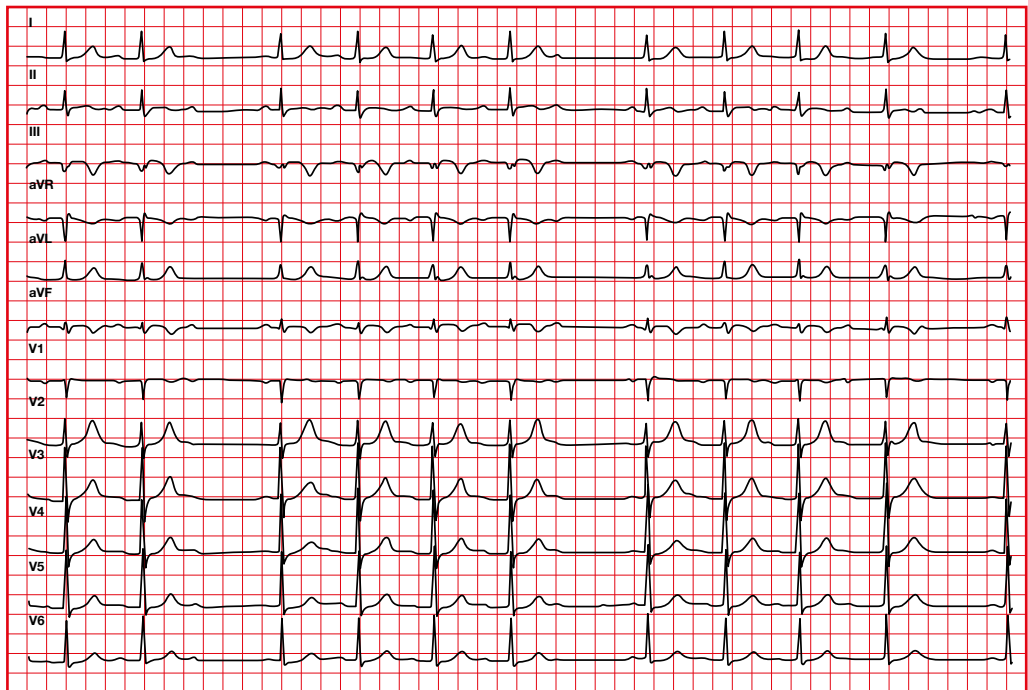
6.2. PR interval abnormalities. First-degree Atrioventricular (AV) block

- Each P is followed by a QRS.
- PR > 0.20 seconds (in children > 0.18 seconds).
- Normally with a constant PR.
- Regular rhythm.



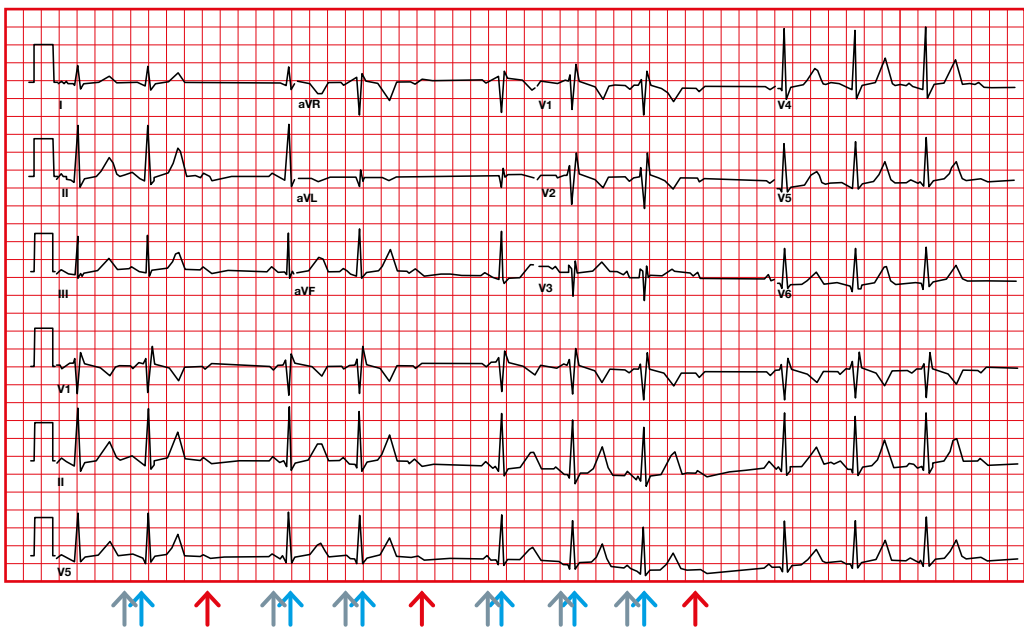
6.3. PR interval abnormalities. Second-degree AV block type 1 (Mobitz I or Wenckebach)

- We will find that some Ps are blocked.
- Progressive prolongation of the PR interval and shortening of the RR interval until a P is blocked and is not followed by a QRS.
- The RR interval that contains the blocked P is less than two PP intervals.
- Group beating pattern is usually seen, ventricular rhythm may appear irregular.



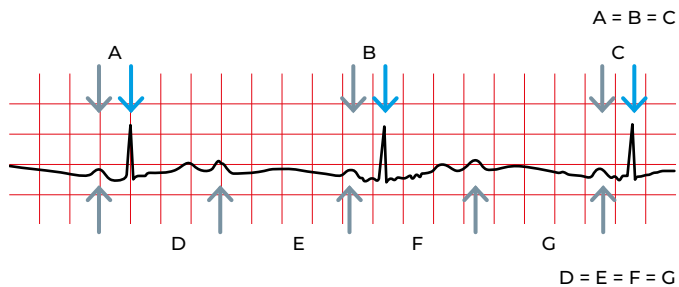
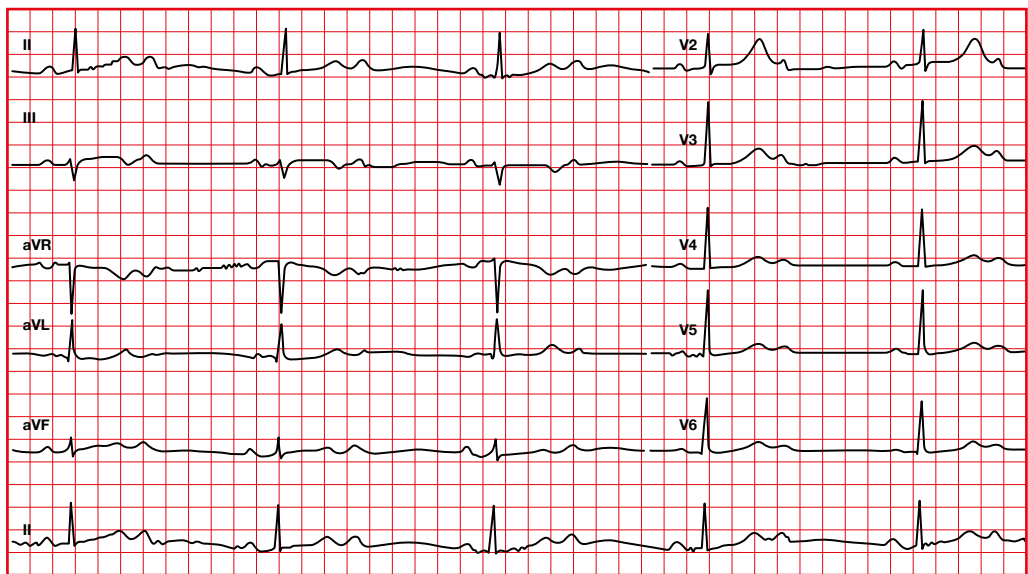
6.4. PR interval abnormalities. Second-degree AV block type 2 (Mobitz II)

- We will find that some P waves are blocked.
- Constant PR.
- There is no change in the PR or RR before a blocked P.
- RR containing the blocked P is exactly twice the PP interval.



6.5. PR interval abnormalities. Second-degree AV block type 2:1

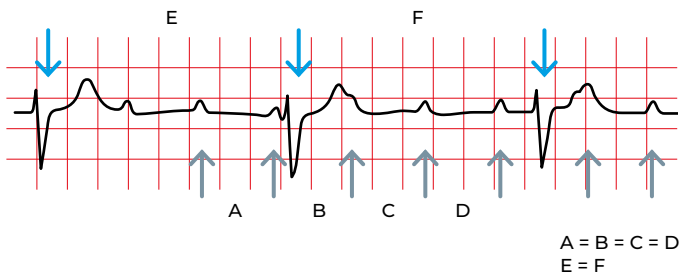
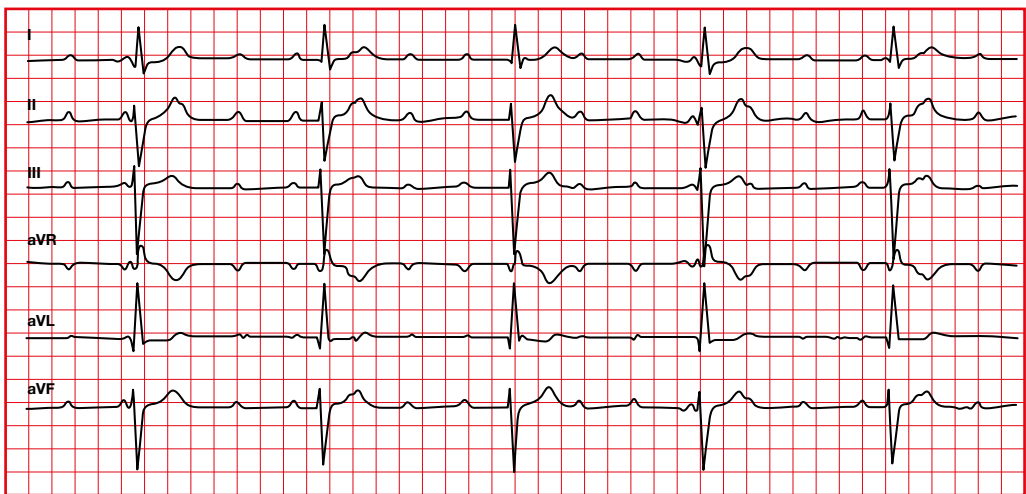
- It can be Mobitz I or II.
- If the QRS is wide, with bundle branch block or bifascicular block, it will probably be Mobitz II.



6.6. PR interval abnormalities.

Third-degree AV block

- The atrial and ventricular rhythms are independent and regular.
- The atrial rate is usually faster than the ventricular rate (more P than QRS).
- The P wave can be hidden within a QRS or a T.
- If the ventricular rate is faster than the atrial rate there is AV dissociation, not AV Block.



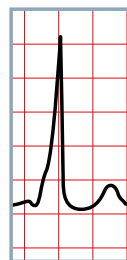
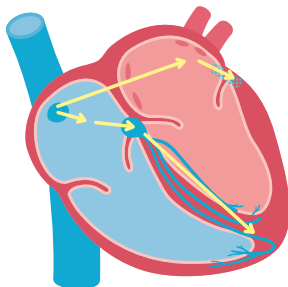
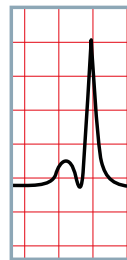
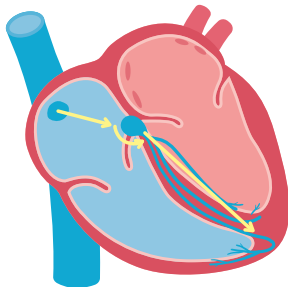
6.7. PR interval abnormalities.

Short PR

- It is associated with junctional arrhythmias or pre-excitation syndromes.
- There is early ventricular excitation.

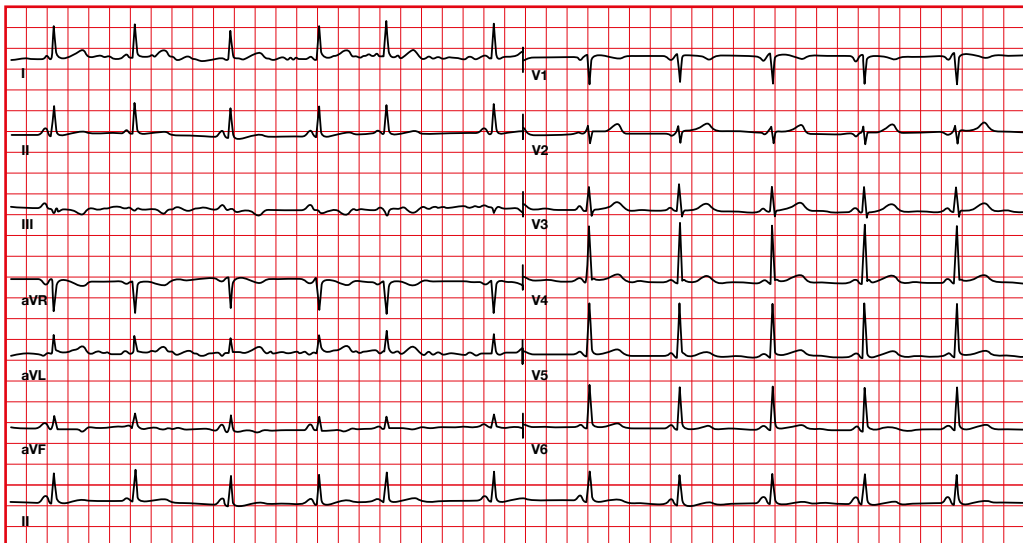
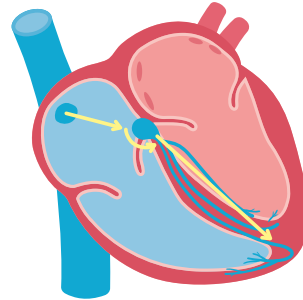
Short PR:

- Without delta wave. Ventricular excitation follows the normal route (without pausing in the AV node).
- With delta wave. A different area of the ventricle is stimulated prematurely (through an abnormal pathway).



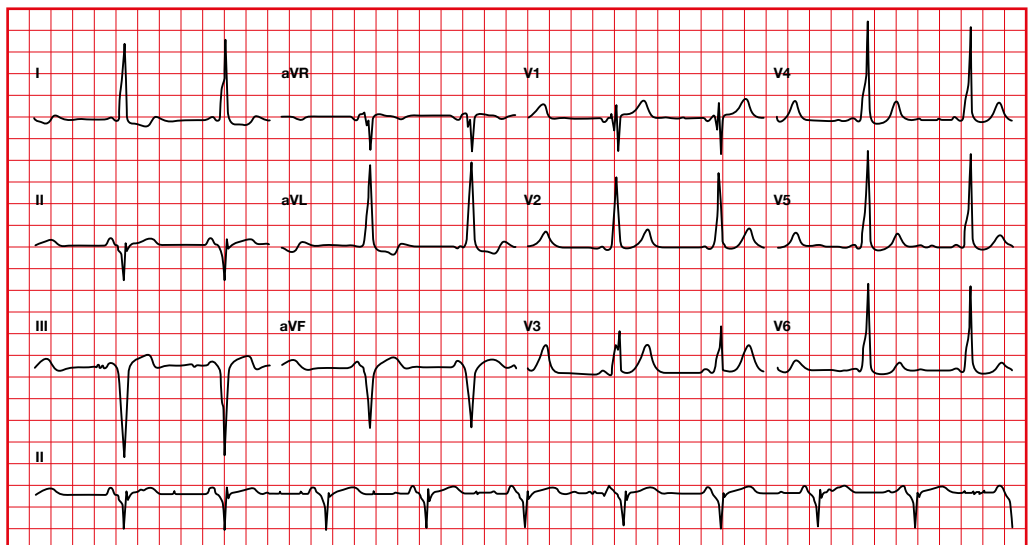
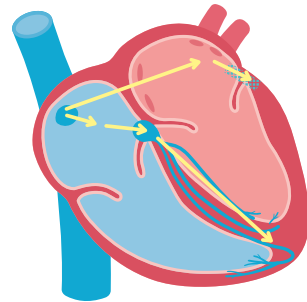
6.8. PR interval abnormalities. Short PR via atriofascicular pathway (James fibers)

- Normal P axis and morphology.
- PR less than 0.12 seconds.
- Without delta wave (QRS less than 0.11).
- There is no AV dissociation.
- Both the P wave and the QRS complex are normal, but the PR segment has disappeared due to the faster activation of the ventricle, without slowing down in the AV node.
- If tachyarrhythmias occur, it is called Lown-Ganong-Levine syndrome.



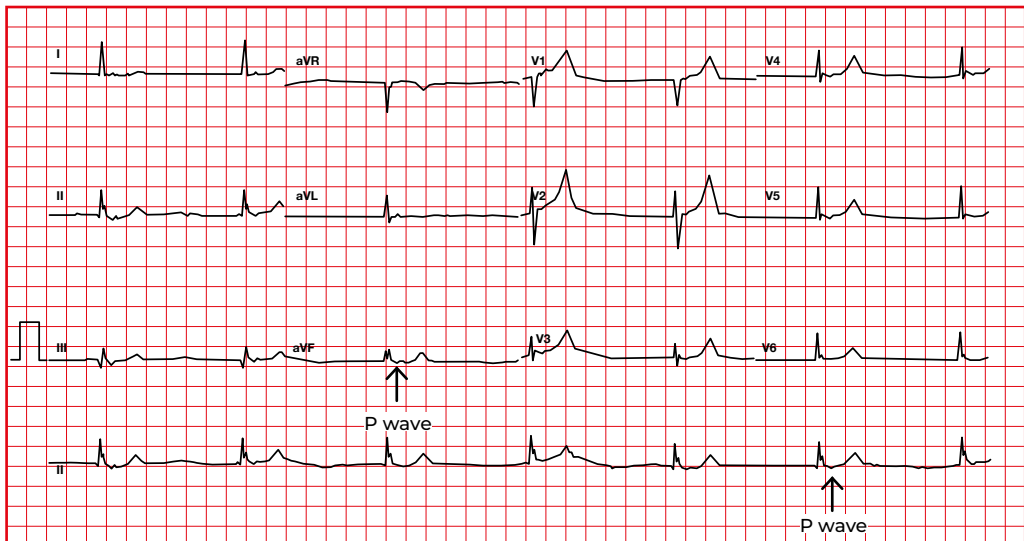
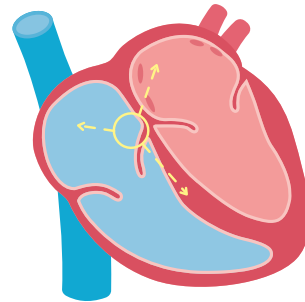
6.9. PR interval abnormalities. WPW pattern (excitation through an atrioventricular pathway, bundle of Kent)

- Normal P axis and morphology.
- PR less than 0.12 seconds.
- Wide QRS (> 0.10 s) caused by the delta wave.
- Changes in the ST-T (in direction opposite to the QRS).
- If tachyarrhythmias occur, it is called Wolff-Parkinson-White syndrome.



6.10. PR interval abnormalities. Nodal or junctional rhythm

- The AV junctional pacemaker exceeds the sinus pacemaker, either by increasing the AV node automaticity or by decreasing the sinus node automaticity.
- Retrograde atrial activation.
- Abnormal P in axis and morphology (P negative in II, III, aVF).
- If there is retrograde conduction through the fast av nodal pathway, the P will appear very quickly and next to the QRS (RP < PR).
- If there is retrograde conduction through the slow av nodal pathway, the P wave will be farther away from the QRS (RP > PR).
- Junctional escape rhythm: HR 40-60 beats per minute.
- Accelerated junctional rhythm: HR 60-100 beats per minute.
- Junctional tachycardia: HR > 100 beats per minute.

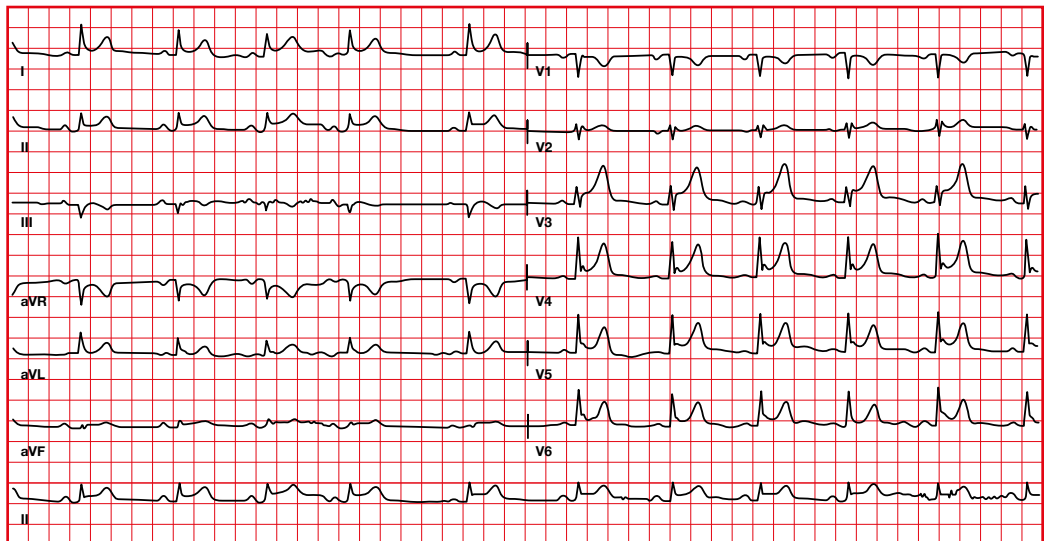


6.11. PR segment abnormalities. Pericarditis

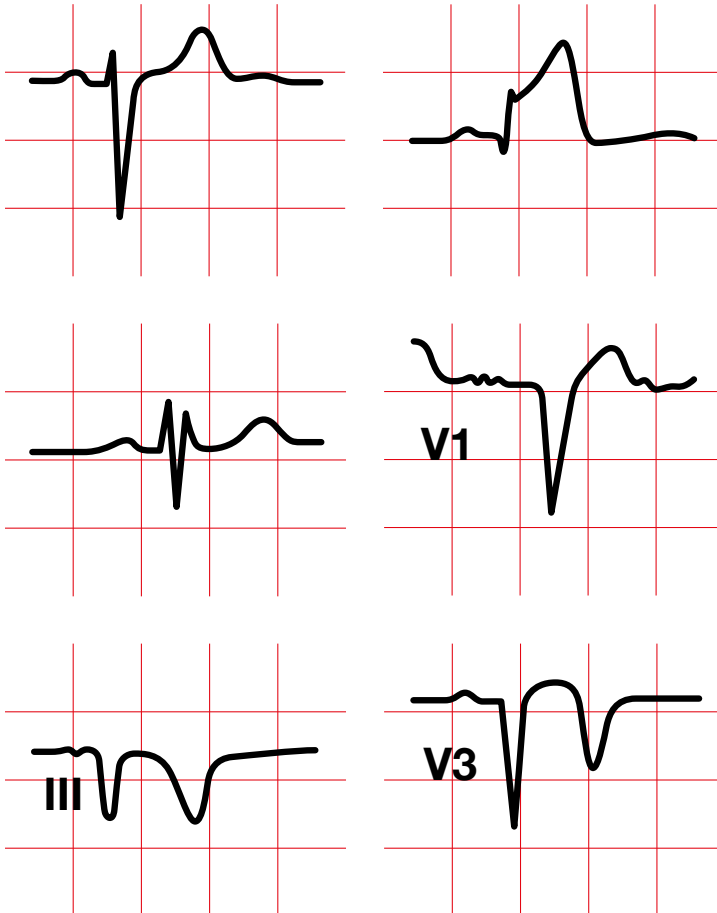
- Diffuse ST segment elevation.
- PR segment depression in lead II.
- PR segment elevation in lead aVR.

If there is a pericardial effusion:

- QRS with low voltage ($R + S < 5$ mm in limb leads, or < 10 mm in precordial leads).
- Electrical alternans.

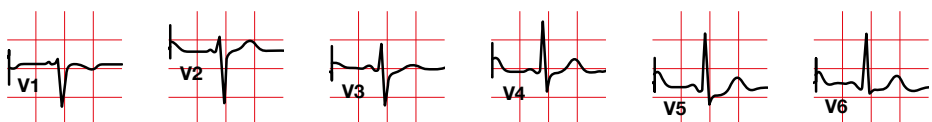
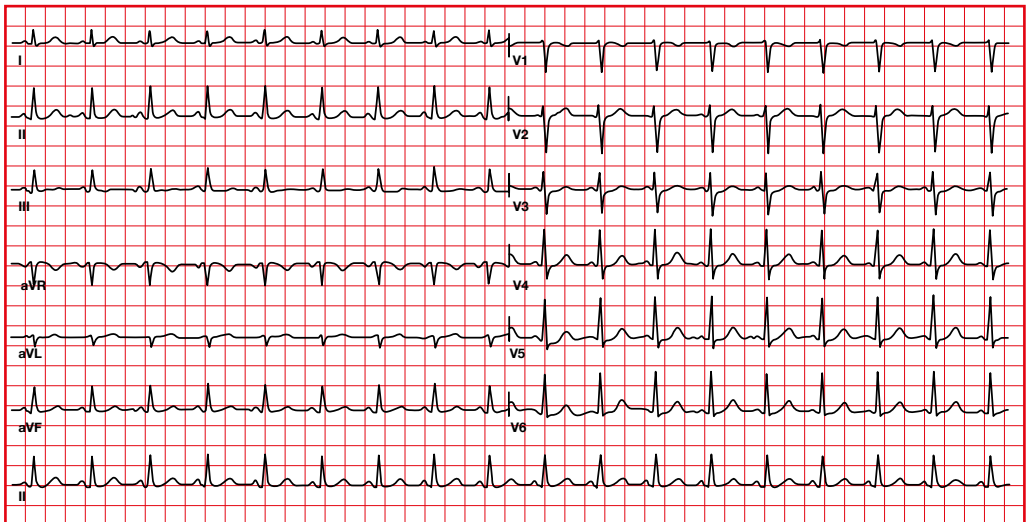
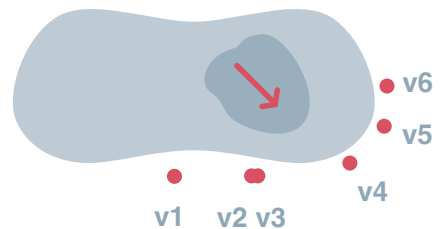


7. QRS complex



7.1. QRS complex voltage transition in precordial leads

- The R of the QRS complex becomes more positive from V1 to V5.
- The S of the QRS complex becomes more negative from V1 to V6.
- The R/S transition usually appears in V3-V4.
- In V6 the R can be smaller than in V5.



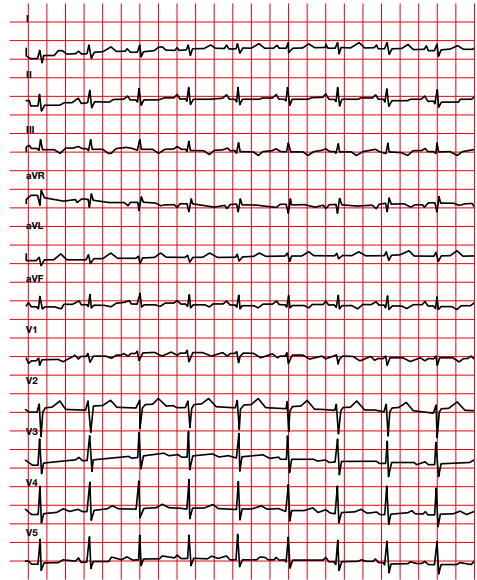
7.2. QRS complex voltage abnormalities. Low voltage

- Limb leads: low voltage QRS complex when < 5 mm (adding R and S).
- Precordial leads: low voltage QRS complex when < 10 mm (adding R and S).

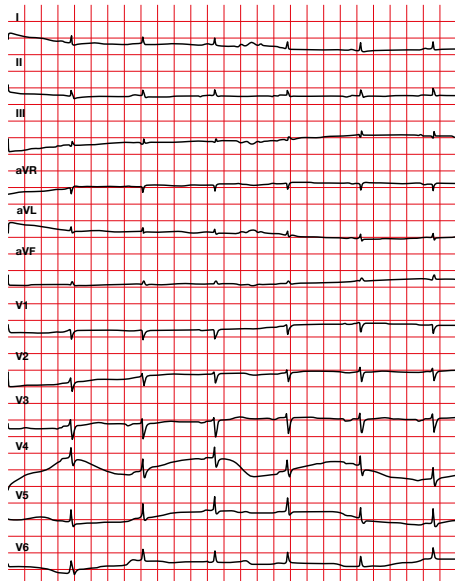
Causes

- Pericardial effusion.
- Pleural effusion.
- Infiltrative cardiomyopathies.
- Diffuse coronary heart disease.
- Chronic lung disease.
- Obesity.
- Myxedema.

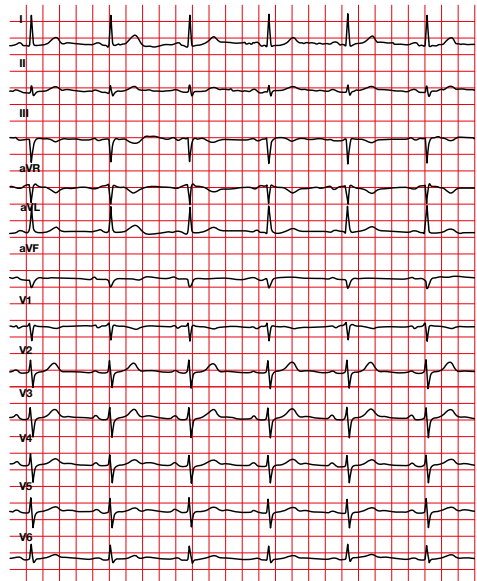
Amyloidosis



With pericardial effusion



Without pericardial effusion



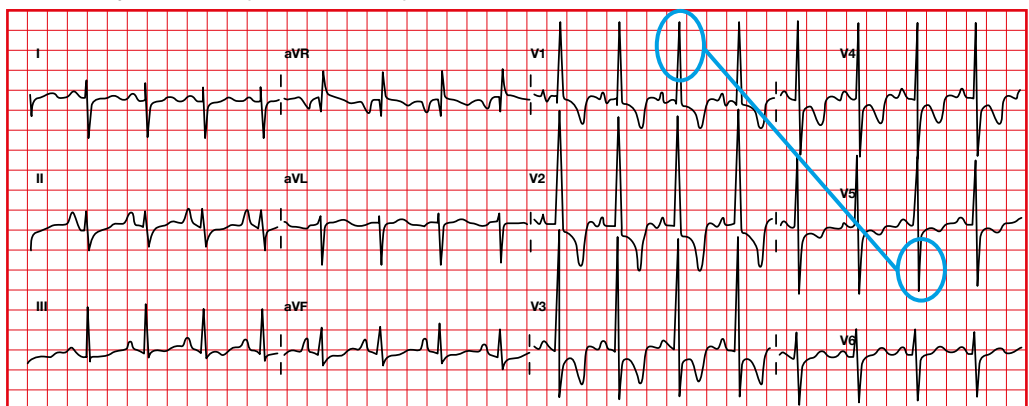
7.3. QRS complex voltage abnormalities. Right ventricular hypertrophy

- Right axis > 110 (lead I more negative than positive).
- Dominant R in the right (there are more forces to the right due to hypertrophy):
 - $V1 R > S$.
 - $V5$ or $V6 R < S$.
 - R in $V1 \geq 7$ mm.
 - $(R$ in $V1$ plus S in $V5/V6) > 10.5$ mm.
- Right atrial enlargement.
- ST-T changes (ST depression, T inversion) in right precordial leads.

Causes

- Lung disease.
- Congenital heart disease.

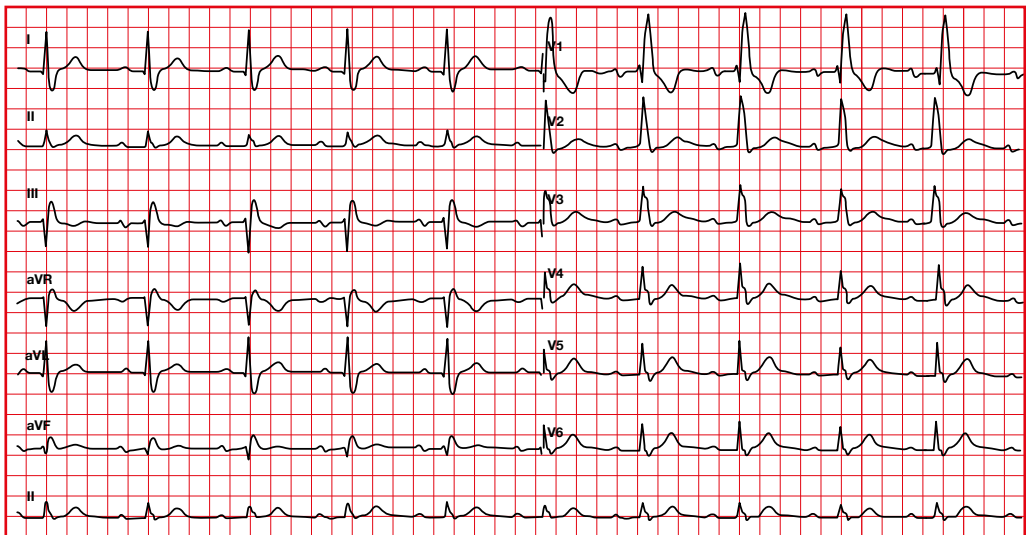
Sokolow-Lyon criteria $(R V1 + S V5/V6) > 10.5$ mm



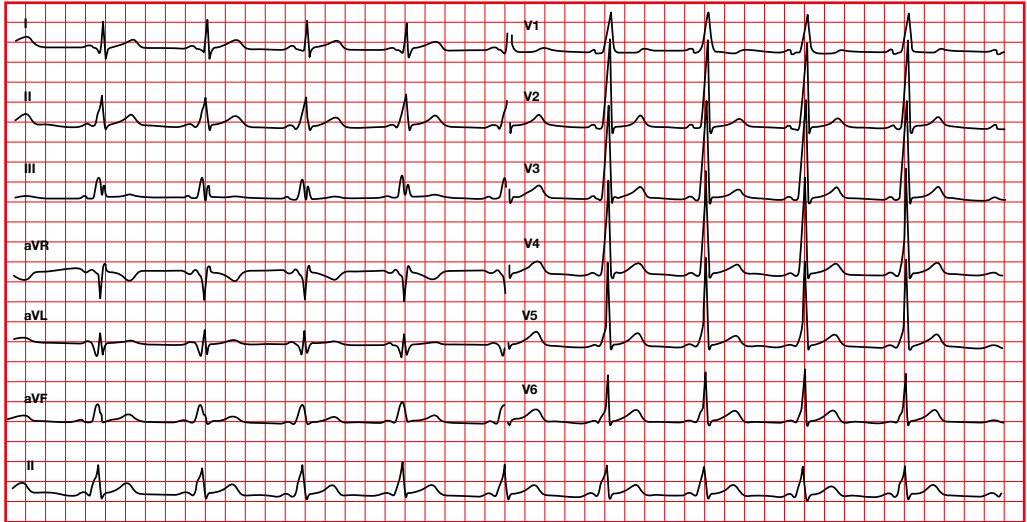
You must exclude:

- Posterior infarction.
- Right bundle branch block.
- Pre-excitation.
- Cardiac dextroposition.
- Left posterior fascicular block.
- Normal variant in children.
- Septal hypertrophy.

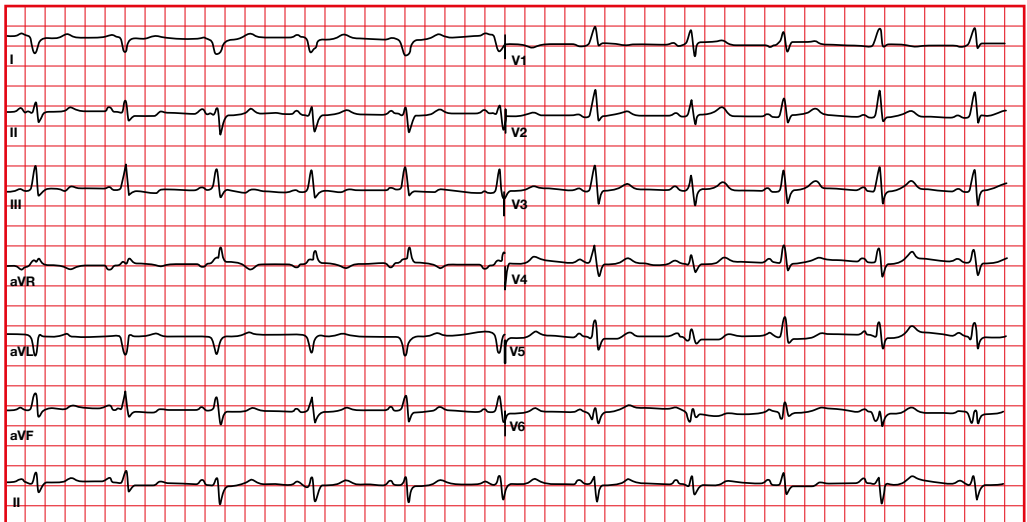
Right bundle branch block



Pre-excitation



Left posterior fascicular block

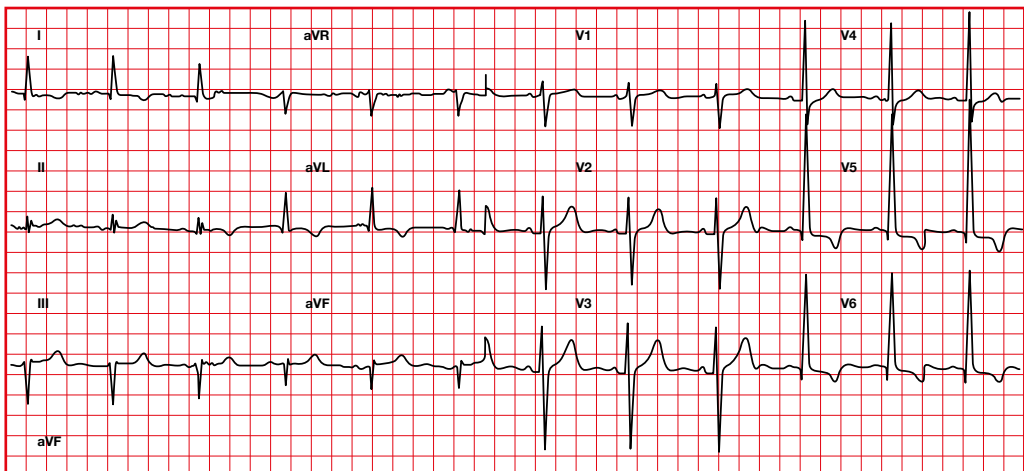


7.4. QRS complex voltage abnormalities. Left ventricular hypertrophy

- R more dominant in the left (there are more forces in the left due to hypertrophy).
 - Deep S waves will be present in the right precordial leads.
 - It takes more time to activate endocardium-epicardium, the time for ventricular activation is increased, therefore QRS is lengthened.
- Often seen:
- Left atrial enlargement.
 - Left axis deviation.
 - Loss of anterior forces (small anterior R waves).
 - Without Q in I, V5, V6.
 - Q in II, III, aVF.

Causes

- Hypertension.
- Valvular disease (aortic stenosis).
- Hypertrophic cardiomyopathy.

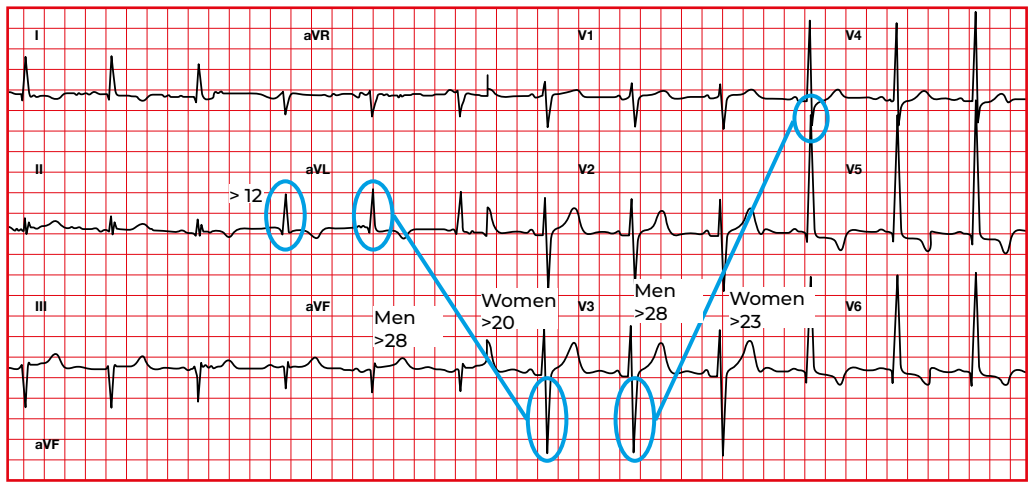


Cornell Criteria:

- Women (R aVL + S V3) > 20 mm.
- Men (R aVL + S V3) > 28 mm.
- Modified Cornell, R in aVL > 12 mm.

Peguero-Lo Presti criteria:

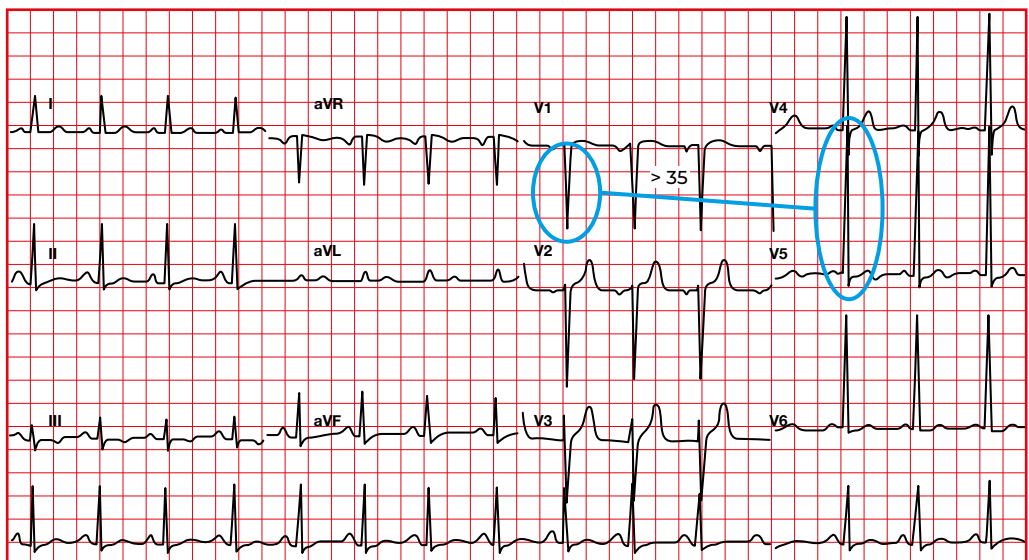
- Deepest S + S in V4:
- Women > 23 mm.
 - Men > 28 mm.



Sokolow-Lyon criteria:

(S V1 + R V5/V6).

- > 35 mm (> 30 years of age).
- > 40 mm (between 20 and 30 years of age).
- > 60 mm (between 16 and 19 years of age).

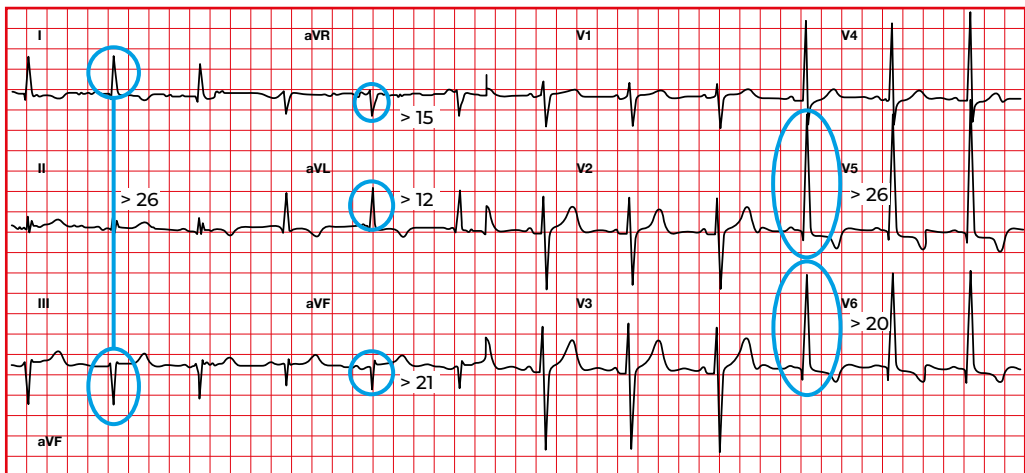


Other hypertrophy criteria:

- R V5 > 26 mm.
- R V6 > 20.

Limb leads:

- (R I + S III) \geq 26 mm.
- R I \geq 14 mm.
- S aVR \geq 15 mm.
- R aVL > 12 mm.
- R aVF > 21 mm.

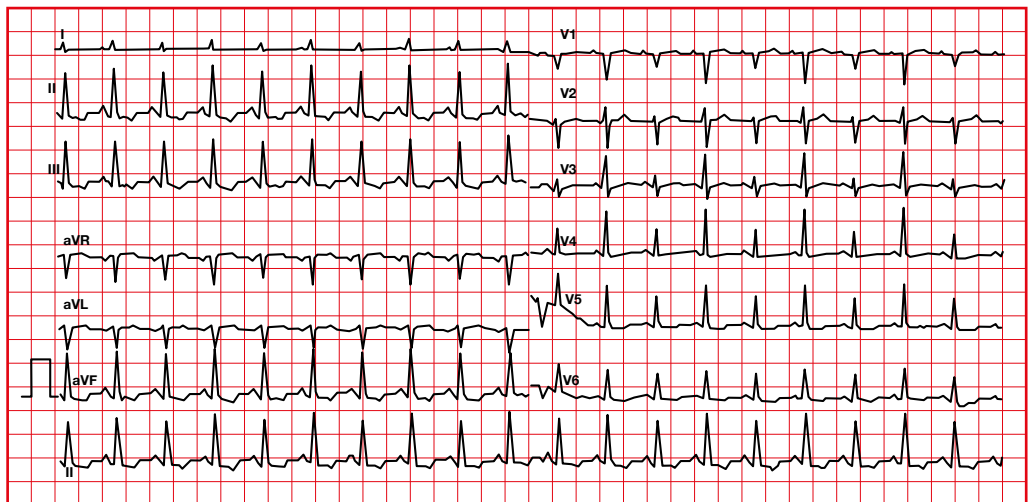


7.5. QRS complex voltage abnormalities. Electrical alternans

Regular alternating of P, QRS or T amplitude, alone or in combination. The complexes must originate from a same pacemaker.

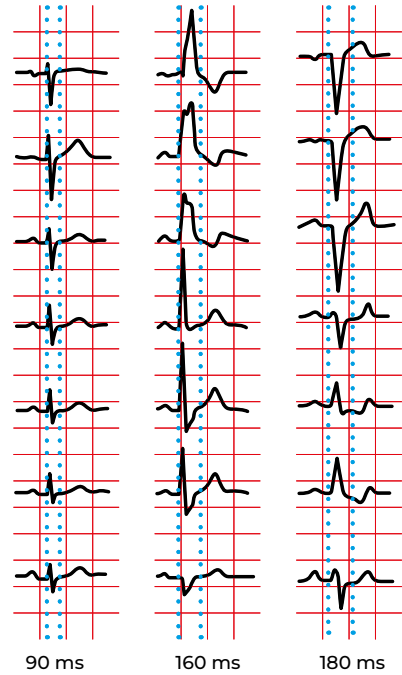
Causes

- Pericardial effusion.
- Severe heart failure.
- Coronary heart disease.
- Rheumatic heart disease.
- Supra or ventricular tachycardia.

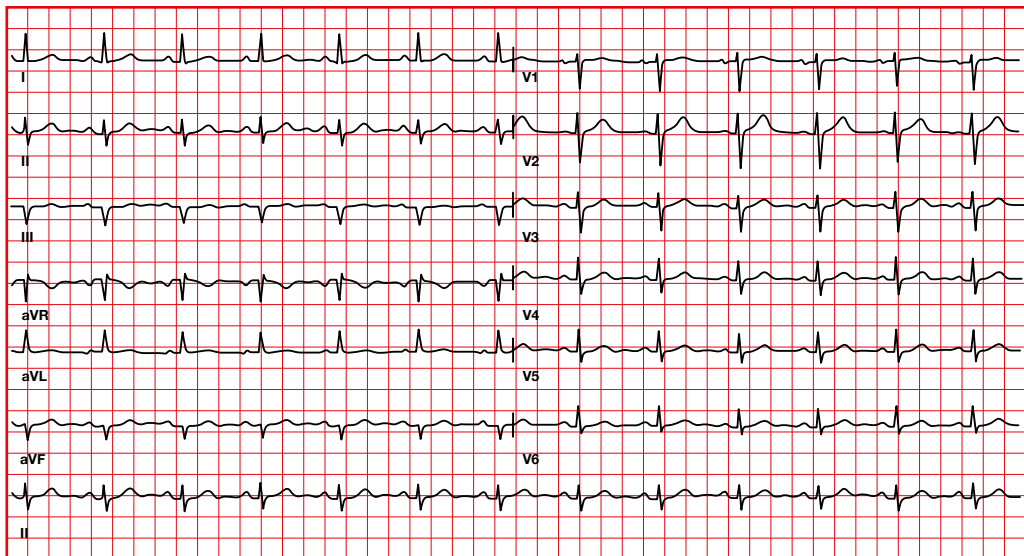


7.6. QRS complex morphology abnormalities

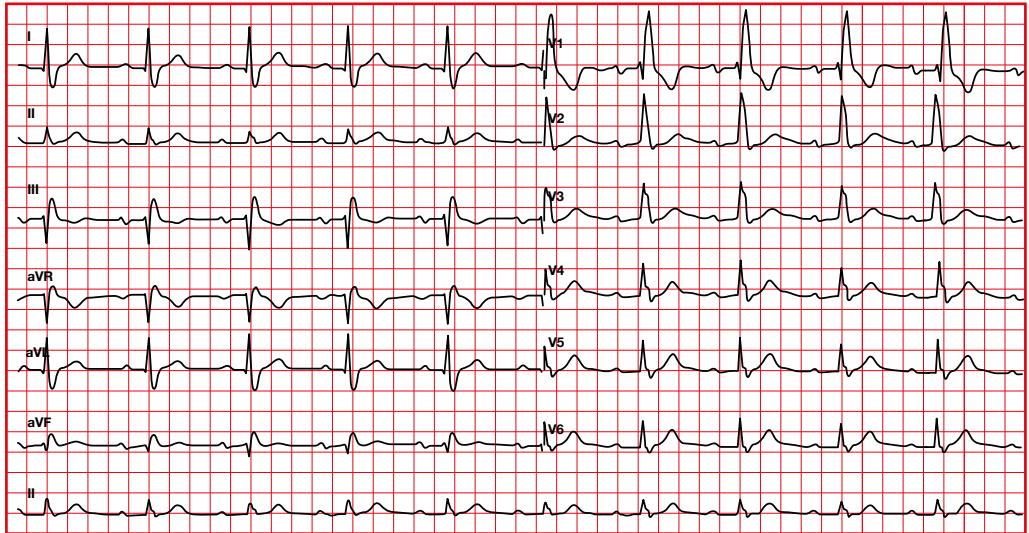
- Due to the blockage in one of the branches, the activation of one ventricle starts from the other branch, so the activation sequence is changed.
- If the blockage is in a main branch, right or left, the activation time will increase (wider QRS).



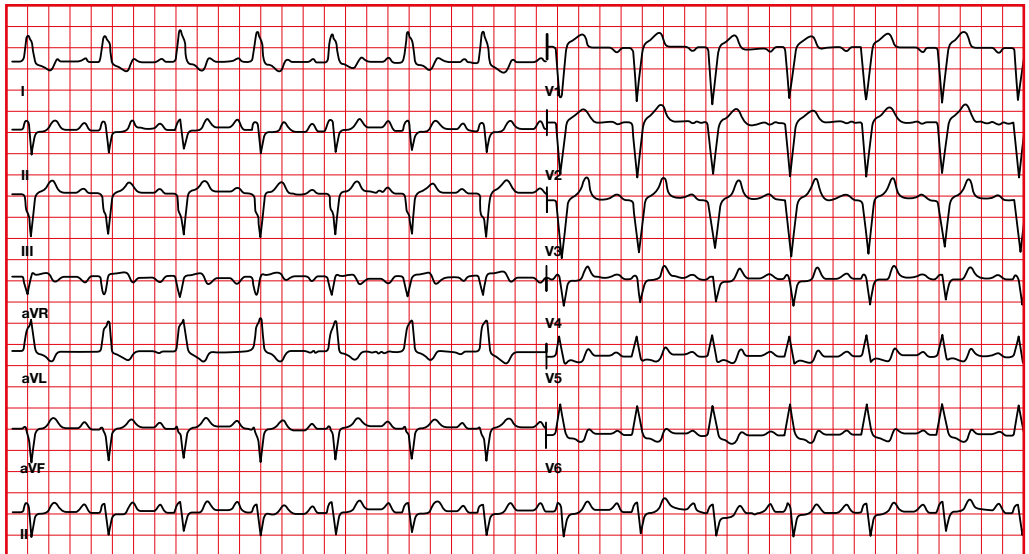
Without blockage



Right bundle branch block



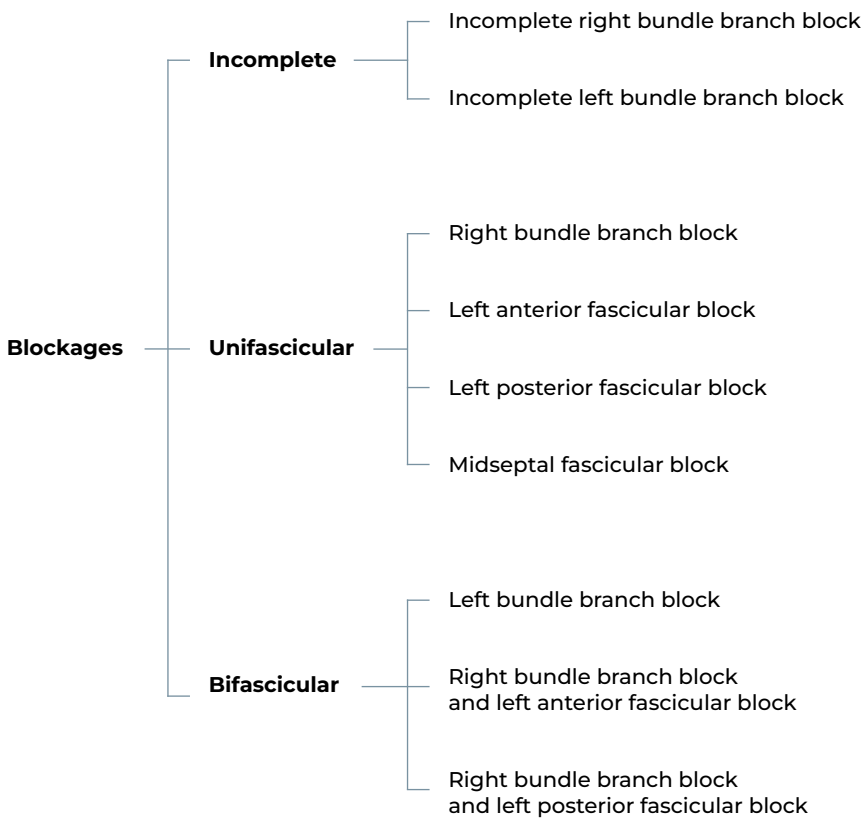
Left bundle branch block



QRS > 120 ms

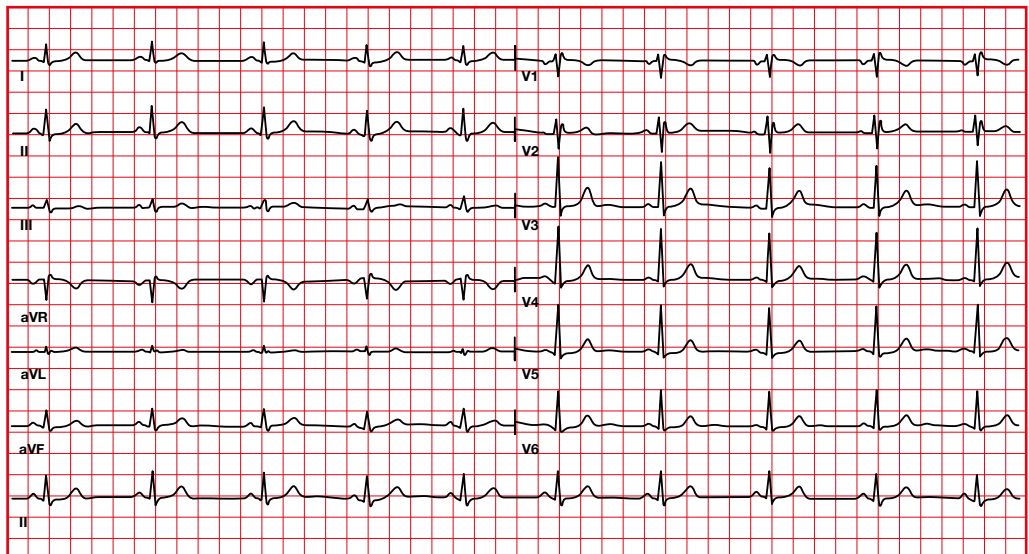
7.7. QRS complex morphology abnormalities. Bundle branch blockages

When there is an alteration in the electrical conduction through the different branches, a change in the QRS morphology, in the depolarization axis and/or an increase in the QRS duration may be observed.



7.8. QRS complex morphology abnormalities. Incomplete right bundle branch block

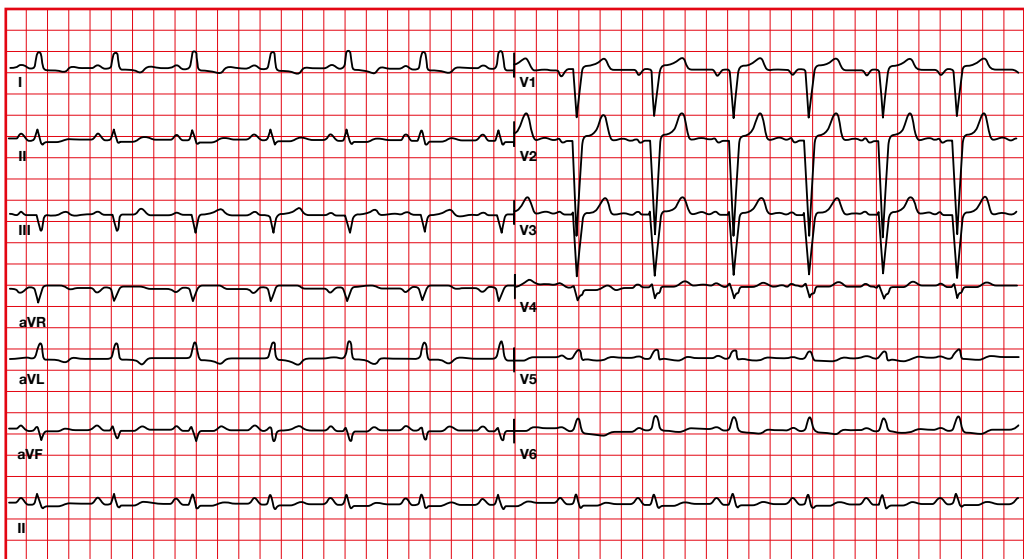
- QRS between 110 and 120 milliseconds.
- Right bundle branch block morphology (rsR' in V1).
- Other causes of rsR' with QRS less than 0.12 seconds includes:
 - Normal variant.
 - Right ventricular hypertrophy.
 - Posterior infarction.
 - Lead misplacement.
 - *Pectus excavatum*.
 - Hyperkalemia.



7.9. QRS complex morphology abnormalities. Incomplete left bundle branch block

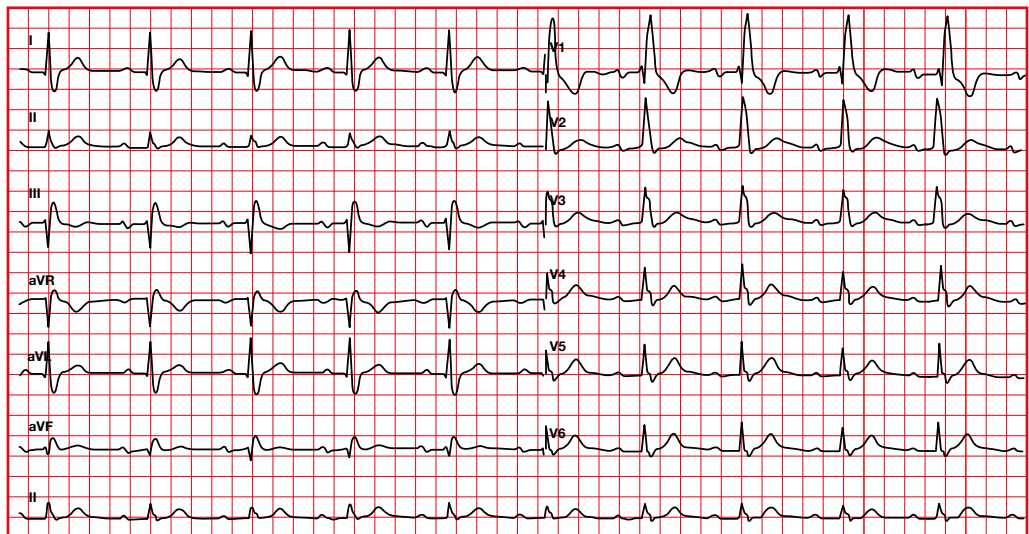
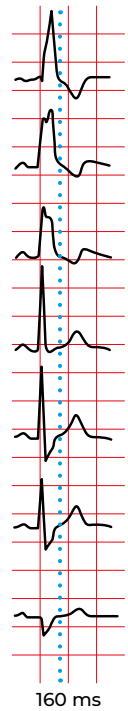
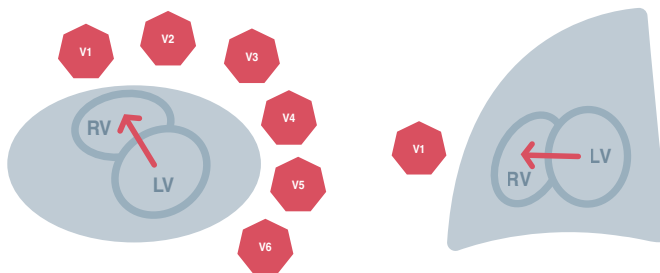
It is diagnosed when there is left bundle branch block morphology but the QRS < 120 ms.

- QRS from 100 to 119 milliseconds.
- Wide R in I, aVL, V5-V6, normally with a notch.
- Without Q or q in I, and in V5-V6.



7.10. QRS complex morphology abnormalities. Right bundle branch block

- Wide QRS (≥ 0.12 seconds).
- R' in V1 and V2 (rsR' or rSR').
- R' normally greater than initial R.
- ST-T changes (ST depression, negative T) in V1, V2.
- Wide S wave in I, aVL, V5, V6.



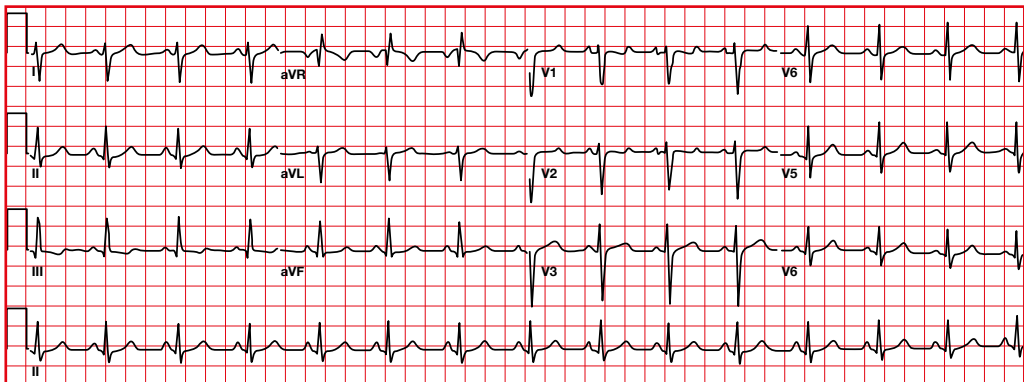
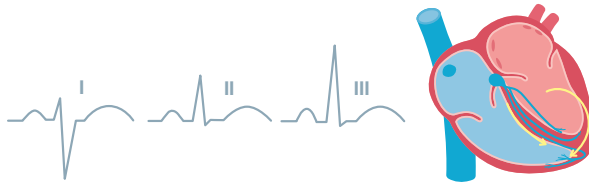
QRS > 120 ms

7.11. QRS complex morphology abnormalities. Left posterior fascicular block

- Axis to the right (+90 to +180).
- Small R in I, aVL.
- Small Q in II, III, aVF (Q less than 0.04 seconds).
- Minimally increased QRS duration.
- Sometimes S1Q3 pattern.

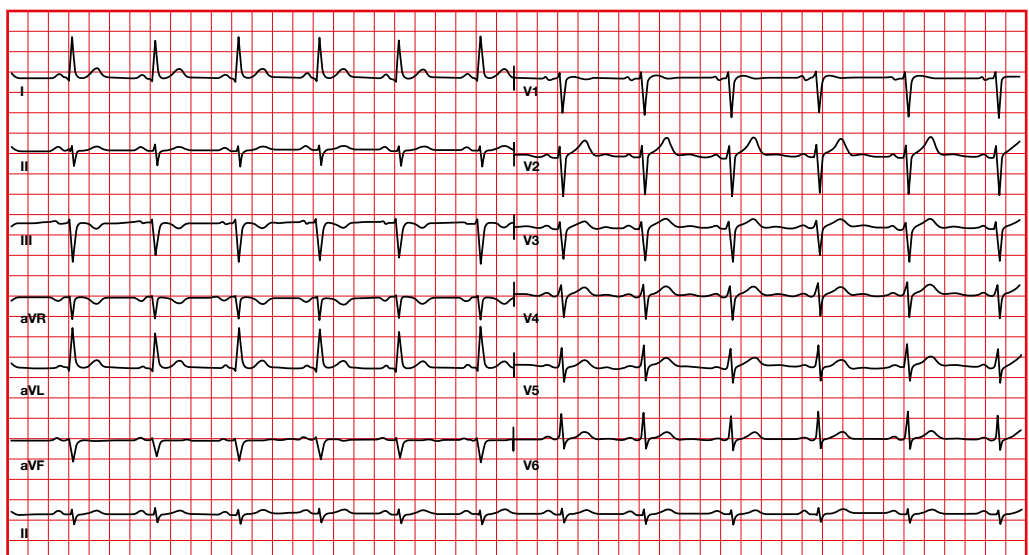
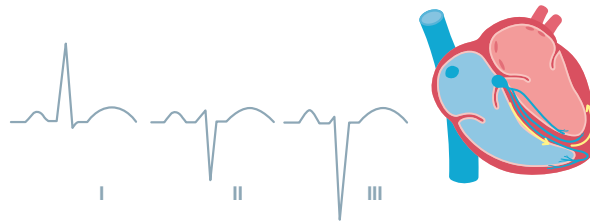
No other factor responsible for axis to the right:

- Right ventricular hypertrophy.
- Ventricular ectopy.
- Hyperkalemia.
- Emphysema.
- Pulmonary embolism.
- Lateral infarction.
- Dextrocardia.
- Lead misplacement.
- Pre-excitation.



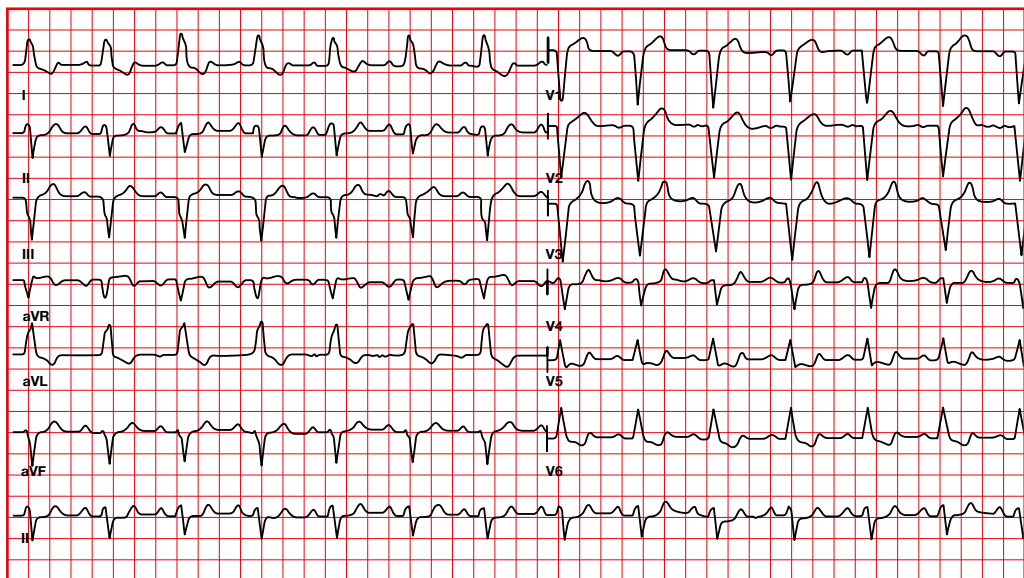
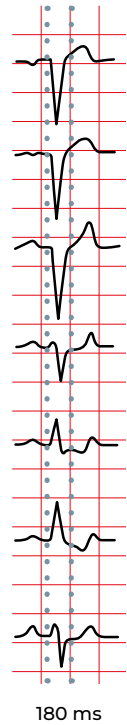
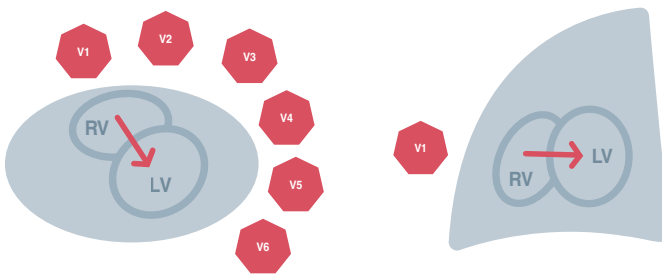
7.12. QRS complex morphology abnormalities. Left anterior fascicular block

- Axis to the left (-45 to -90).
 - Small Q in I and aVL.
 - Small R in II, III, aVF.
 - Minimally increased QRS duration.
 - SIII > SII.
- No other factor responsible for axis to the left:
- Left ventricular hypertrophy.
 - Ventricular ectopic rhythms.
 - Inferior infarction.
 - Emphysema.
 - Left bundle branch block.
 - Atrial septal defect *ostium primum*.
 - Severe hyperkalemia.



7.13. QRS complex morphology abnormalities. Left bundle branch block

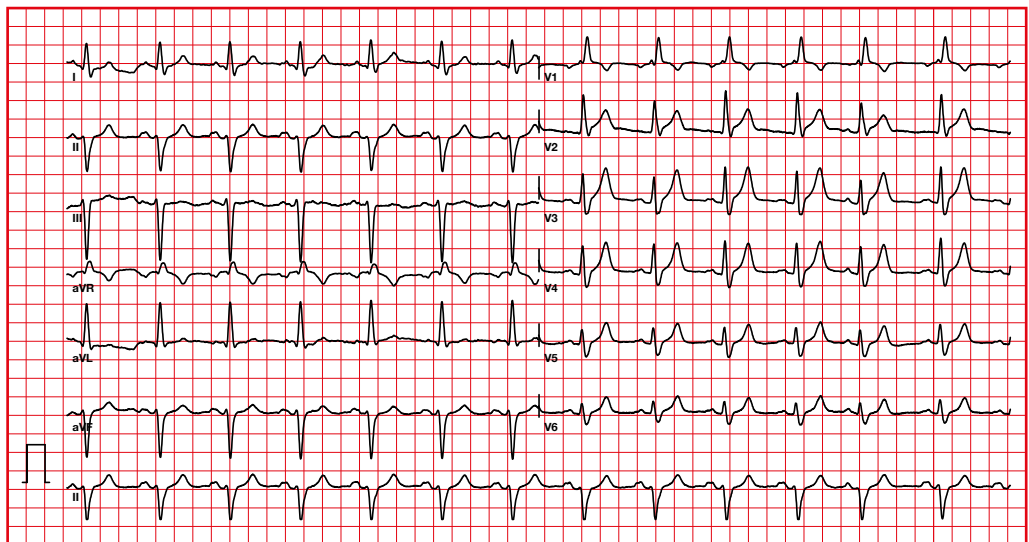
- Prolonged QRS (≥ 0.12 seconds).
- Wide R in I, V5-V6, with a notch.
- ST-T changes in the opposite direction of the QRS.
- rS or QS in the right precordial leads.
- Without Q in I, and in aVL, V5-V6.



QRS > 120 ms

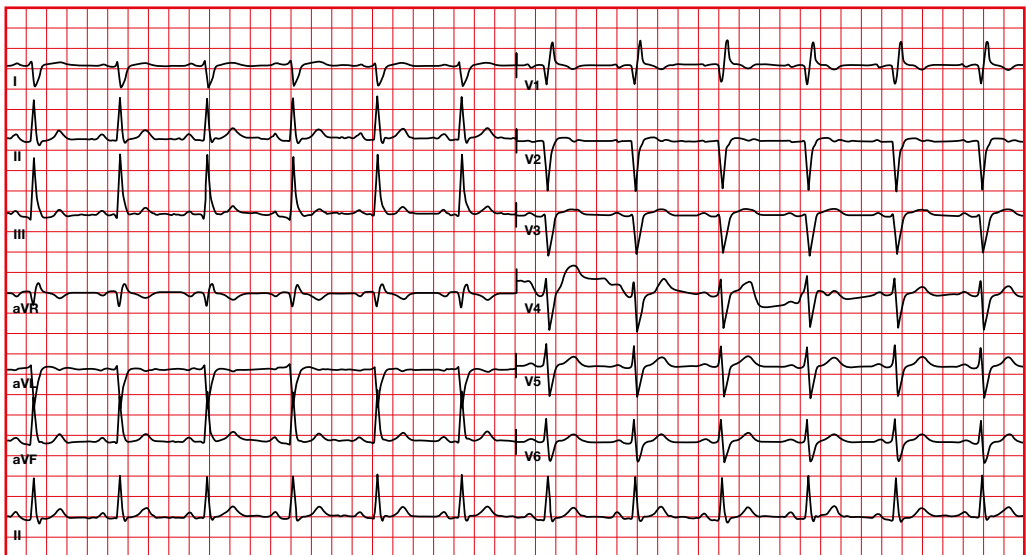
7.14. QRS complex morphology abnormalities. Right bundle branch block + left anterior fascicular block

- R or R' typical of right bundle branch block in V1.
- Initial R and prominent S in II, III, aVF.
- QRS > 0.12 seconds.
- Axis between -45 and -120 .



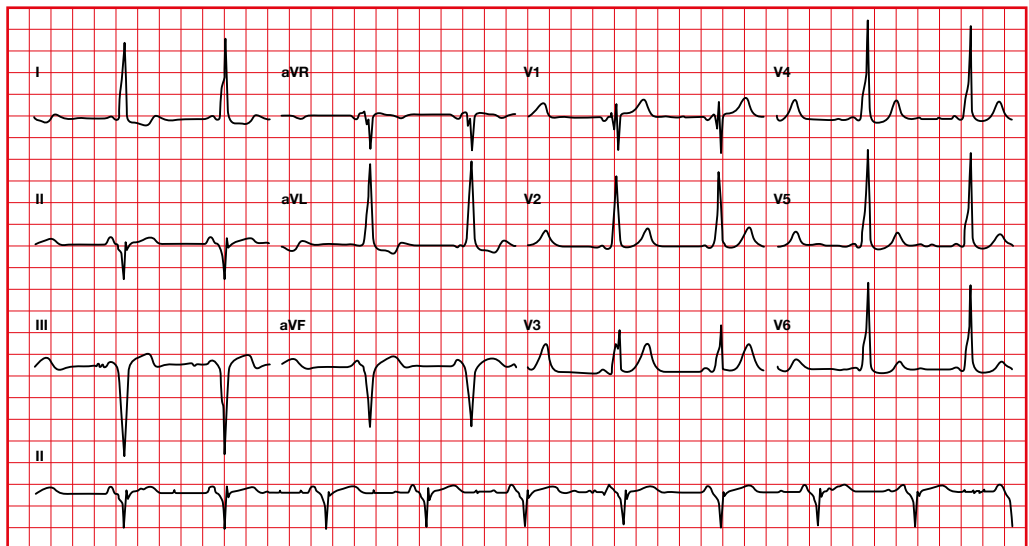
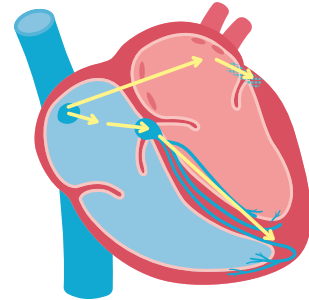
7.15. QRS complex morphology abnormalities. Right bundle branch block + left posterior fascicular block

- R or R' typical of right bundle branch block in V1.
- Initial R and prominent S in I, aVL.
- QRS > 0.12 seconds.
- Axis > +90.



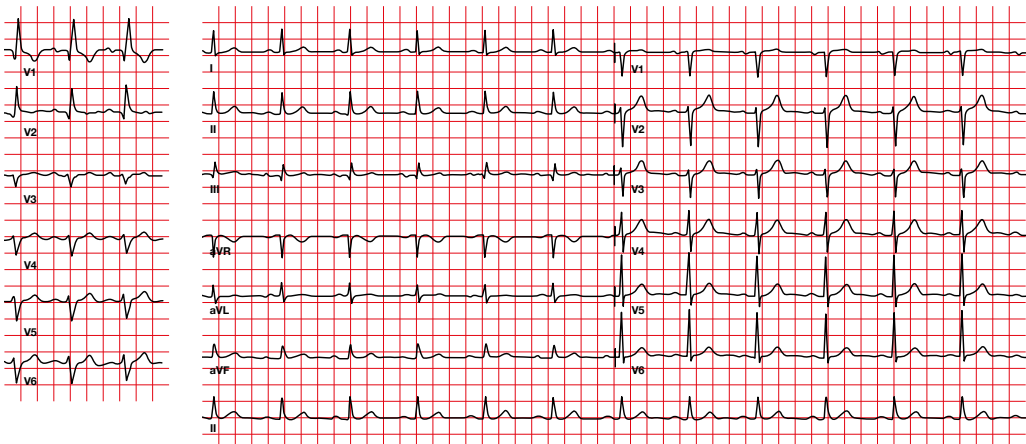
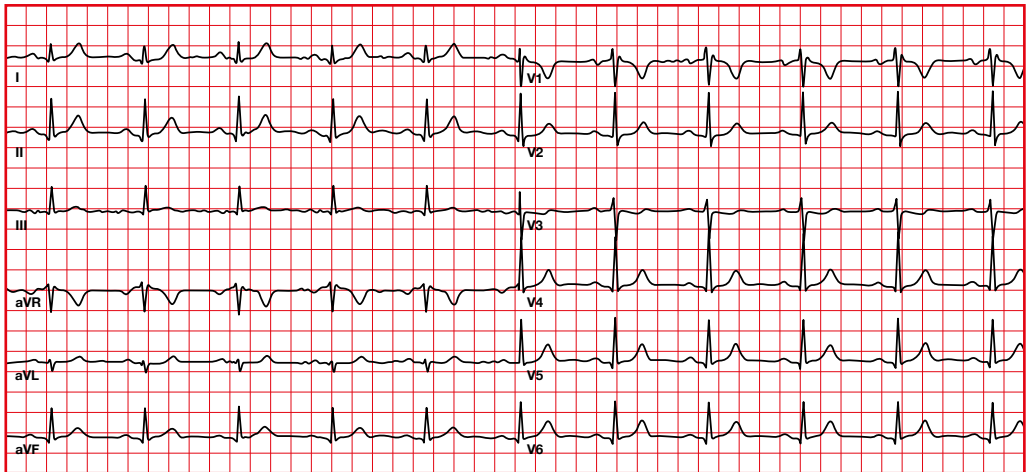
7.16. QRS complex morphology abnormalities. Pre-excitation

- Normal P axis and morphology.
- PR less than 0.12 seconds.
- Delta wave at the beginning of the QRS, resulting in a wide QRS.
- Changes in the ST-T (in the opposite direction to the QRS).



7.17. Q wave

- In most leads you can observe Q (< 0.04 s and amplitude < 2 mm) except in aVR, V1 and V2.
- The Q should not exceed 25% of the R wave.
- An isolated Q wave in III or aVR is considered normal.



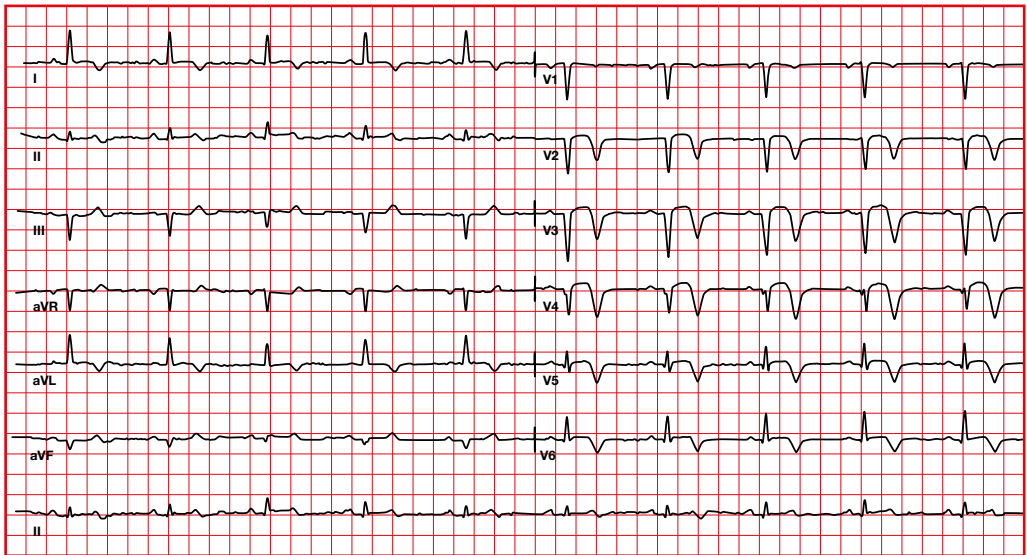
The presence of Q in V1-V2-V3 must be considered abnormal.

Q waves may be increased by infarction, dilatation, hypertrophy or conduction disturbances.

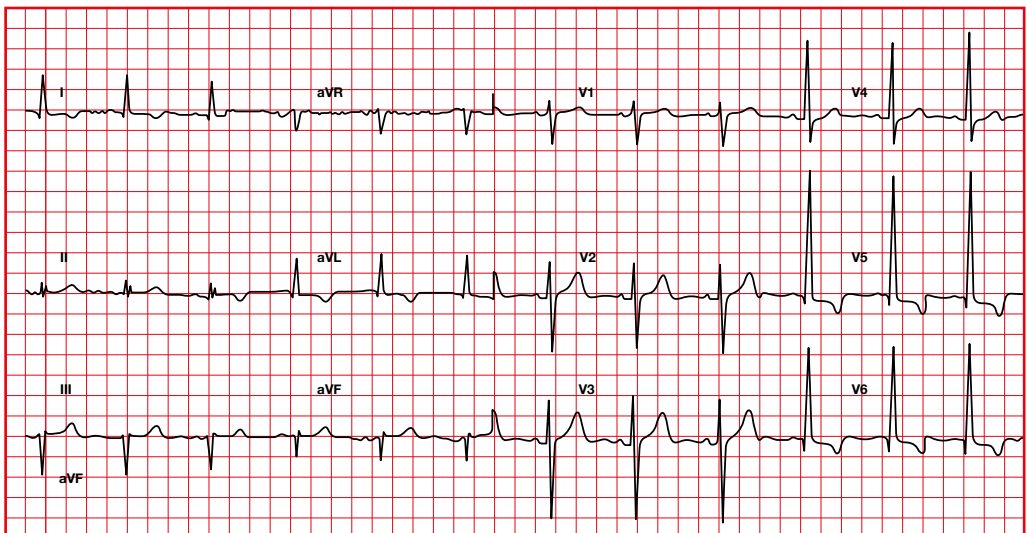
Abnormal Q:

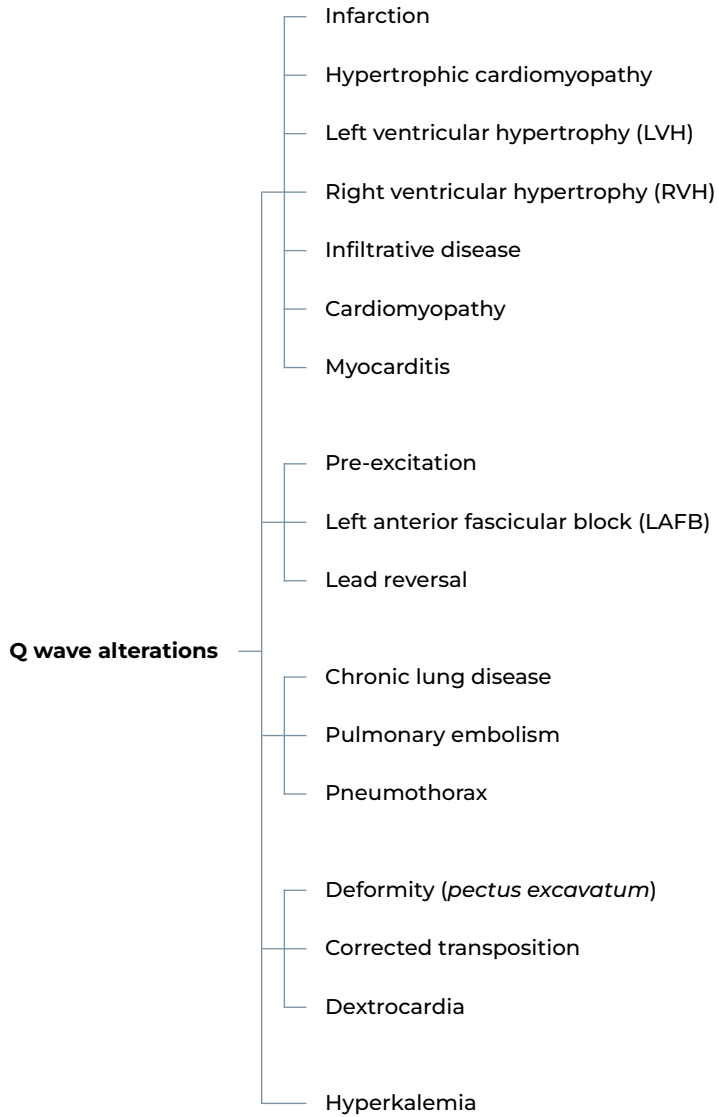
- Duration ≥ 0.03 s in most leads.
- Duration ≥ 0.04 s in III, aVL, aVF, and in V1.

Infarction



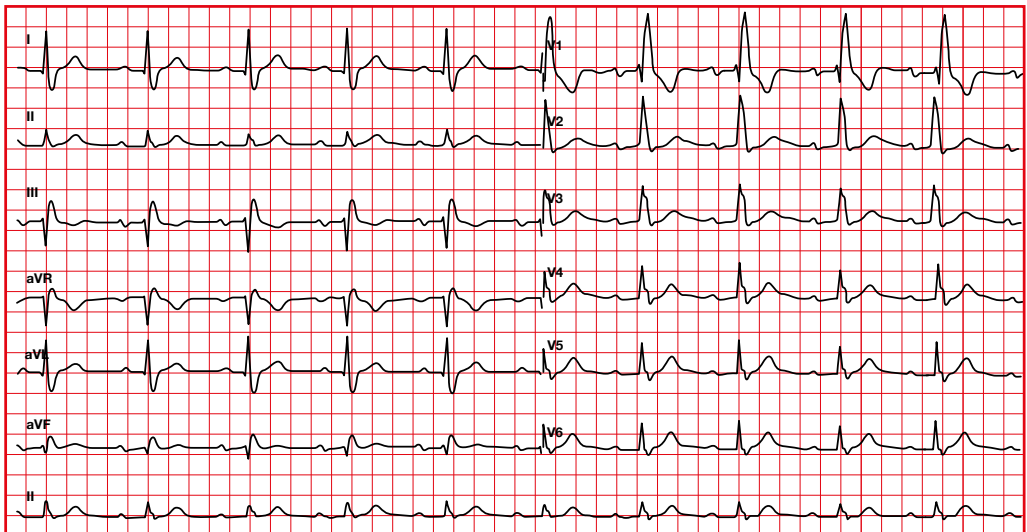
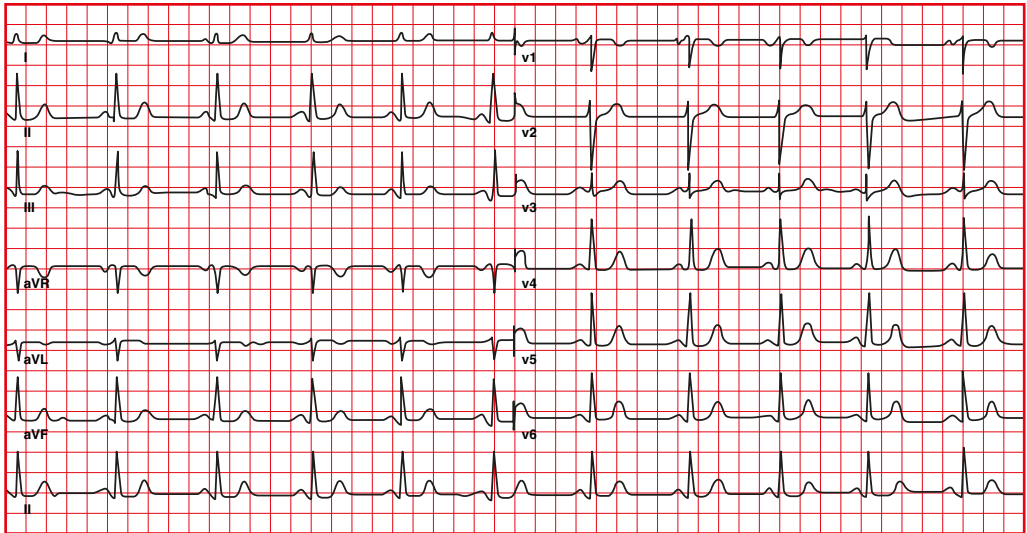
Left ventricular hypertrophy





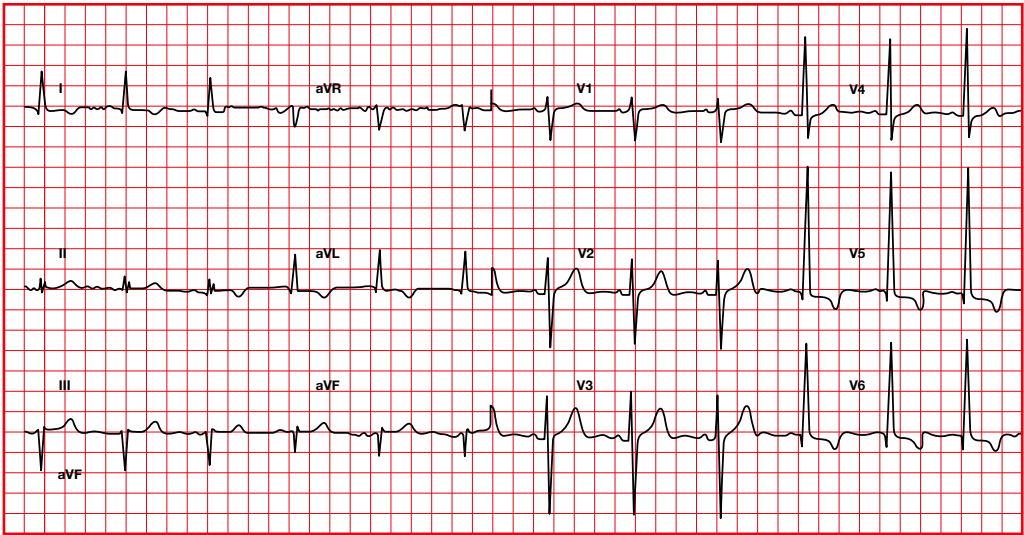
7.18. R wave of the electrocardiogram

In the normal electrocardiogram, the R of the QRS complex becomes more positive from V1 to V5.

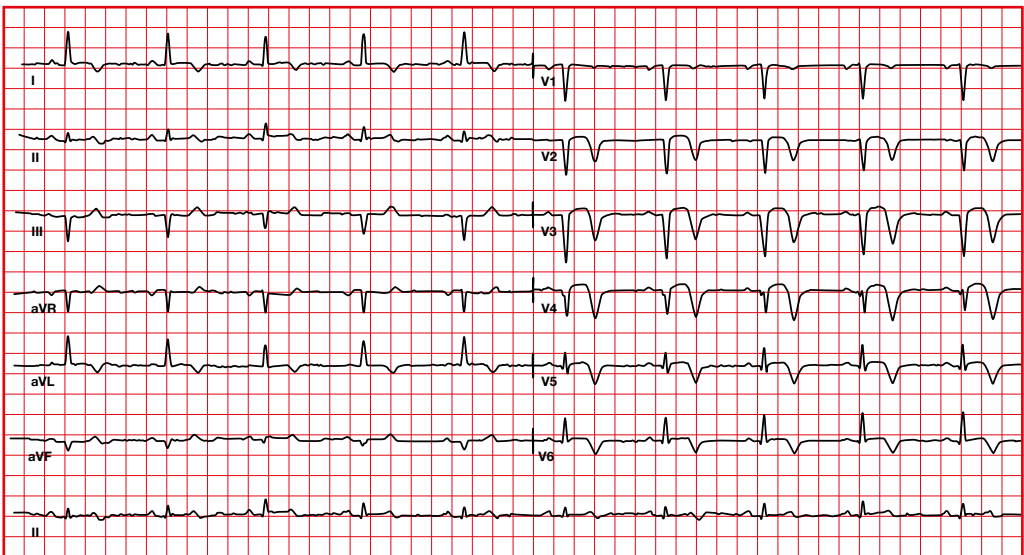


There will be larger R in the right precordials in right ventricular hypertrophy, in posterior infarction and in right bundle branch block.

Systematic assessment of the electrocardiogram



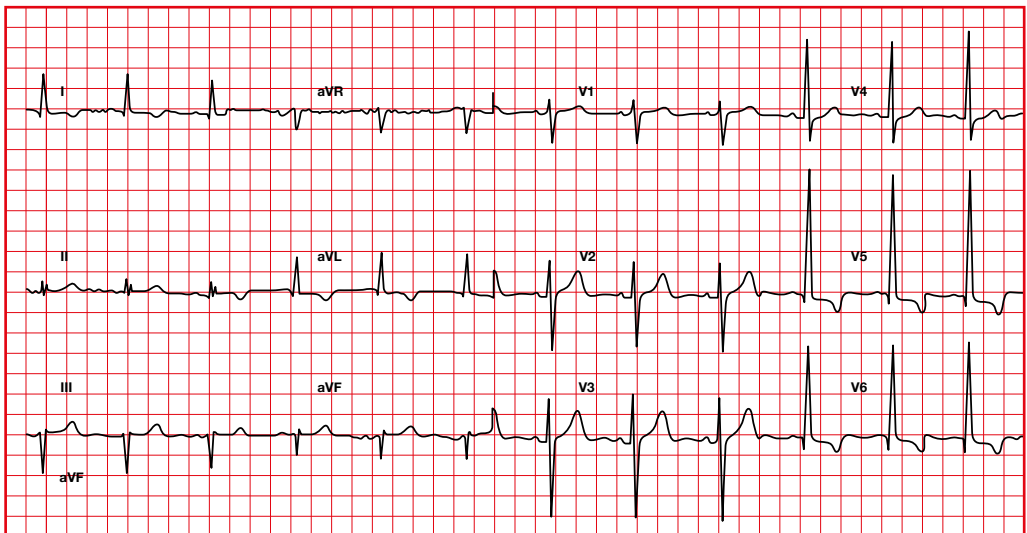
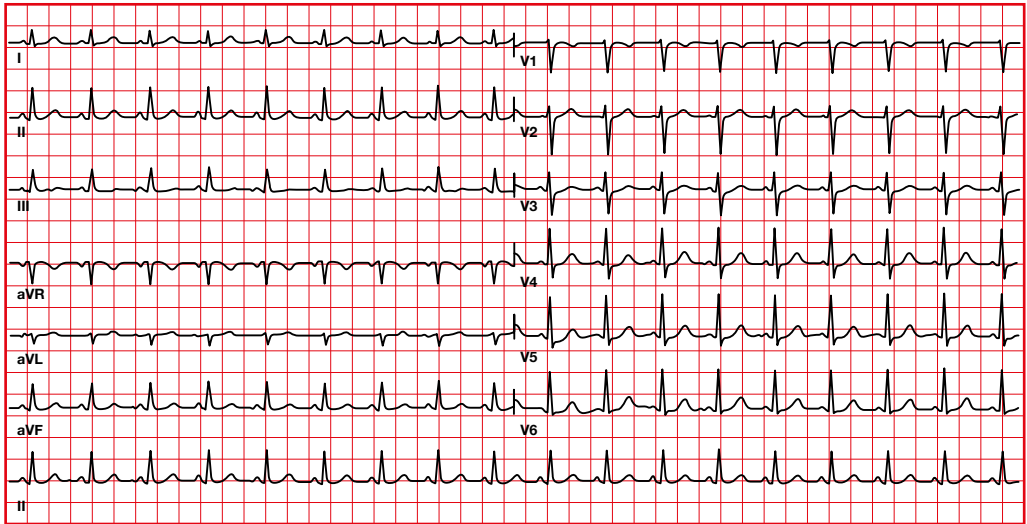
There will be larger R in V5-V6 in left ventricular hypertrophy.



There will be less R in anterior myocardial infarction (loss of anterior forces).

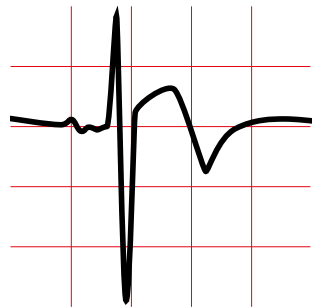
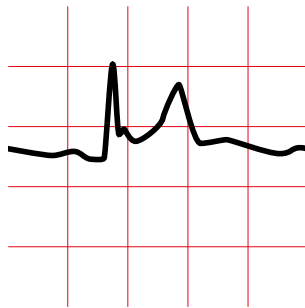
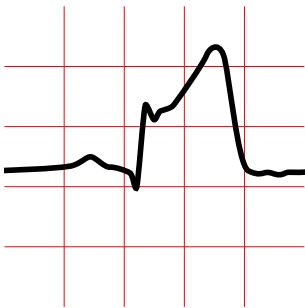
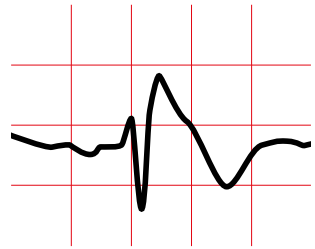
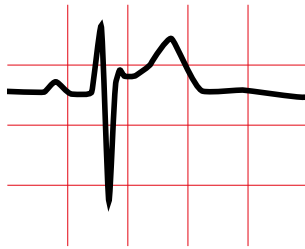
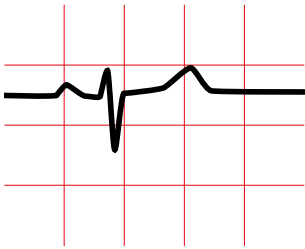
7.19. S wave of the electrocardiogram

- In the normal electrocardiogram, the S of the QRS complex follows a progression according to the axis of the heart.
- In V1 it is usually smaller than in V2, but then it gets smaller until V6.



The progression of the S can be altered by hypertrophy.

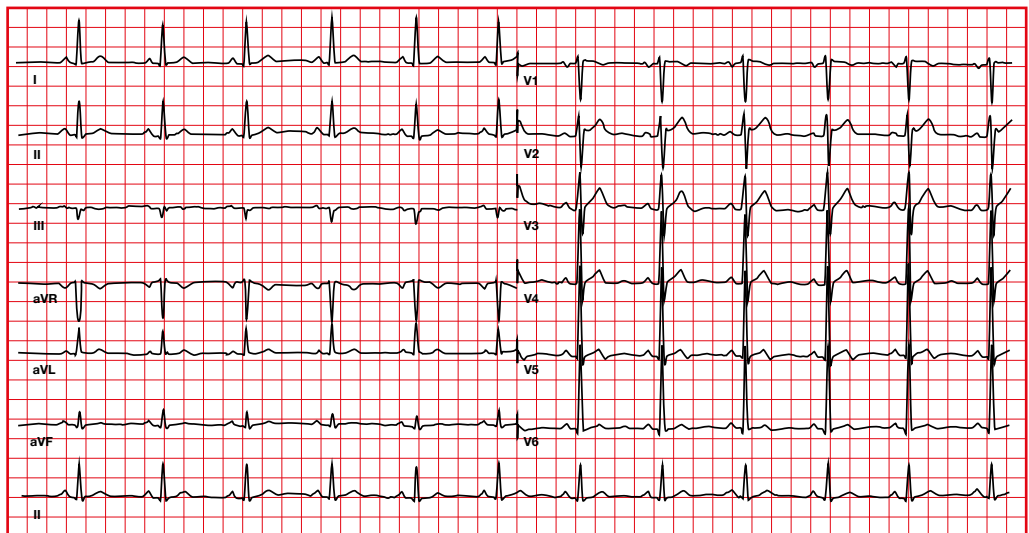
8. J point



8.1. J point abnormalities.

Early repolarization

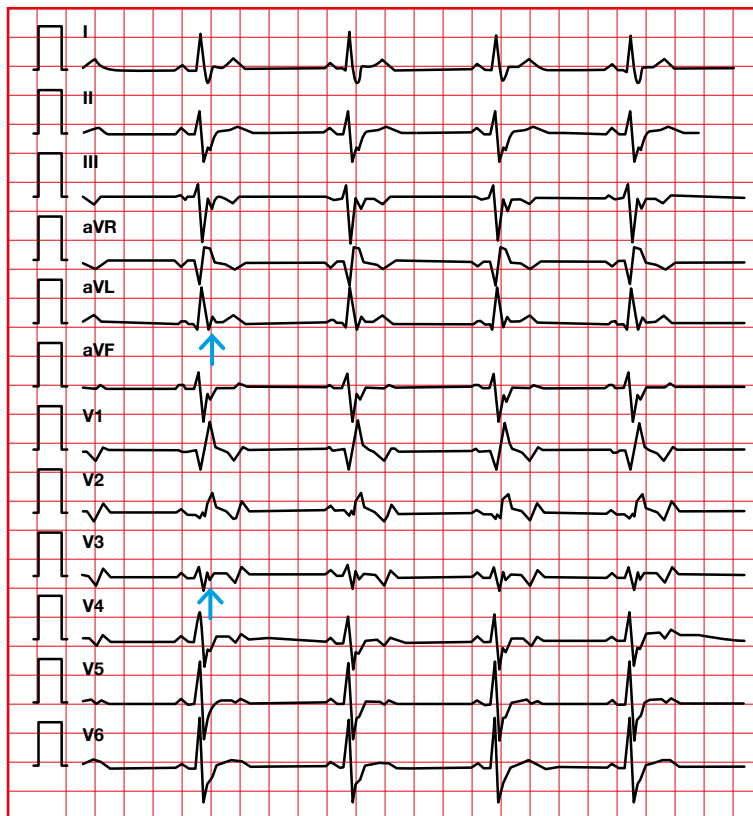
- Normal variant.
- J point elevation.
- ST elevation (concave up) that ends with a symmetrical T wave.
- Notch on the descens of the R wave, usually in V2-V5, sometimes in II, III, aVF.
- Without reciprocal depression of the ST segment.
- Young individuals, athletes and afro-descendants, usually have ST segment elevation, especially in the precordial leads.



8.2. J point abnormalities.

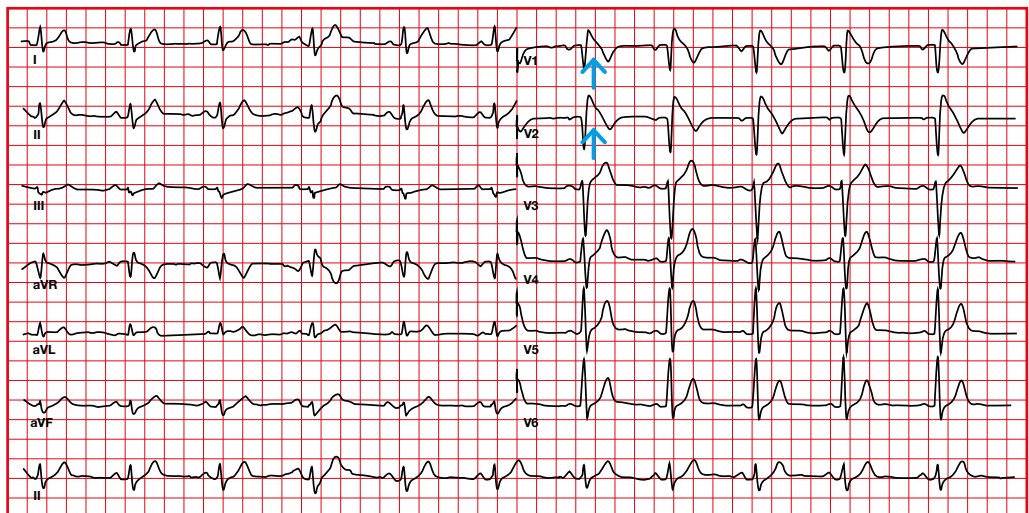
Epsilon wave (arrow)

- The epsilon wave is a marker of delayed activation of the right ventricular free wall.
- It is considered a minor criterion for the diagnosis of arrhythmogenic cardiomyopathy.

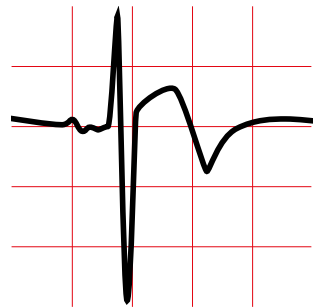
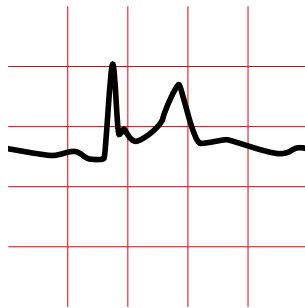
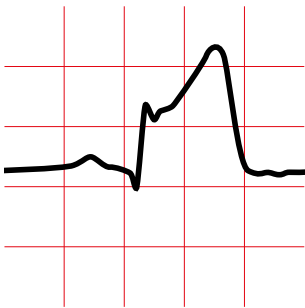
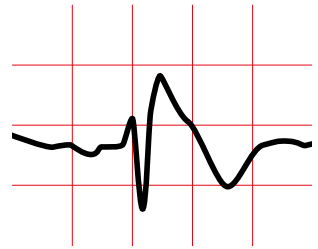
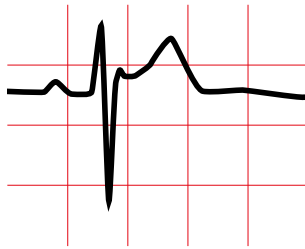
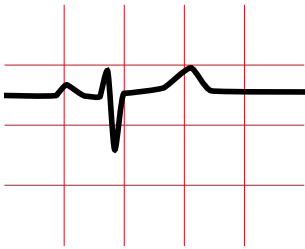


8.3. J point abnormalities. Brugada syndrome

- J point elevation.
- ST segment elevation especially in the right precordial leads (arrow).

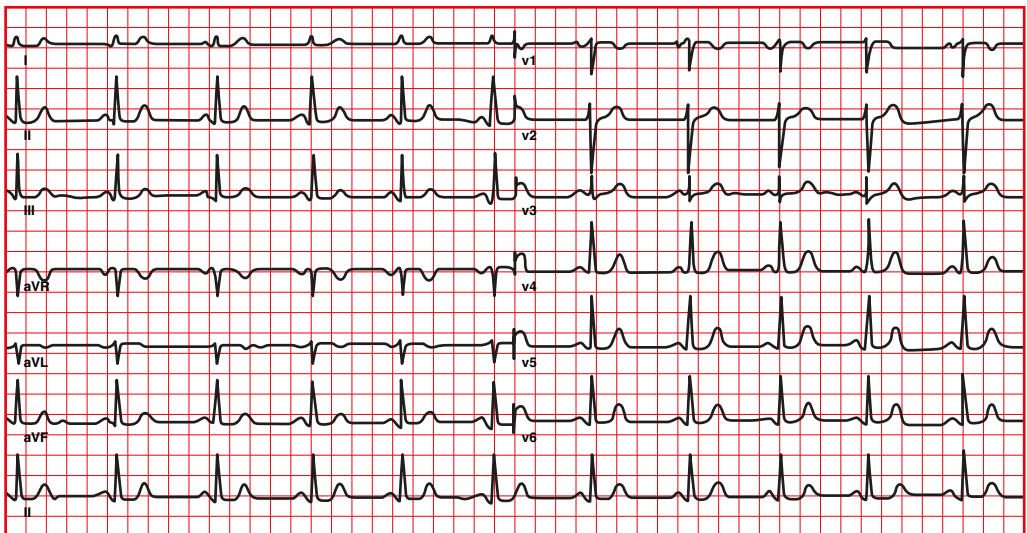


9. ST segment



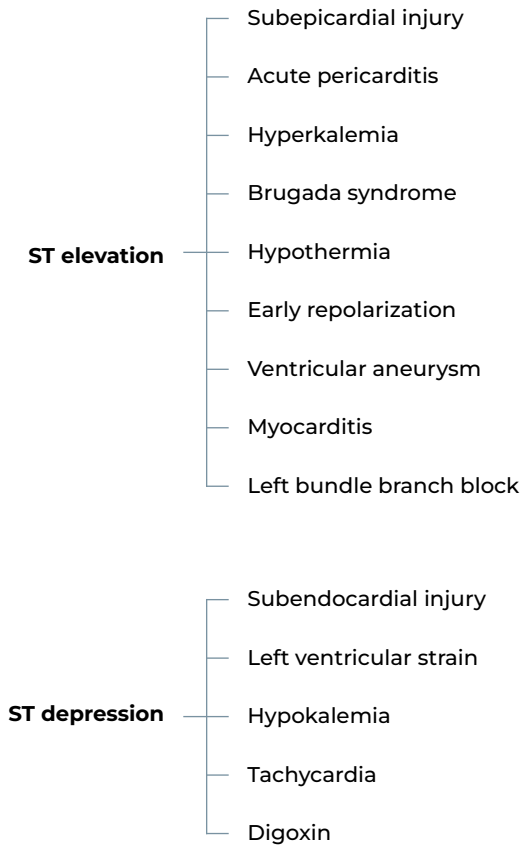
9.1. Normal ST segment

Normally, the ST segment is isoelectric, but can vary from a 0.5 mm depression to a 1 mm elevation in the limb leads, and up to 3 mm elevation (concave above) in the precordial leads (early repolarization).



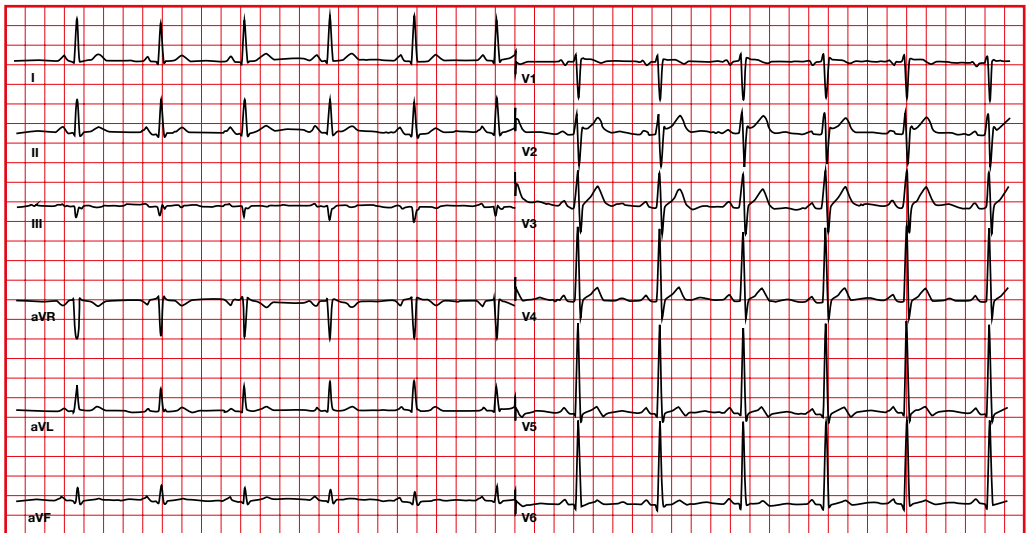
9.2. Differential diagnosis of ST segment abnormalities

Different situations and pathologies can give rise to abnormalities in the ST segment.

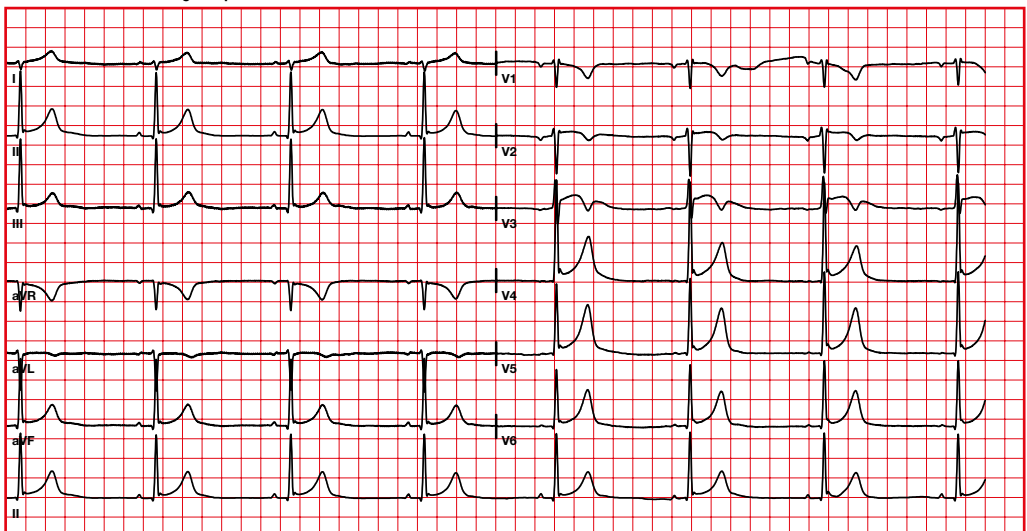


9.3. ST segment abnormalities. ST segment elevation. Early repolariation

Normal variant with ST segment
elevation in the precordial leads.



Athlete with early repolarization



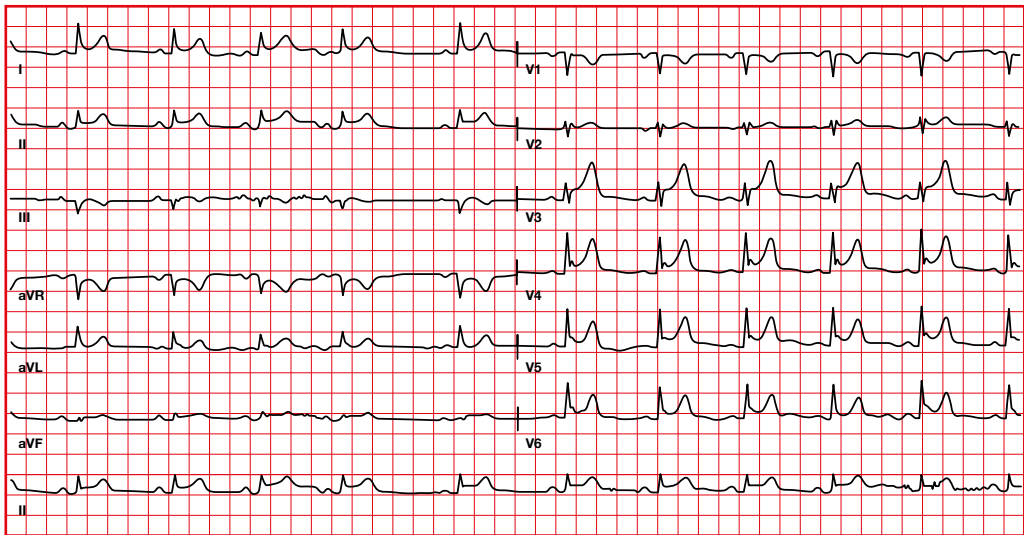
9.4. ST segment abnormalities.

ST segment elevation. Pericarditis

ST elevation (concave up) in all leads except in aVR, without reciprocal ST depression.

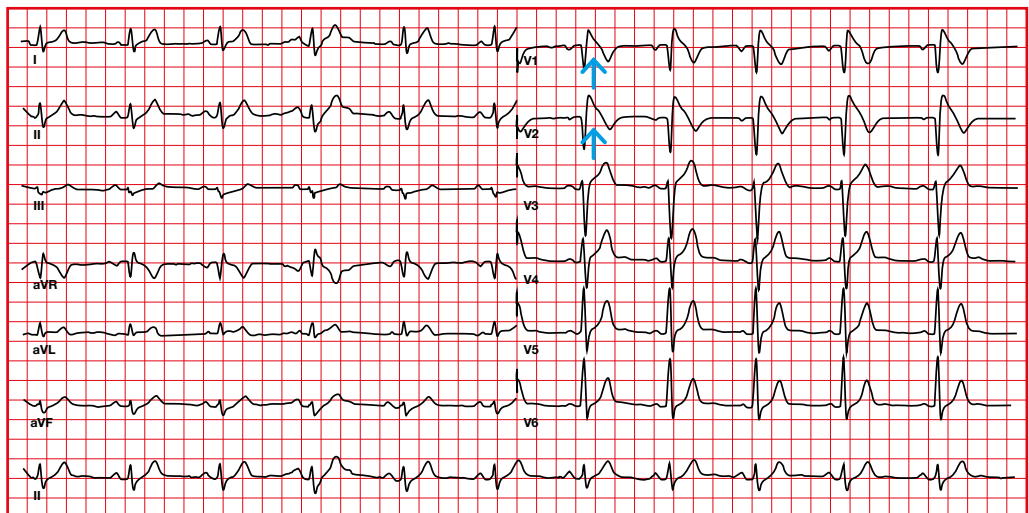
Other changes in pericarditis:

- PR depression (except PR elevation in aVR).



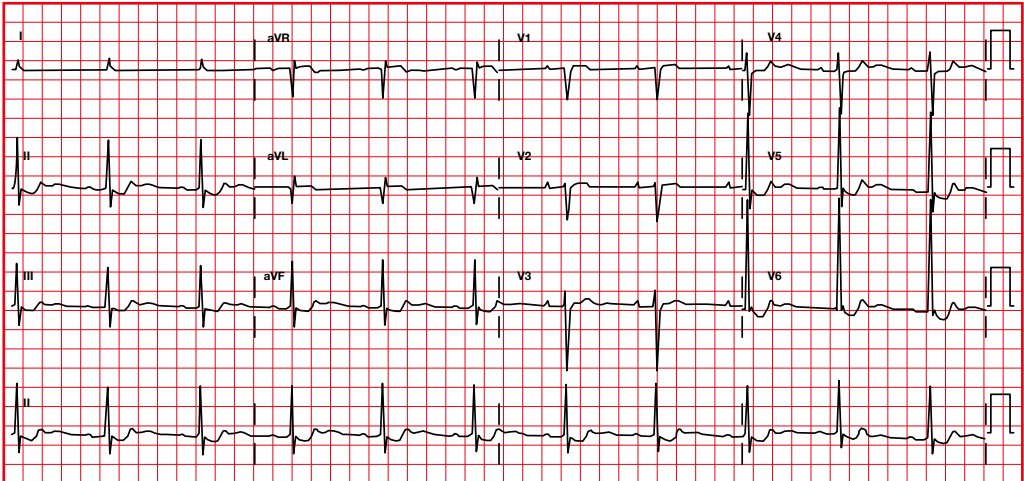
9.5. ST segment abnormalities. ST segment elevation. Brugada syndrome

- J point elevation.
- ST segment elevation in the right precordial leads.



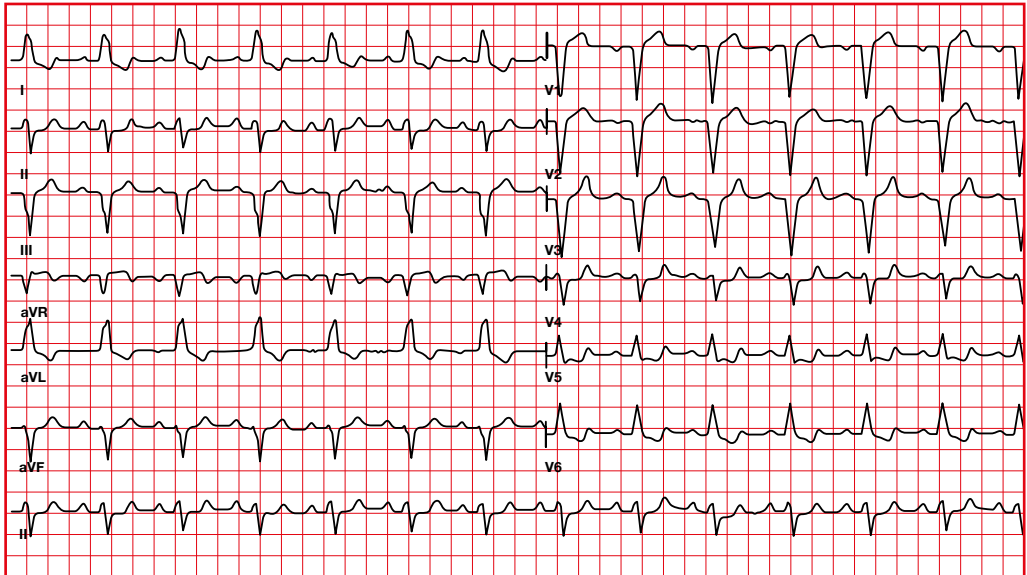
9.6. ST segment abnormalities. ST segment depression

Downsloping ST depression in patients taking digoxin (Salvador Dalí sagging).

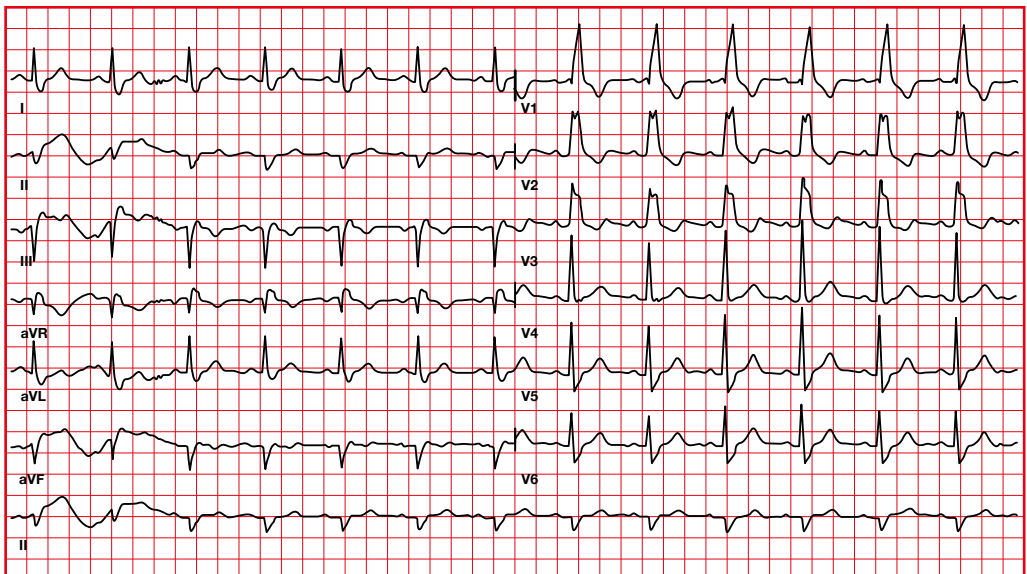


9.7. ST segment abnormalities. Bundle branch blocks

We will observe ST segment abnormalities in bundle branch blocks.



Left bundle branch block. ST depression and T inversion in the left precordial leads, ST segment elevation and positive T wave in the right precordial leads.

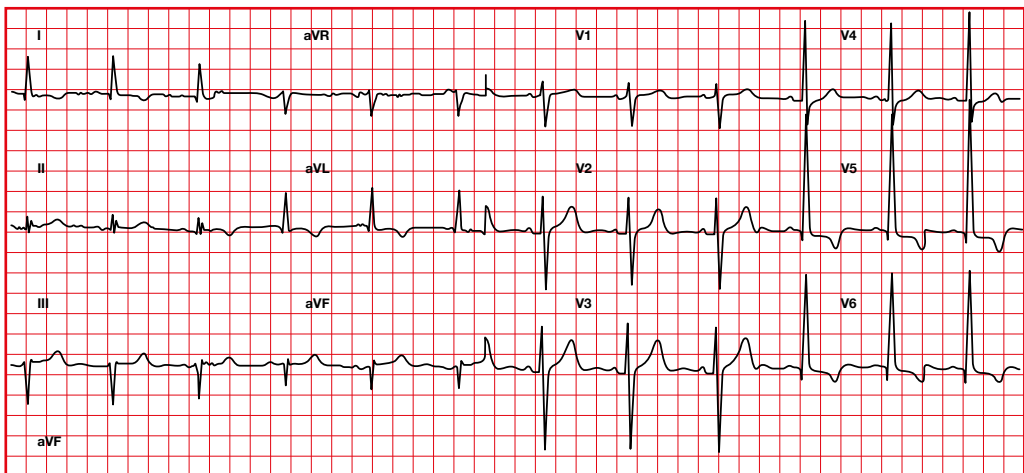


Right bundle branch block. ST depression and T inversion in the right precordial leads.

9.8. ST segment abnormalities.

Ventricular hypertrophy

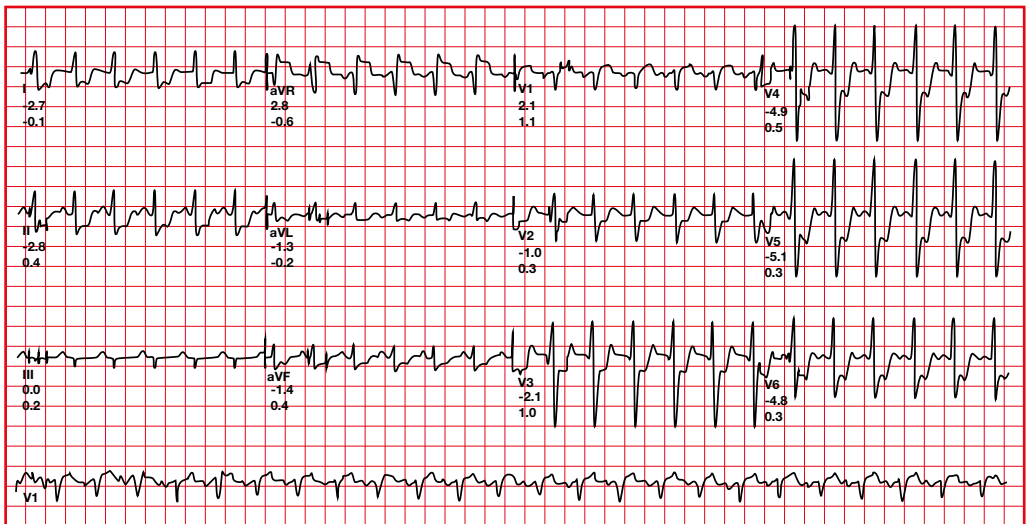
- Changes in the right ventricle will be observed in V1, V2.
- Changes in the left ventricle will be observed in I, aVL, V5, V6.
- We will find abnormalities in the ST segment and in the T wave.
- The ST and T will be deviated in direction opposite to QRS. We will see ST depression in I, aVL, V4-V6.



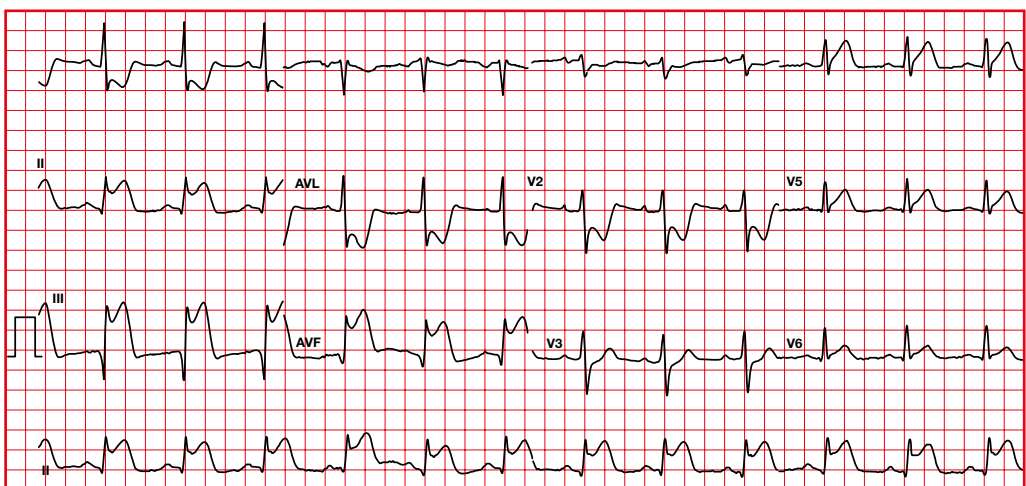
9.9. ST segment abnormalities. ST changes suggesting injury

ST segment depression (subendocardial injury) or ST segment elevation (subepicardial injury) with or without T wave inversion.

Reciprocal or mirror image will be observed on the opposite wall.

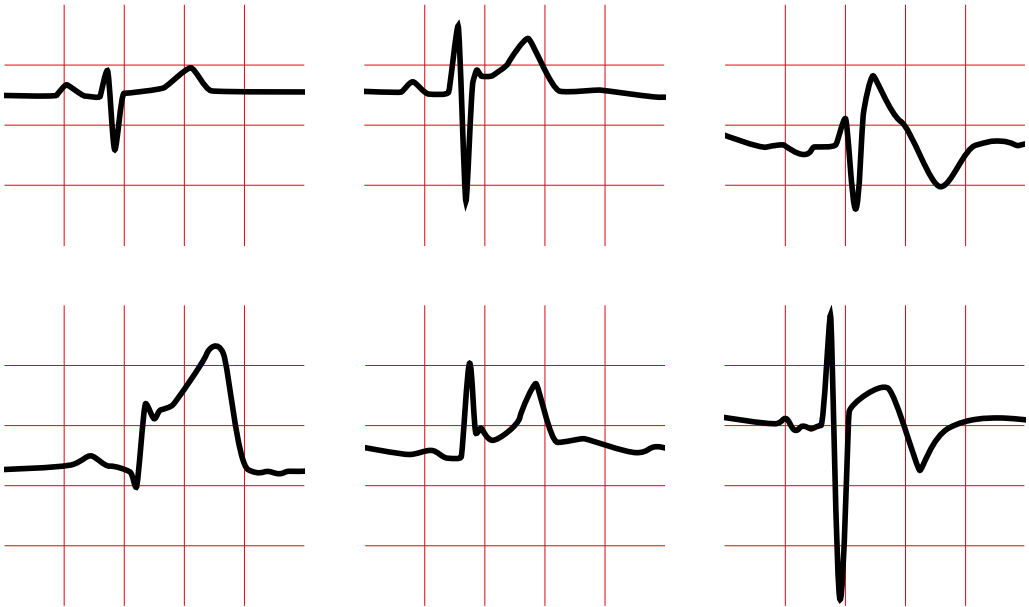


Decreased ST segment during a stress test.



Q waves with ST segment elevation in II, III, aVF, with ST segment depression in V1, V2, I, aVL (reciprocal image). Acute inferoposterior infarction.

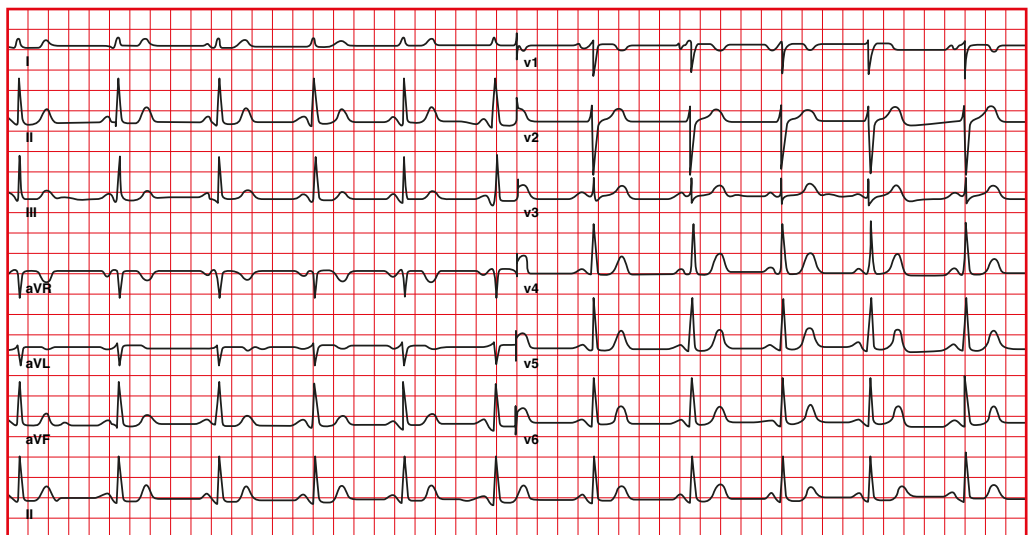
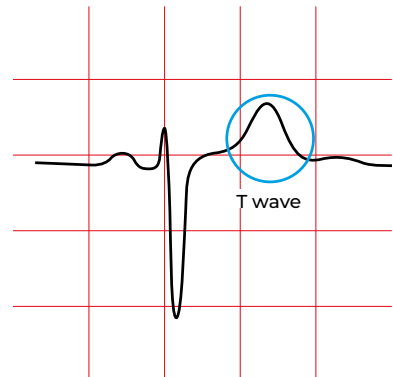
10. T wave



10.1. Normal T wave

On the ECG, the T wave represents ventricular repolarization.

- Positive in I, II, V4-V6.
- Inverted in aVR, sometimes in V1.
- It may be negative in V1-V3 in young people (V1 to V4 in black ethnicity).
- Amplitude < 6 mm in bipolar leads, < 10 mm in precordial leads.

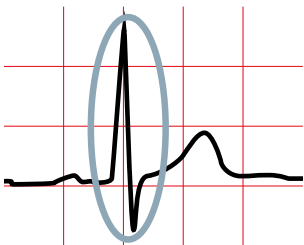
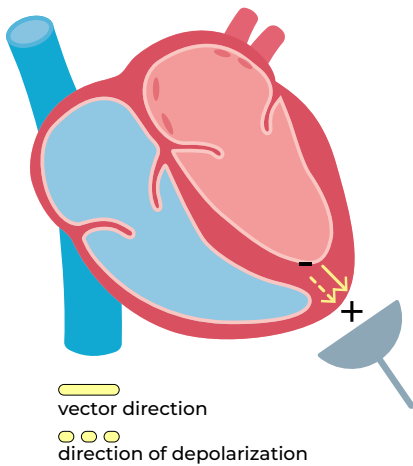


Repolarization should result in a wave opposite to the direction of the QRS complex.

Why does it follow the QRS direction?

10.2. Depolarization in the heart

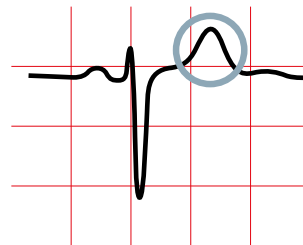
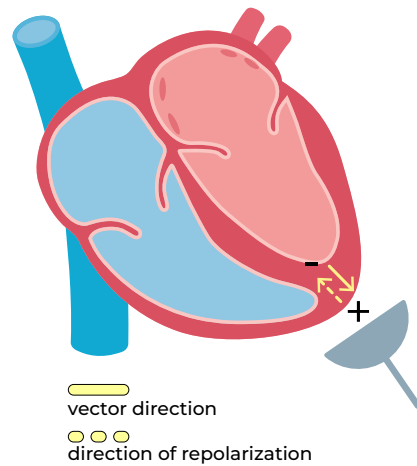
Depolarization advances from endocardium to epicardium. When depolarization moves toward the positive electrode, it results in a positive wave on the electrocardiogram.



10.3. Repolarization in the heart

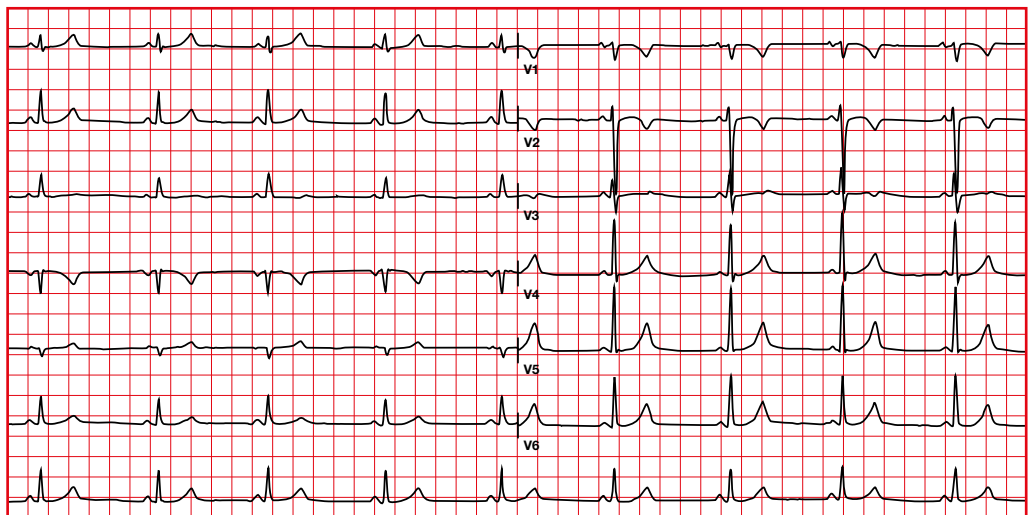
A repolarization wave should generate a complex in the opposite direction to the QRS because the part that depolarizes first should also repolarize first.

However, due to transient physiological ischemia of the endocardium, the repolarization wave travels from epicardium to endocardium, causing a wave in the same direction as the QRS complex.



10.4. Normal T wave variation. Juvenile T waves

- They are usually seen in young males.
- There will be persistent negative T waves (not symmetrical and not deep) in leads V1-V3 (up to V4 in black ethnicity).



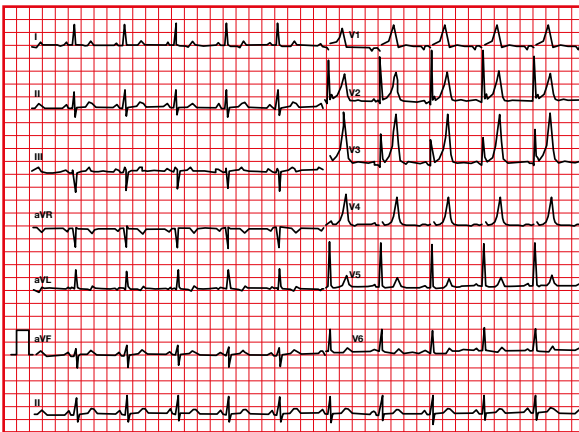
10.5. T wave abnormalities

Peaked or hyperacute T wave

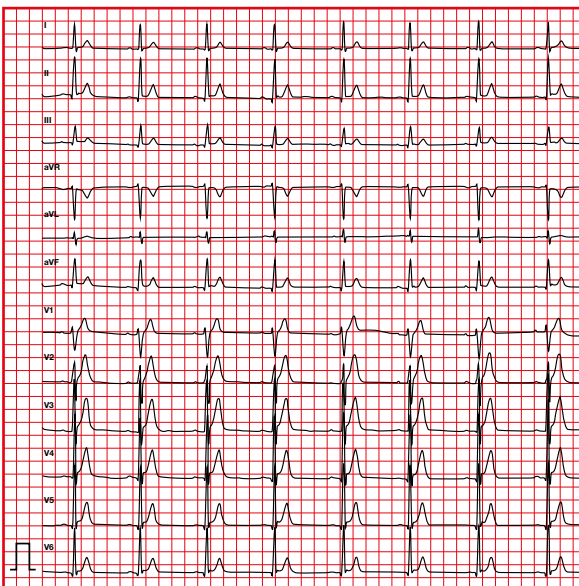
- > 6 mm in limb leads.
- > 10 mm in precordial leads.

Differential diagnosis

- Normal variant (vagotonic T waves).
- Myocardial infarction.
- Long QT syndrome.
- Short QT syndrome.
- Hyperkalemia.
- Left ventricular hypertrophy.



Hyperkalemia

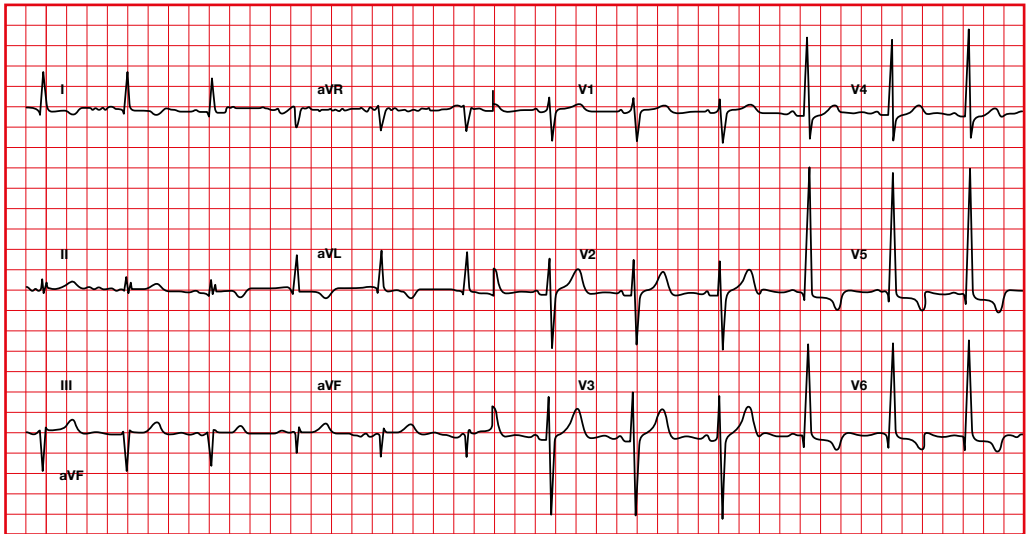


Short QT

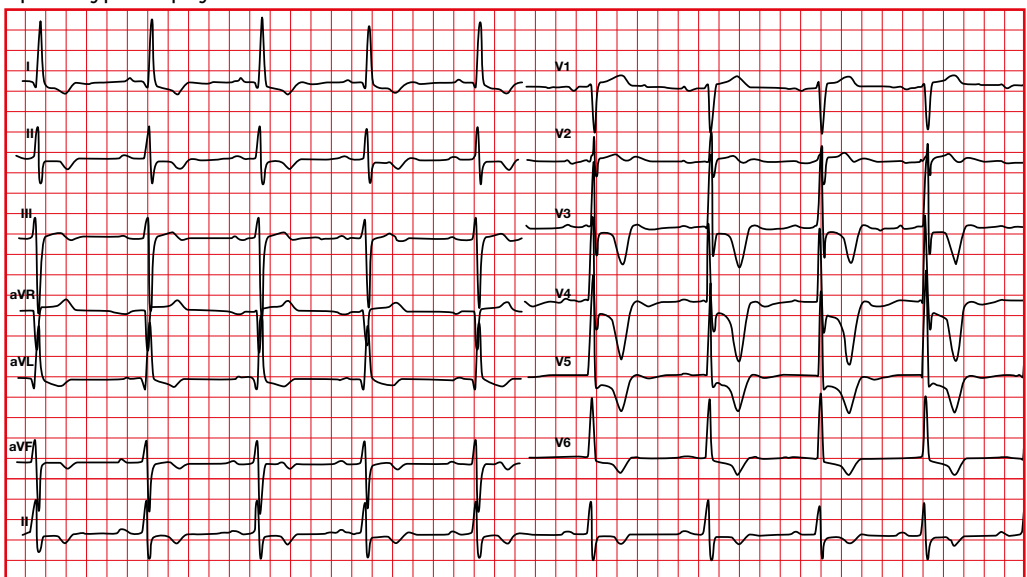
Negative T waves

- Negative T waves can be seen in ventricular hypertrophy.
- In apical ventricular hypertrophy T waves are usually negative and symmetrical in the lateral leads.

Hypertrophy (strain)



Apical hypertrophy



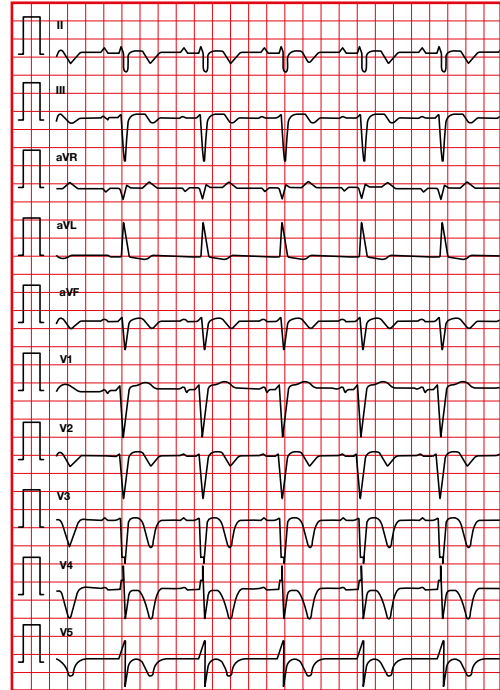
Tako-Tsubo syndrome

Negative T waves are usually seen in the lateral precordial leads.

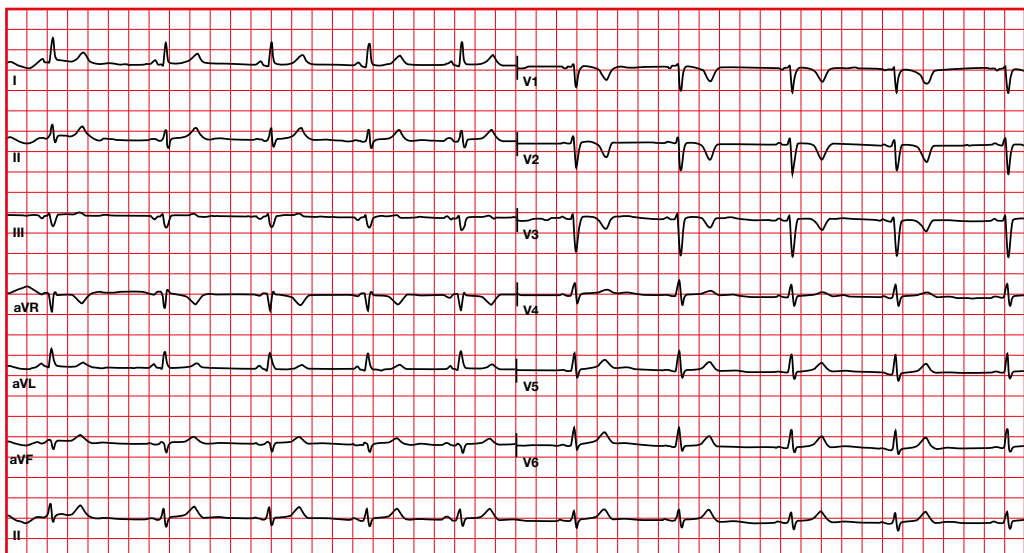
Arrhythmogenic cardiomyopathy

- Inversion of T waves can be observed in the right precordial leads (V1-V3).
- If the inversion is present beyond the right precordial leads, there is probably a more extensive involvement of the disease, even affecting the left ventricle.

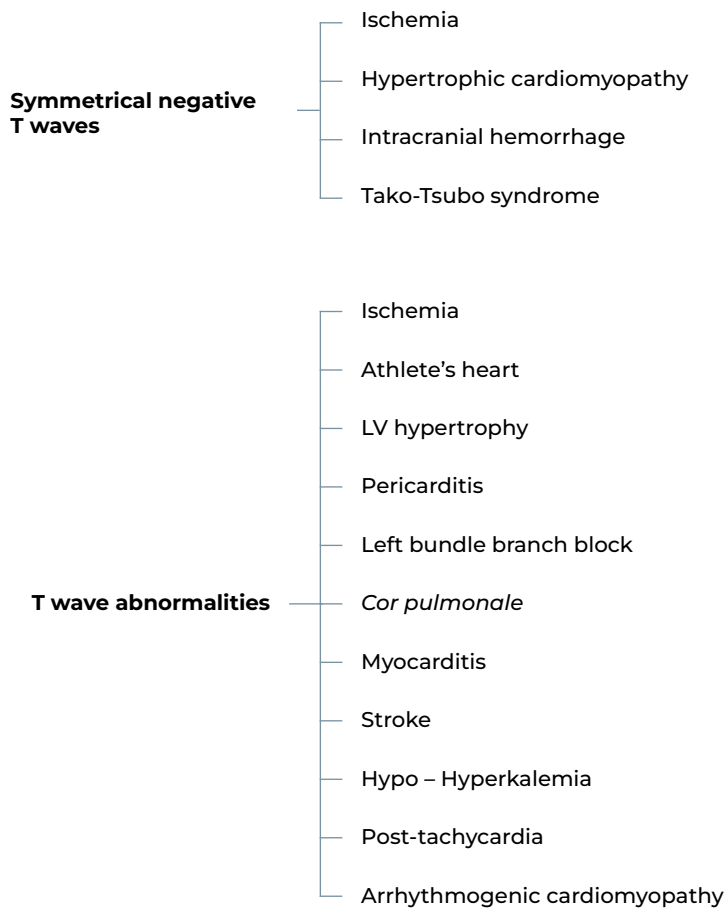
Tako-Tsubo syndrome



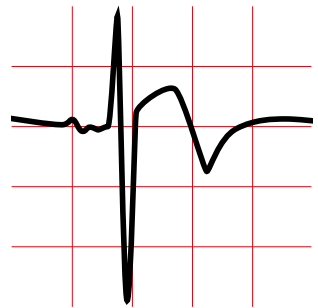
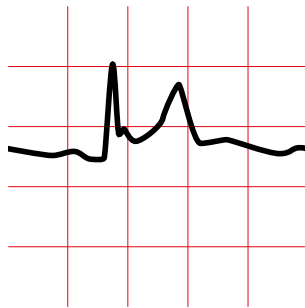
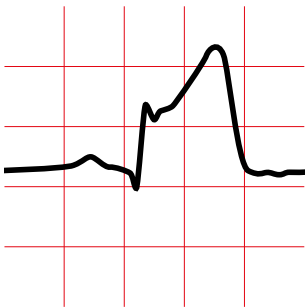
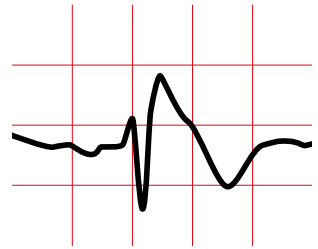
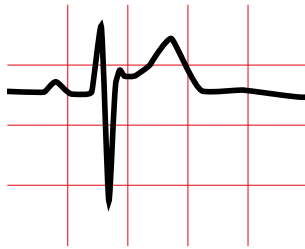
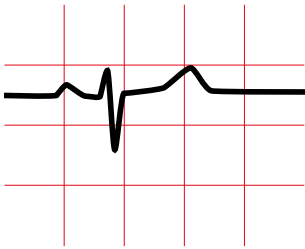
Arrhythmogenic cardiomyopathy



Differential diagnosis

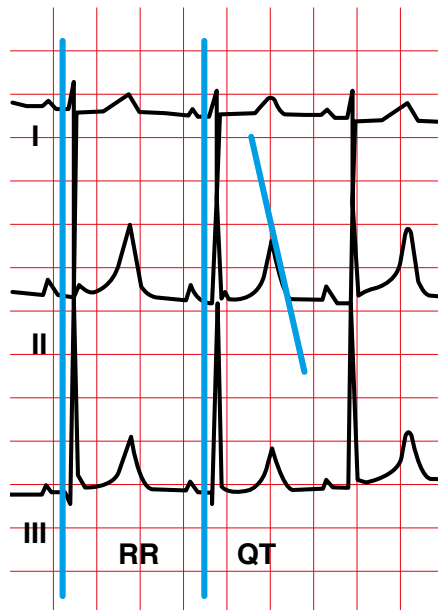


11. QT interval



11.1. QT Interval measurement

- The QT interval varies inversely with heart rate. For this reason, it must be corrected according to HR (corrected QT or QTc).
- Measure the longest QT interval in several leads.
- There are several formulas for calculating the QT interval.



Formulas for calculating QT

Bazett	QT/\sqrt{RR}
Fridericia	$QT/3\sqrt{RR}$
Framingham	$QT + 0.154 \times (1-RR)$
Hodges	$QT + 1.75 \times (HR-60)$

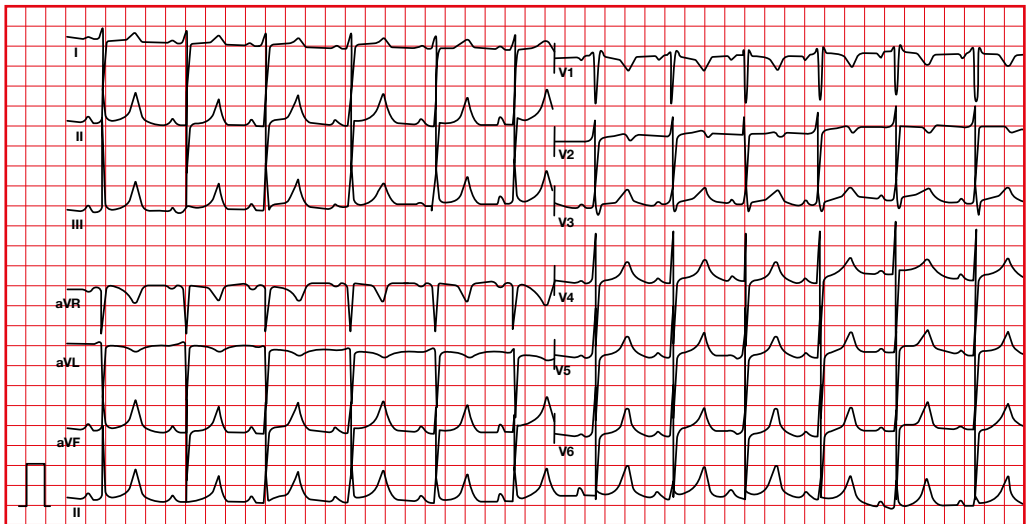
11.2. QT interval abnormalities.

Long QT syndrome

The long QT syndrome is an inherited disease associated with sudden death in young people.

There are two inherited forms of long QT syndrome:

- Autosomal dominant (Romano-Ward syndrome).
- Autosomal recessive (Jervell and Lange Nielsen syndrome).



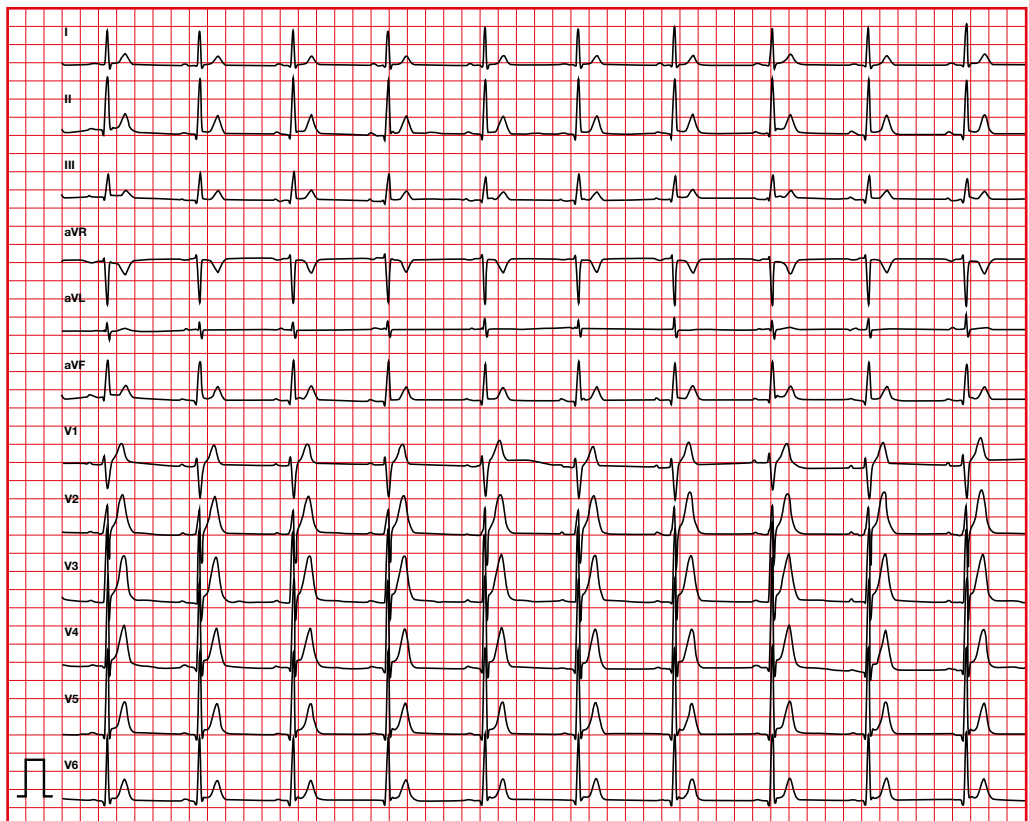
Value	1-15 years	Adult male	Adult female
Normal	< 440 ms	< 430 ms	< 450 ms
Borderline	440-460 ms	430-450 ms	450-460 ms
Long	> 460 ms	> 450 ms	> 460 ms

11.3. QT interval abnormalities. Short QT syndrome

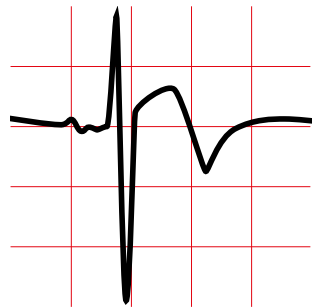
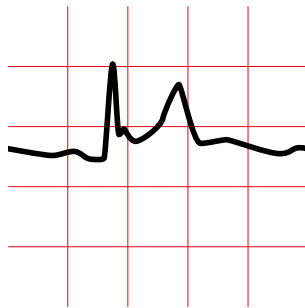
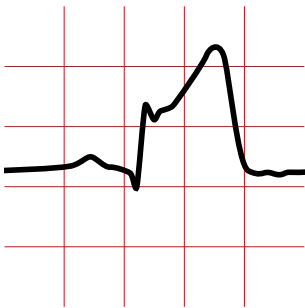
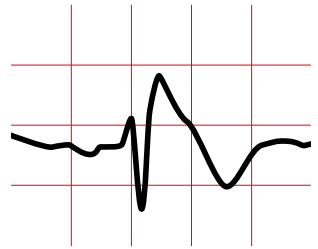
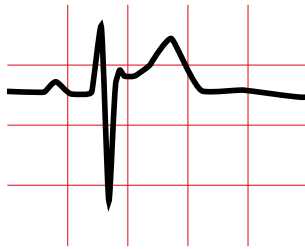
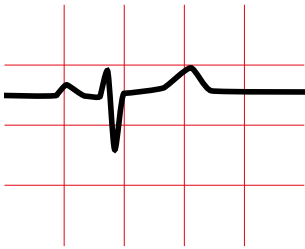
The short QT syndrome is a very rare inherited disease associated with sudden death in young people.

Short QT syndrome is diagnosed:

- in an asymptomatic patient with a $QTc \leq 340$ ms or
- in a patient with symptoms with a $QTc < 360$ ms.



12. U wave



12.1. U-wave abnormalities

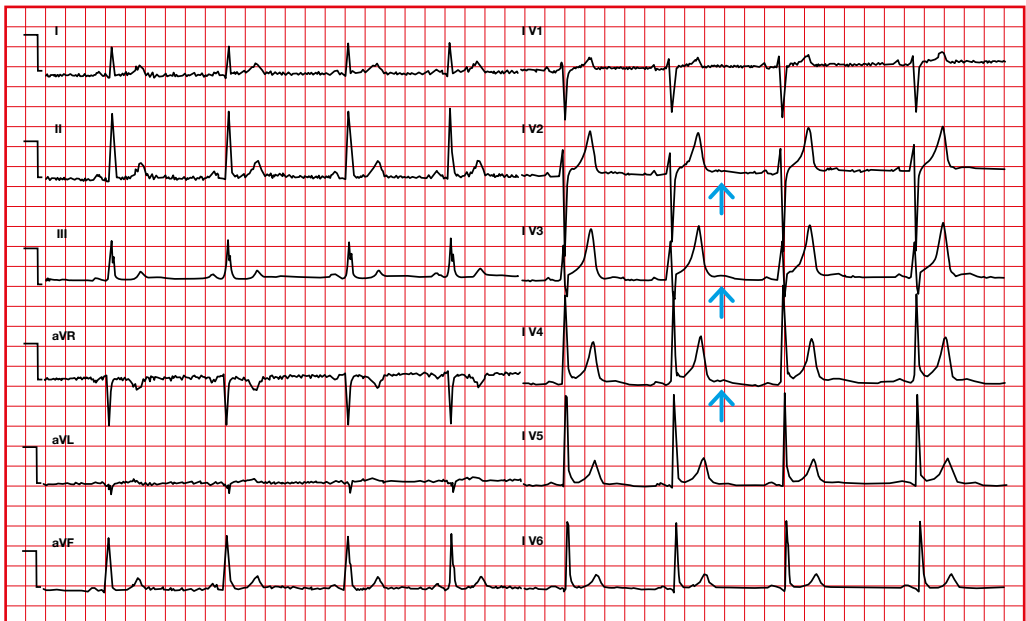
- Width ≥ 1.5 mm.
- Typically 5-25% of the height of the T wave.
- It is highest in V2 and V3.

Causes of augmented U waves

- Hypokalemia.
- Bradyarrhythmias.
- Hypothermia.
- Left ventricular hypertrophy.
- Drugs (digitalis, quinidine, amiodarone, isoproterenol).

Causes of inverted U waves

- Hypertension.
- Coronary artery disease.
- Congenital heart disease.
- Cardiomyopathy.



ISCHEMIA / INJURY / NECROSIS |

1. Definition

Ischemia:


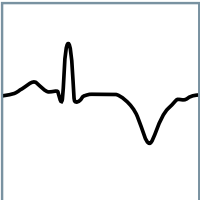
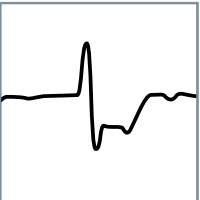

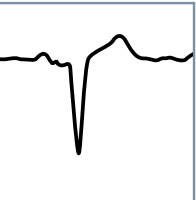
- Reversible process.
- T wave abnormalities.

Injury (more severe ischemia):

- Reversible process.
- ST segment abnormalities.

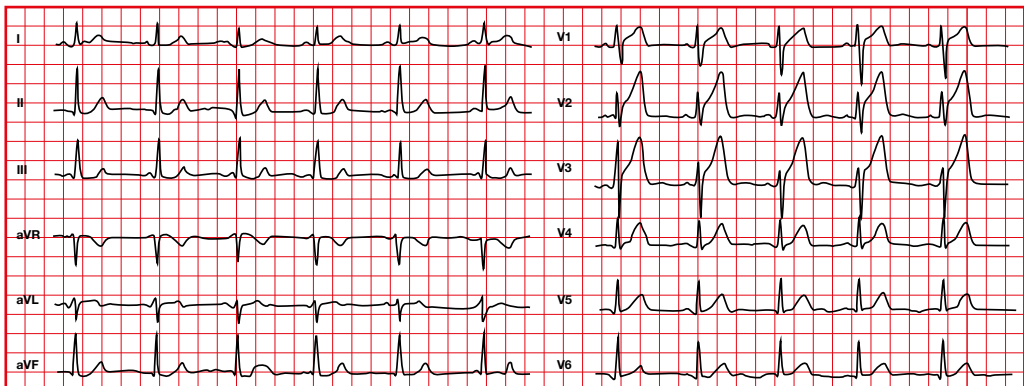
Necrosis:

- Tissue is lost in the affected area.
- Irreversible process.
- Appearance of Q waves.

				
Subendocardial ischemia	Subepicardial ischemia	Subendocardial injury	Subepicardial injury	Transmural necrosis
Open artery	Open artery	Open artery	Blocked artery	Open/blocked artery
No cell death	No cell death	Cell death +	Cell death ++	Death established

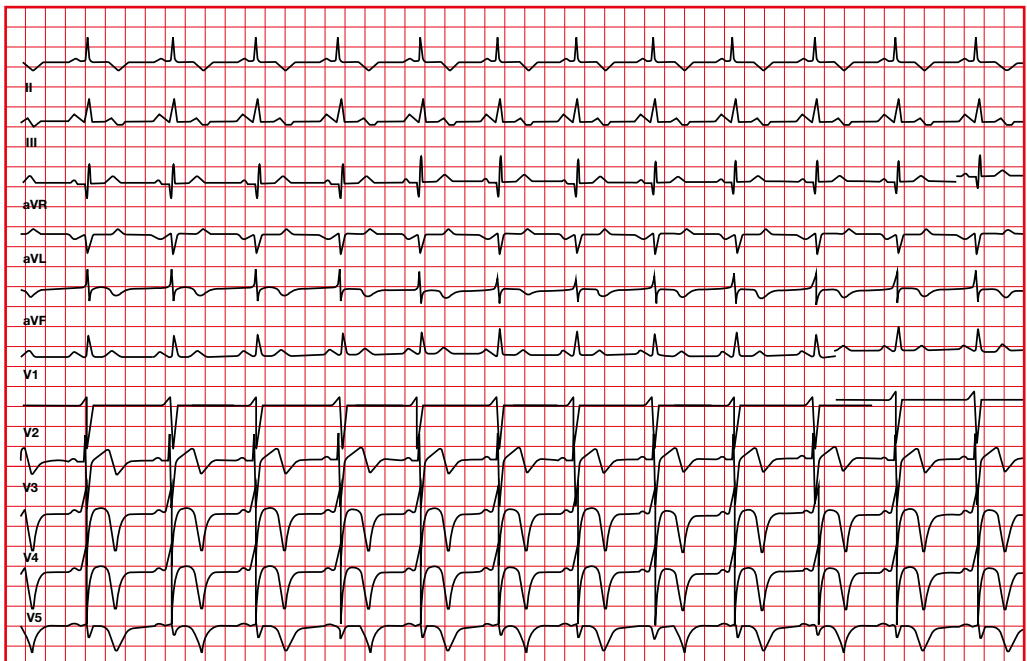
2. Subendocardial ischemia

- There is a delay in ventricular repolarization of the endocardial area.
- Normal repolarization begins in the epicardium (due to physiological endocardial ischemia). The process continues in the same direction but its duration is longer. Normal T waves are therefore amplified.
- Peaked or hyperacute T waves and transient QT prolongation. It precedes the appearance of ST segment elevation.



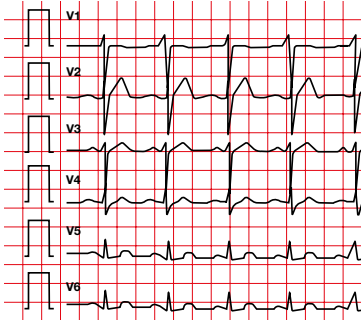
3. Subepicardial or transmural ischemia

- The repolarization vector is reversed and advances from endocardium to epicardium.
- Flattened or negative symmetrical T waves.

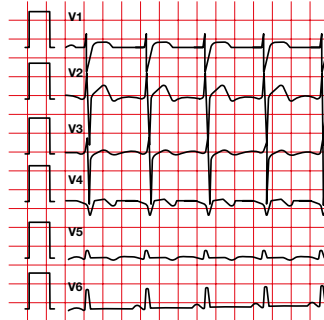


Ischemia is a reversible phenomenon. T wave abnormalities can be reversed over time.

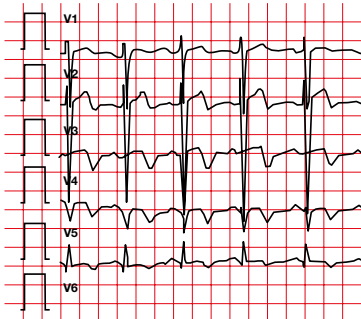
2018 13/01 22:00



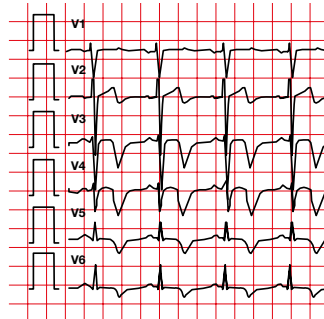
14/01 00:00



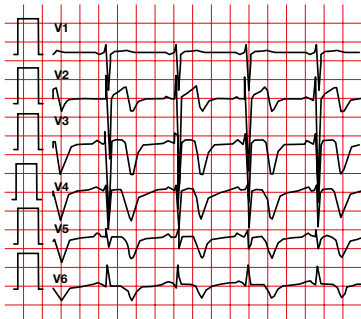
14/01 11:00



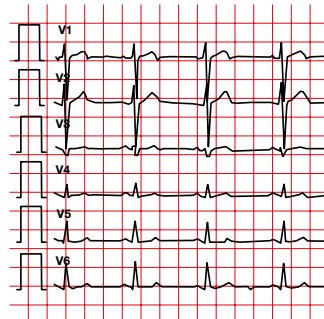
15/01 07:00



15/01 12:00



2019

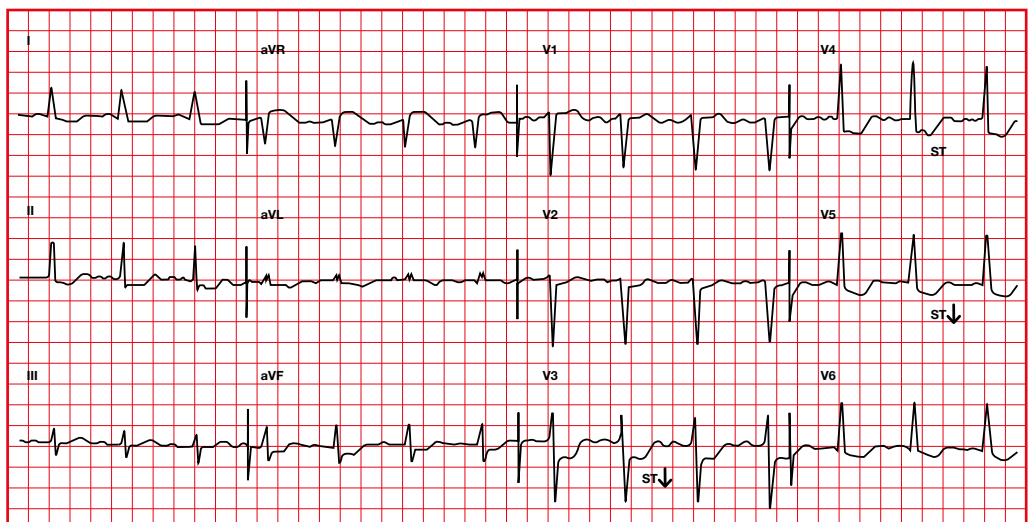
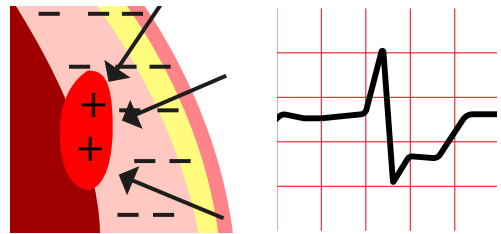


4. Subendocardial injury

4.1. ST depression

At the end of depolarization there still remain positive charges in the endocardium because it depolarizes more slowly. The vector forces will be directed away from the epicardium; **negative ST segment**.

Suggestive with ST depression ≥ 0.5 mm at the J point and it is horizontal or descending for at least 80 ms in 2 contiguous leads.

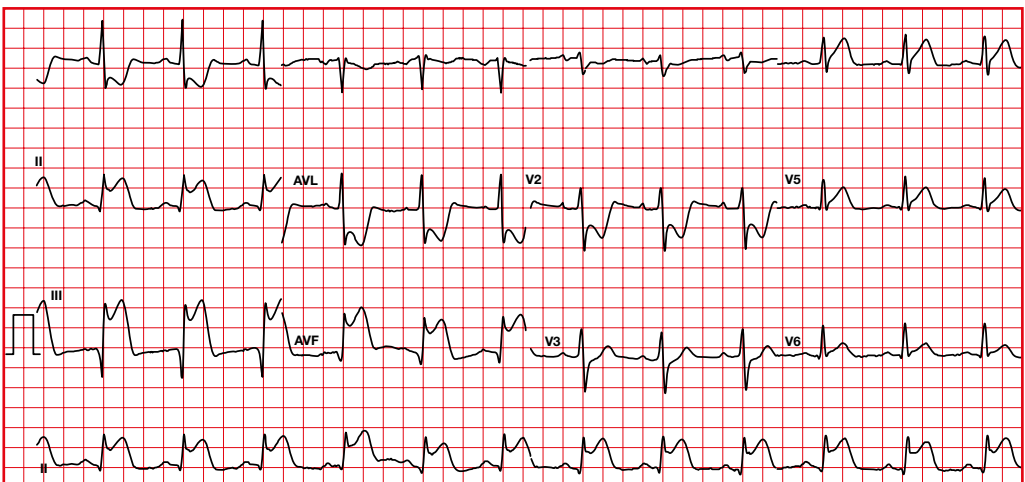
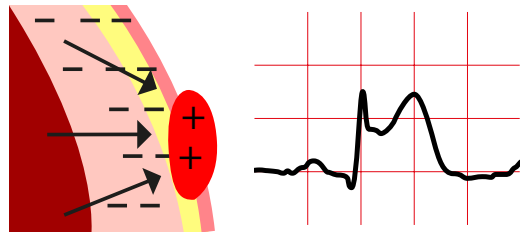


5. Subepicardial or transmural injury

At the end of depolarization, there are positive charges in the epicardium, so the vector forces will be directed towards the epicardium; **positive ST segment**.

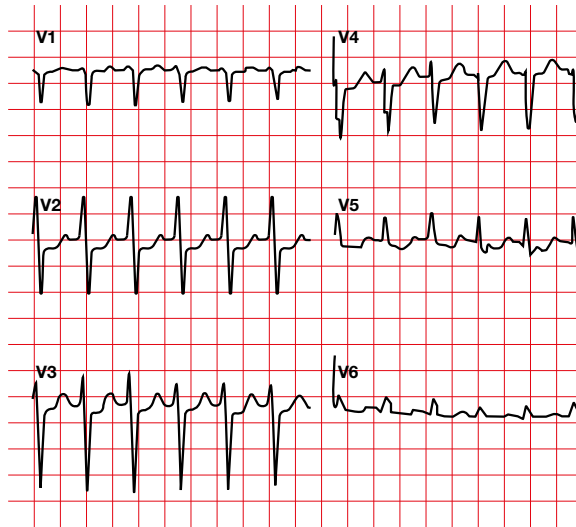
If it affects the posterior wall, ST segment depression can be observed in the right precordial leads.

- ST segment elevation at J point:
 - ≥ 1 mm in two or more limb leads.
 - ≥ 2 mm in two or more precordial leads.

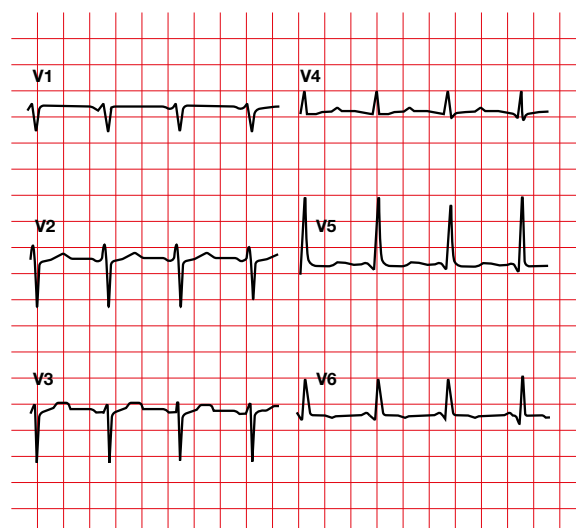


The injury is a reversible phenomenon.
In this ECG, ST segment depression can be observed in the anterior precordial leads.

8:00

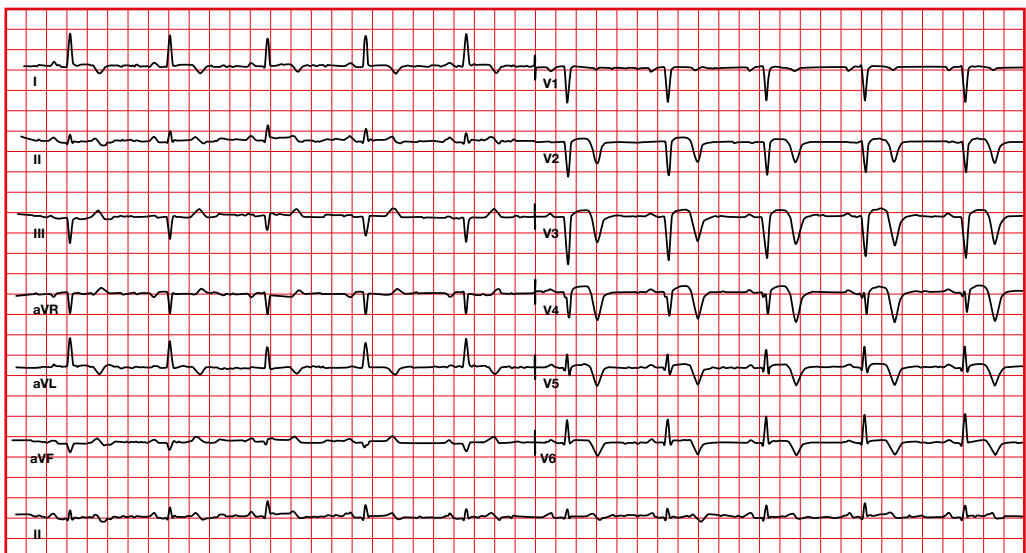
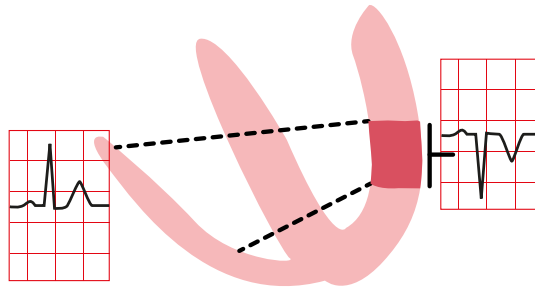


8:30

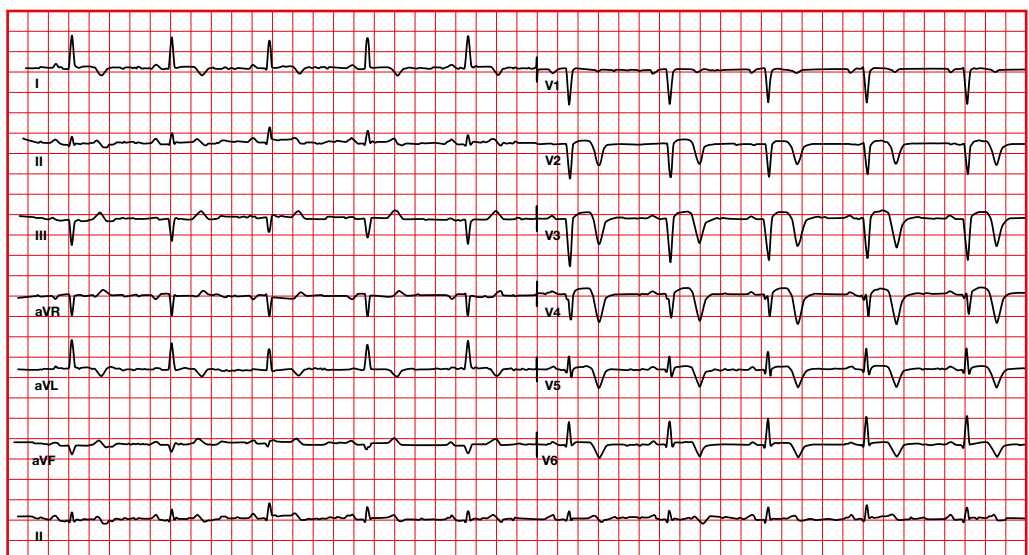


6. Infarction or necrosis

- A necrotic area does not have any electrical activity. The depolarization forces are lost.
- The directing vector necessarily moves away from this area.
- Appearance of the Q wave.
- The necrosis begins in the most subendocardial area.

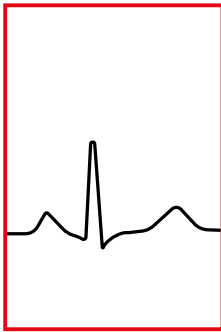


- Qs are significant if they have a duration > 0.04 s and are deep ($> 25\%$ of the R wave).
- Q in aVR is never significant when assessing infarction.
- A small q can be seen in I, aVL, V5 and V6. Sometimes it can be seen in the inferior leads and in V3, V4 (always smaller than 0.1 mV).
- The ST segment elevation is convex upwards. It can persist from 48 hours to 4 weeks (beyond 4 weeks you have to think about aneurysm).
- T-wave inversion may remain indefinitely.

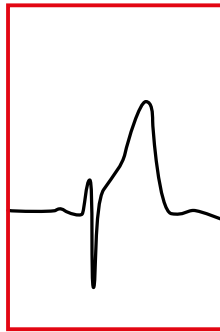


7. Progression of acute myocardial infarction

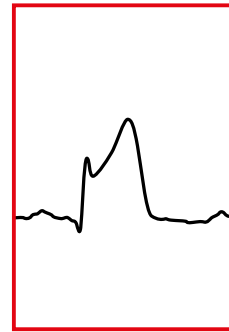
- Ischemia –injury– necrosis is a dynamic process, so the changes occur gradually.
- A normal ECG does not rule out a myocardial infarction.



Normal



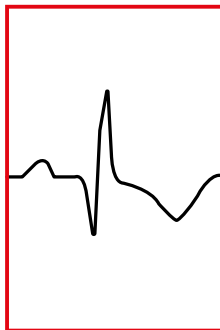
**Hyperacute
T wave**
Minutes/hours



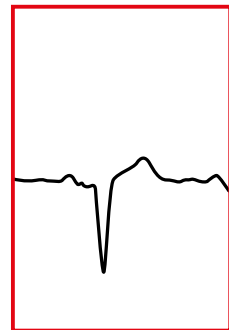
ST Elevation
0-12 hours



**Q wave
development**
1-12 hours



**ST Elevation with
T wave inversion**
2-5 days



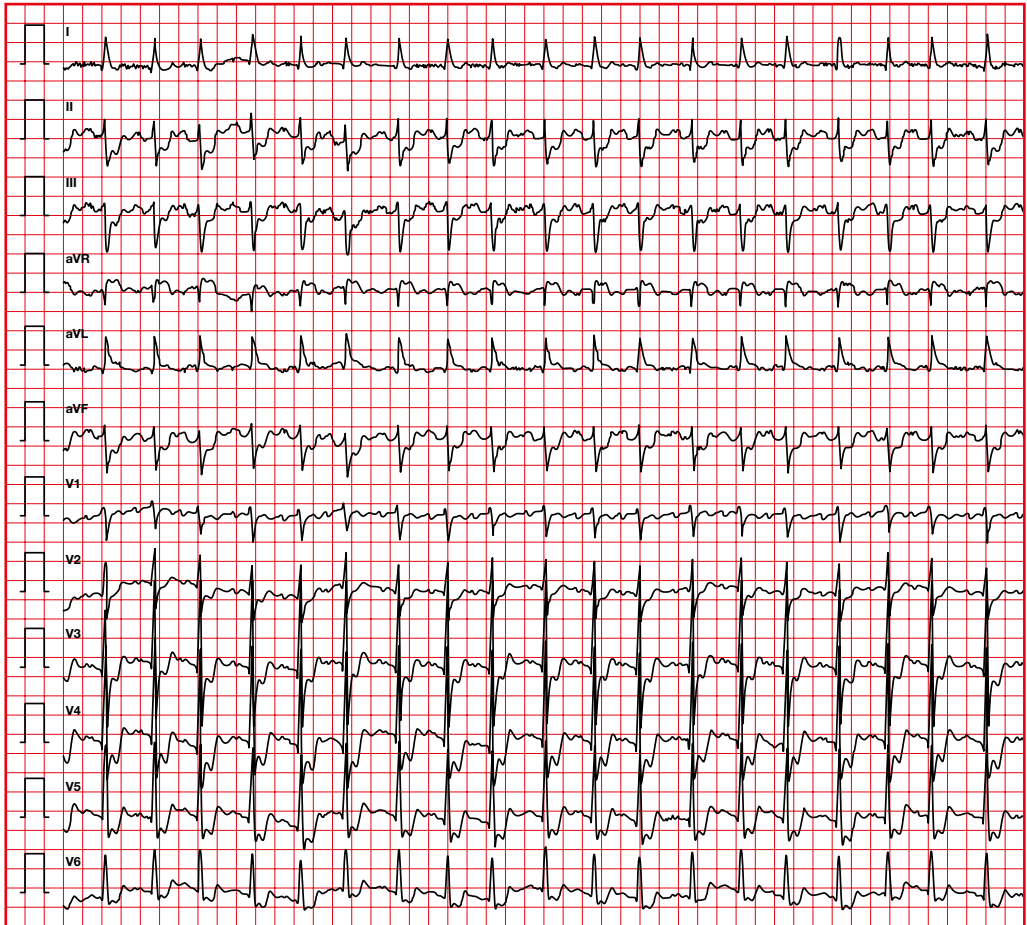
**T wave
recovery**
Weeks/months

8. Location of the infarction

The electrocardiographic abnormalities during an acute coronary syndrome define its location as well as the responsible artery.

Probable responsible artery	MI location		ST	Others
Anterior descending	Anterior	Anteroseptal	↑ V1 to V4	↓ ST II, III, aVF
		Anterolateral	↑ V3 to V6	
		Anterior extensive	↑ V1-V6	
Circumflex	Lateral	High lateral	↑ I, aVL	↓ ST II, III, aVF
		Low lateral	↑ V5-V6	↓ ST I, aVL
Right or dominant circumflex	Inferior	Pure inferior	↑ II, III, aVF	↓ ST I, aVL
		Inferoposterior	↑ II, III, aVF + ↓ V1-V2	
		Inferolateral	↑ II, III, aVF, V5-V6	
		Inferoposterolateral	↑ II, III, aVF, V5-V6 + ↓ V1-V2	
Circumflex or right	Posterior	Pure posterior	↓ V1-V2-V3	↑ ST V7-V8-V9
		Posterolateral	↑ V5-V6 + ↓ V1-V2	
Right	Right	With inferior MI normally (ST III > II)	↑ V1 > V2	↑ V3R, V4R
Left main disease	Anterolateral		Generalized ST depression (in more than 6 leads), especially in DII, DIII and V5 and V6. ST elevation ≥ 1 mm in aVR	

Left main coronary artery obstruction

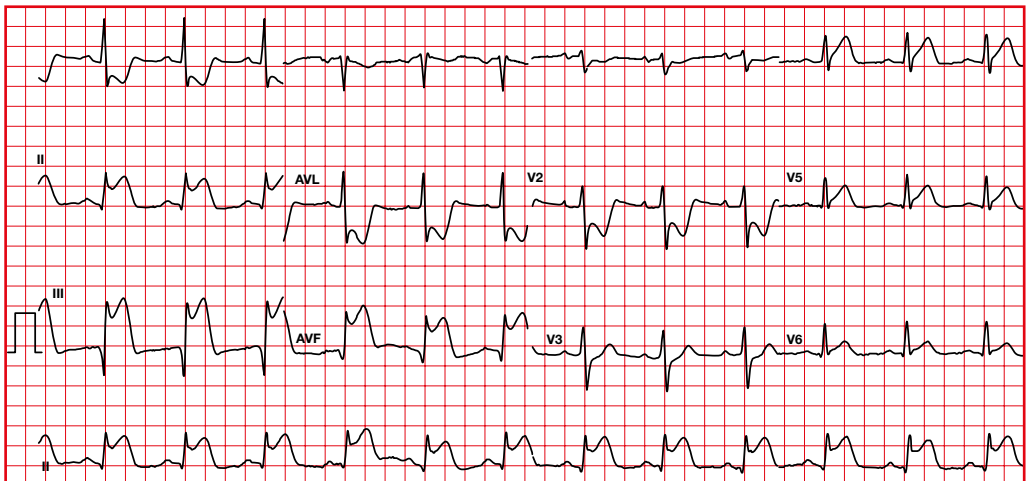


9. Acute and old myocardial infarction

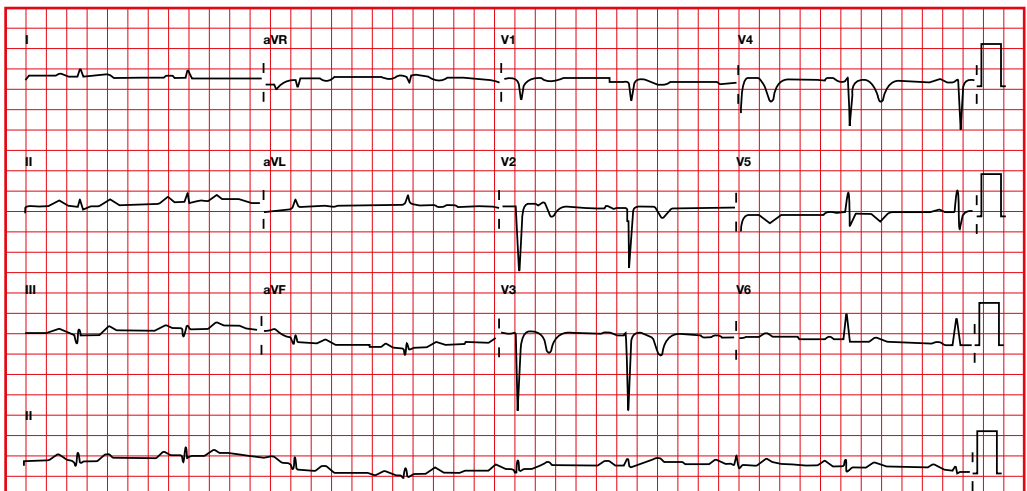
9.1. Acute or recent

- Abnormal Q waves.
- ST segment elevation (with or without ST segment depression in reciprocal leads).
- In a recent myocardial infarction, the ST segment can be isoelectric.

Acute MI



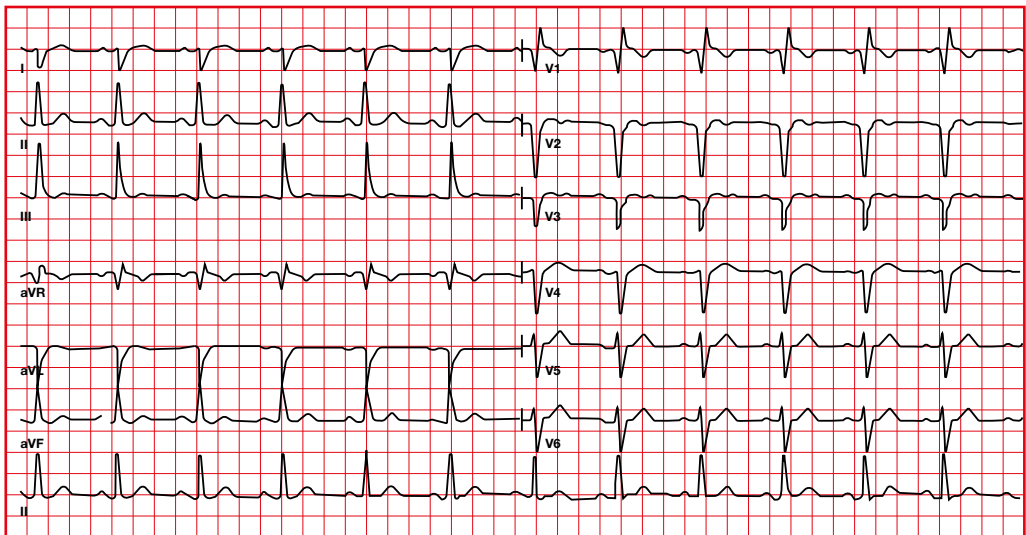
Recent MI



9.2. Old or indeterminate myocardial infarction

- Abnormal Q.
- Isoelectric ST segments.
- Normal or non-specific T wave abnormalities.

Old or indeterminate MI

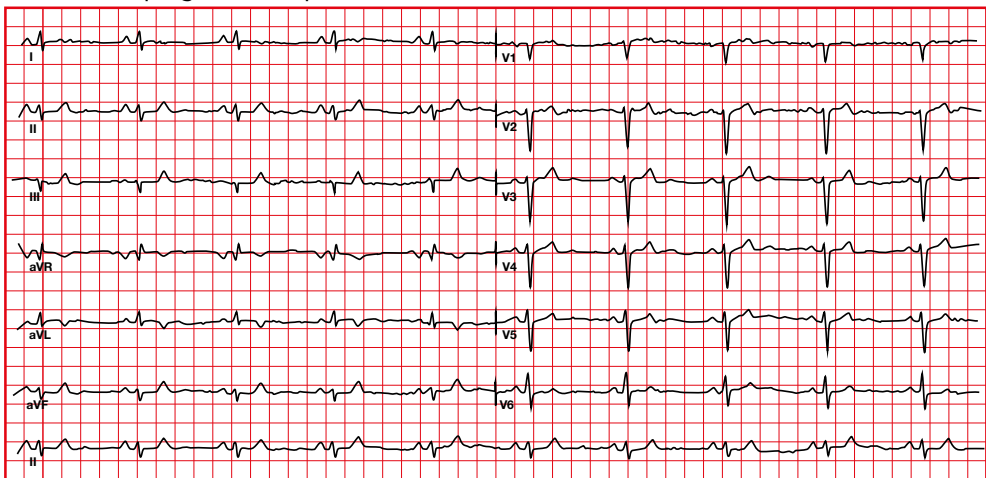


10. Non-Q infarction

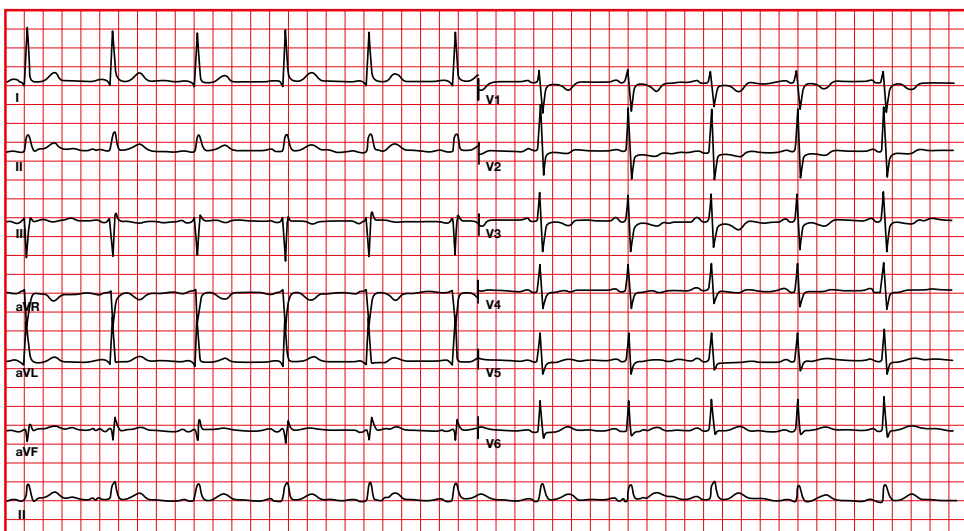
Infarction without Q can be seen in:

- Anterior infarction: decreased anterior forces with decreased R wave progression from V2 to V5. This finding is suggestive but not diagnostic of myocardial infarction.
- Posterior infarction: dominant R in V1-V3.

Poor R wave progression in precordial leads



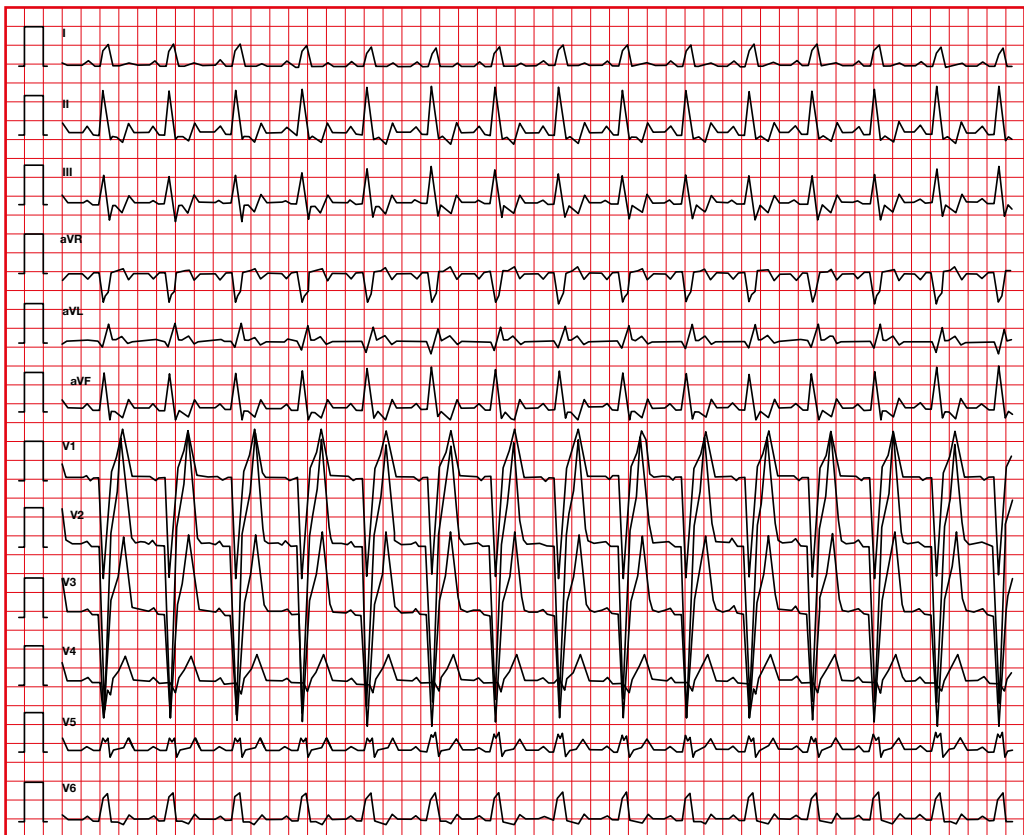
Posterior MI



11. Bundle branch block and infarction

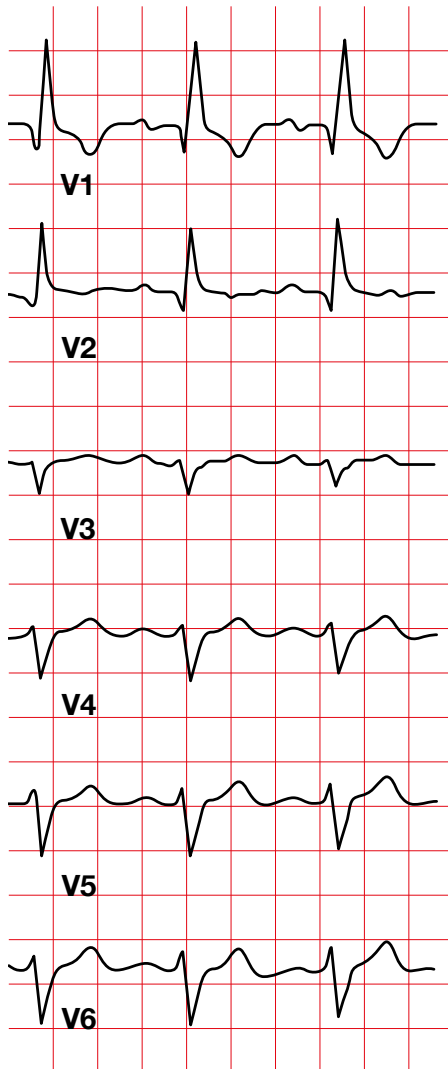
11.1. Suspicion of infarction in LBBB (Sgarbossa criteria)

- ST segment elevation ≥ 1 mm concordant with QRS direction.
- ST segment depression ≥ 1 mm in V1, V2, or V3.
- ST segment elevation ≥ 5 mm, discordant with QRS direction.

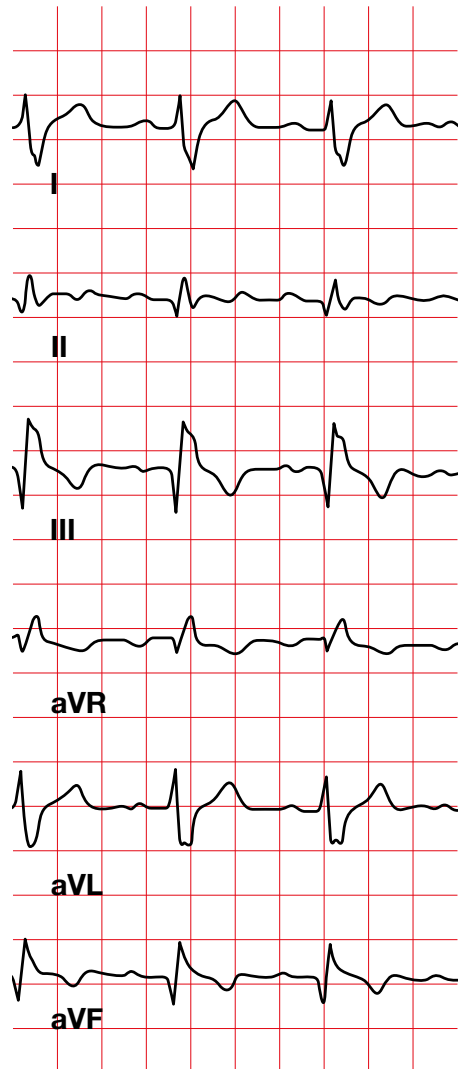


11.2 Right bundle branch block with myocardial infarction

Anteroseptal MI



Inferior MI



ARRHYTHMIAS



1. Definition

An arrhythmia is a disturbance of the heart rhythm that is not a physiological response. Arrhythmias can be caused by:

1. Problems with impulse generation

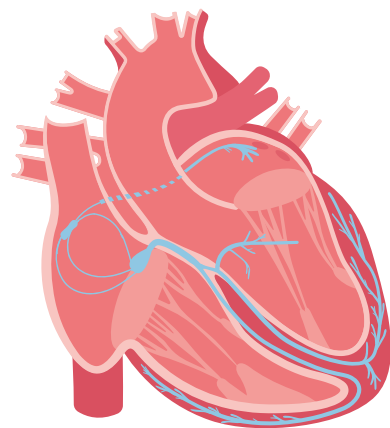
This alteration is caused by an increase in automatism or triggered electrical activity. It can be caused in any automatic cell (with spontaneous depolarization capability):

- Sinus node.
- Myocardium surrounding the atrioventricular node.
- His bundle.
- Left and right bundle branches.
- Purkinje cells.

2. Problems with impulse conduction

There is a problem with the transmission of the electrical stimulus.

- Blockage.
- Reentry.



2. Conduction system

The **heart's conduction system** transmits the electrical impulse through the five structures marked in the figure:

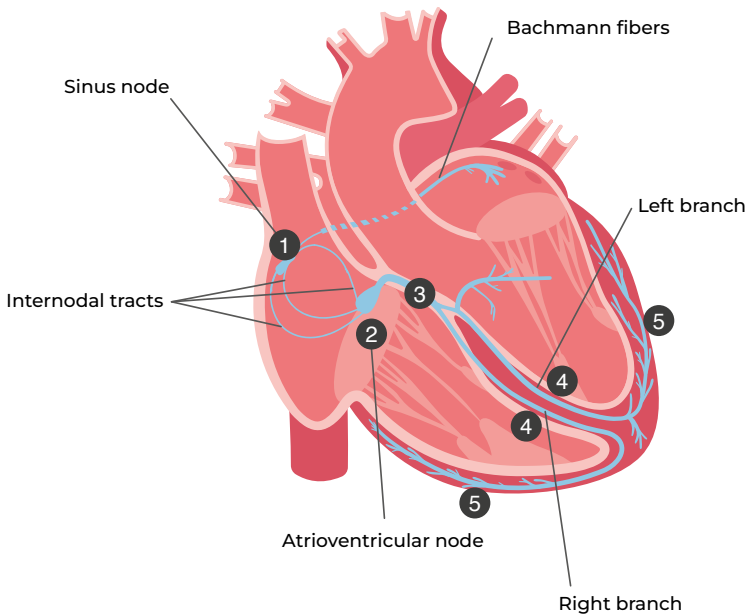
Sinus node (1) . Located in the upper area of the right atrium next to the insertion of the superior vena cava. Predominant pacemaker of the heart.

Electrical activity progresses from the sinus node into the left atrium through the **Bachmann fibers**.

Atrioventricular node (2). It is located in the lower area of the right atrium, next to the interatrial septum.

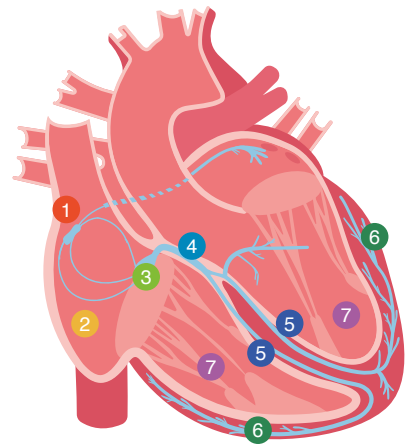
His bundle (3) . Common branch, which connects the AV node with the **right and left branches (4)**, located at the level of the interventricular septum.

Purkinje Fibers (5). They have pacemaker and rapid conduction capability, activating non-automatic or contractile cells from the endocardium to the epicardium.



3. Conduction velocities

- Pacemaker cells in the proximal areas control the more distal areas.
- When these proximal areas fail, the distal ones are activated, always at a lower frequency.
- The table shows the conduction velocities of the different areas.

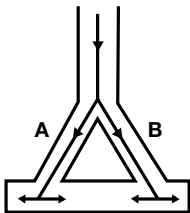


Activation sequence	Structure	Conduction velocity (m/s)	Pacemaker frequency (beats/minute)
1	Sinus node	< 0.01	60 - 100
2	Atrial myocardium	1.0 - 1.2	None
3	AV node	0.02 - 0.05	40 - 55
4	His bundle	1.2 - 2.0	25 - 40
5	Branches	2.0 - 4.0	25 - 40
6	Purkinje fibers	2.0 - 4.0	25 - 40
7	Ventricular myocardium	0.3 - 1.0	None

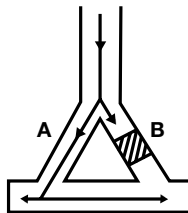
4. Reentry mechanism

In a reentry circuit, the transmission of the electrical impulse is perpetuated. Three conditions are needed for reentry:

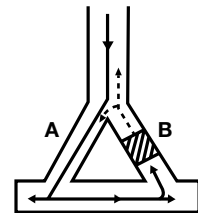
- A circuit.
- A difference in refractory period.
- Slow conduction in one of the parts of the circuit so that the rest of the circuit can recover and can be stimulated again.



Bidirectional conduction

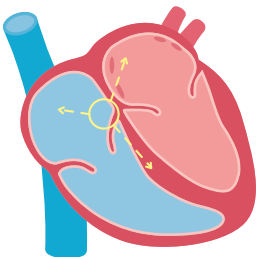


Unidirectional block

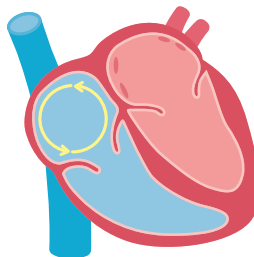


Recovery of excitability and reentry

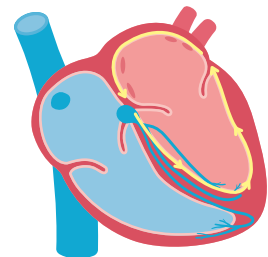
Examples of reentrant arrhythmias



AV nodal reentry



Flutter

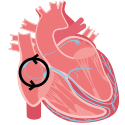

Reentry through an accessory pathway

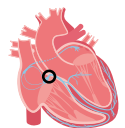
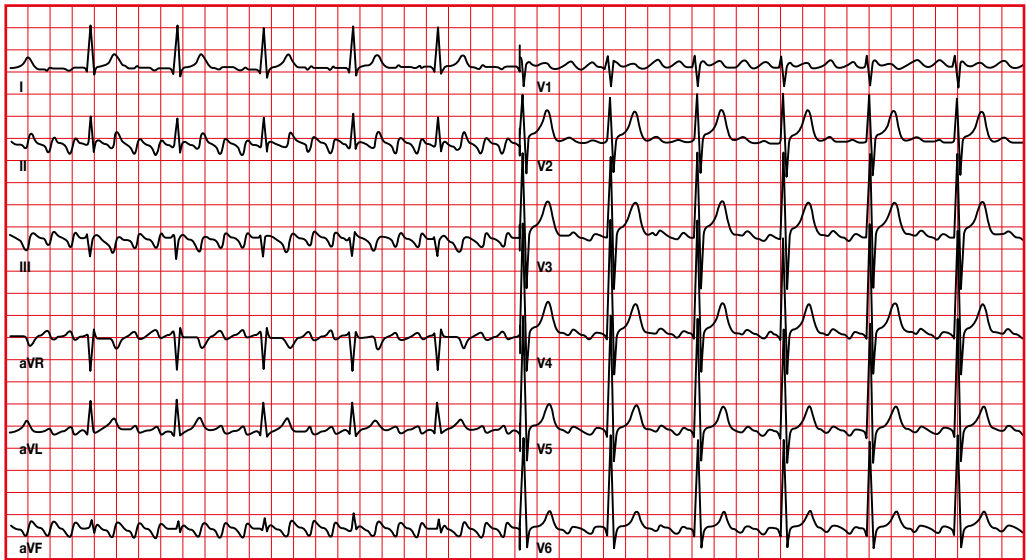
5. Type of arrhythmias

5.1. Arrhythmias with narrow QRS

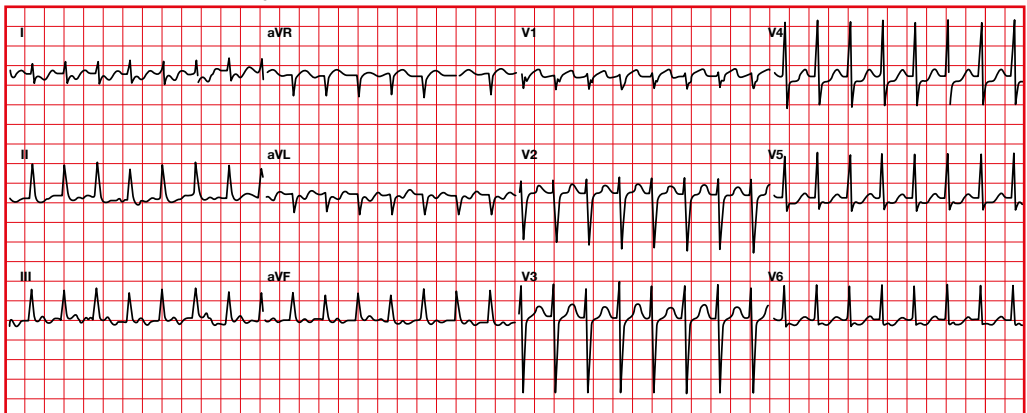
They are always supraventricular.



Flutter

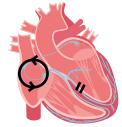


AV nodal reentrant tachycardia

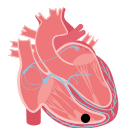
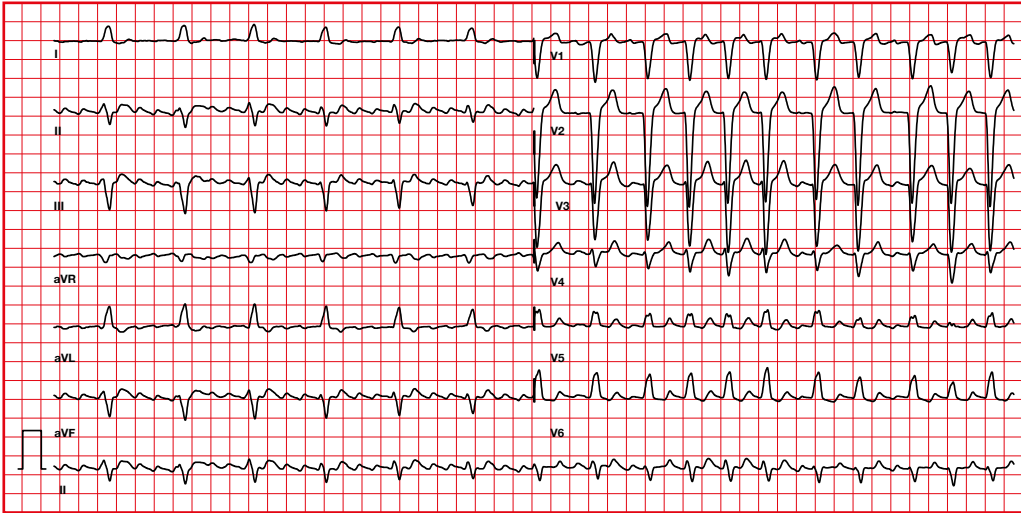


5.2. Arrhythmias with wide QRS complex

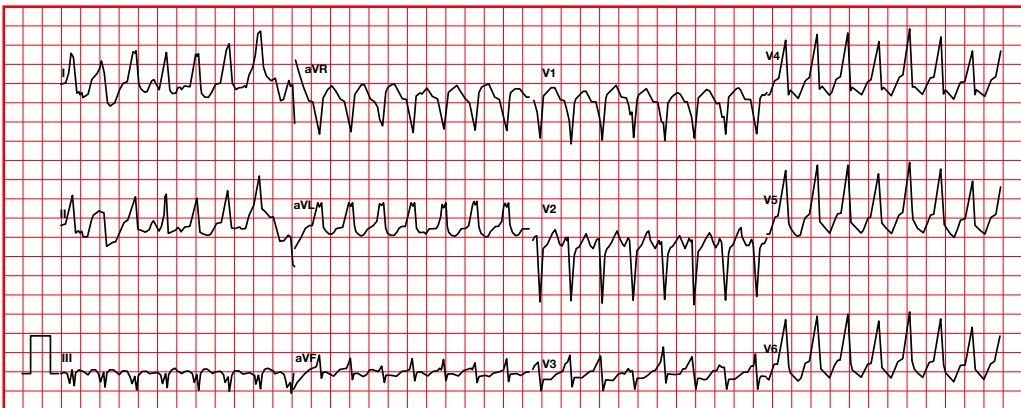
They can be either ventricular or supraventricular with conduction abnormality (branch block) or reentry.



Supraventricular. Flutter with left bundle branch block



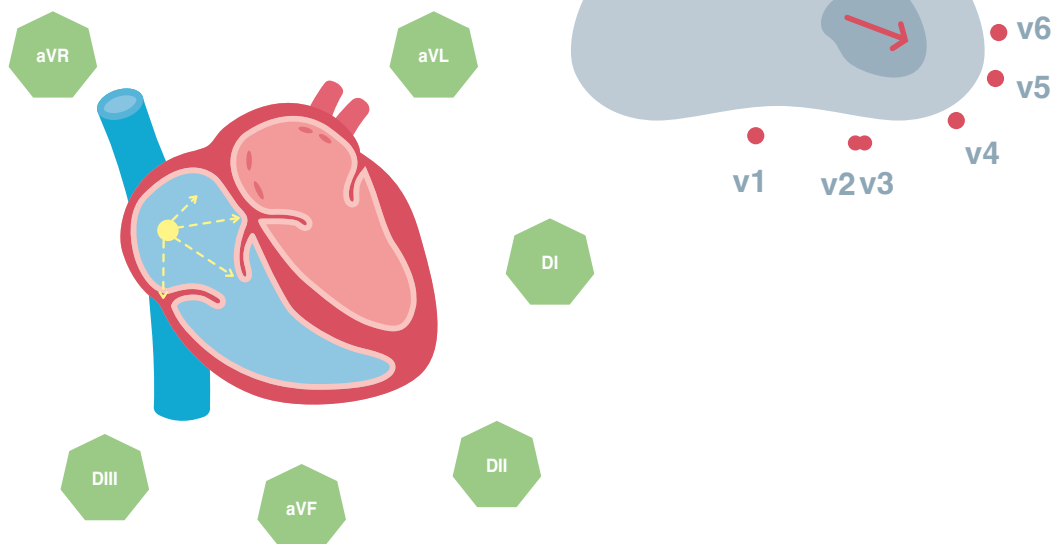
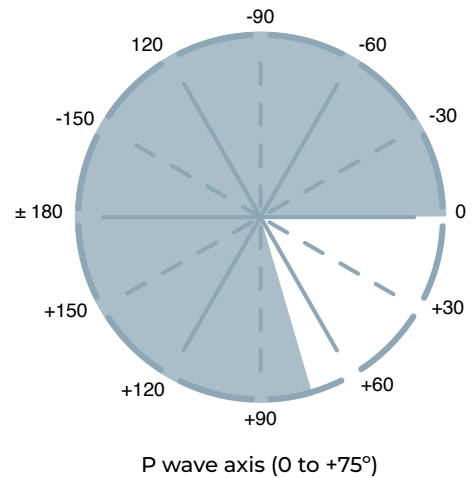
Ventricular tachycardia



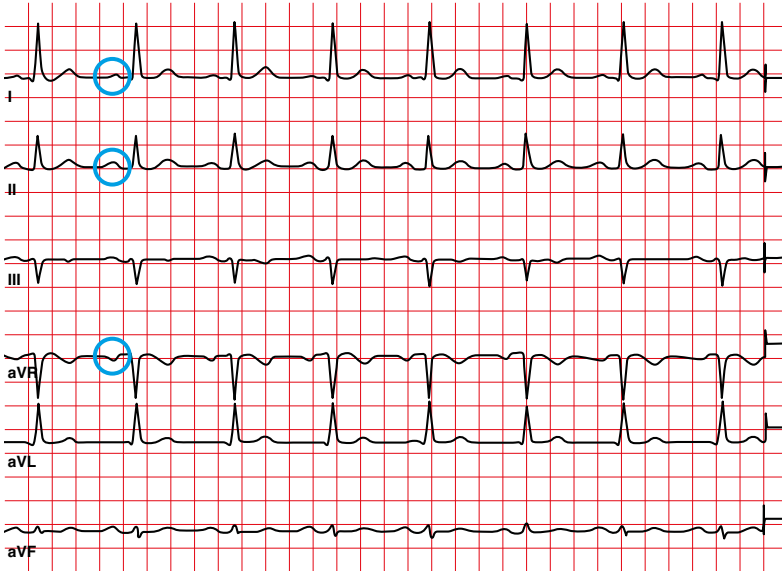
6. Supraventricular rhythms

6.1. Sinus rhythm

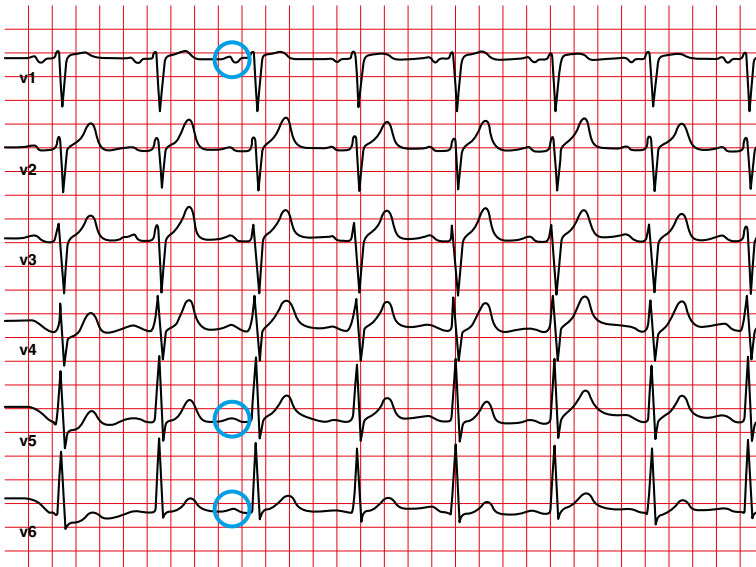
- Rhythm originating in the sinus node.
- P wave with a normal morphology (positive to I, II, negative in aVR).
- P wave axis 15-75°.
- HR between 60 and 100 beats per minute.
- Regular rhythm. Shortest and longest PP interval vary < 0.16 seconds (2 small squares).



Positive P in I, II — negative P in aVR



Positive P in V5, V6 — V1 usually biphasic



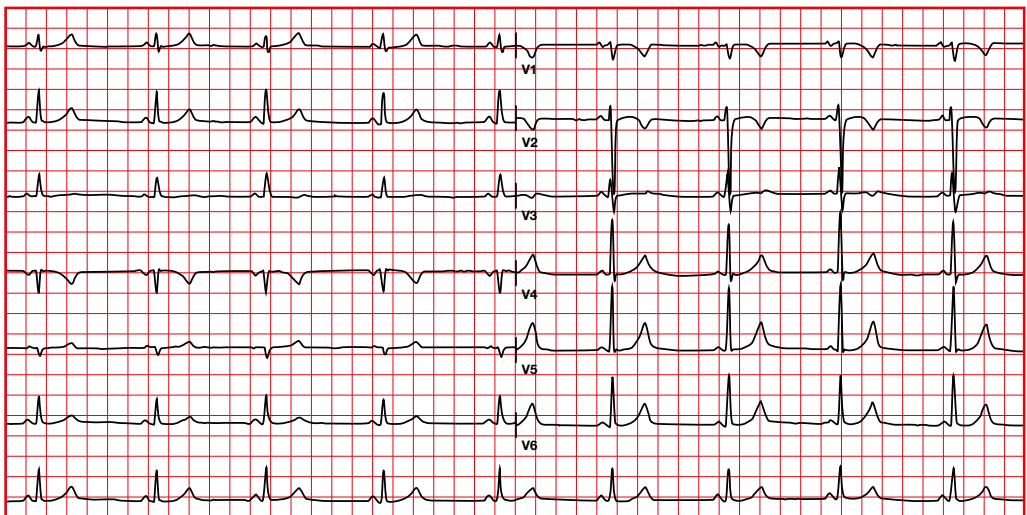
6.2. Sinus bradycardia

- It may be due to a decrease in the automatism of the sinus node.
- Normal P wave morphology.
- Heart rate less than 60 beats per minute.

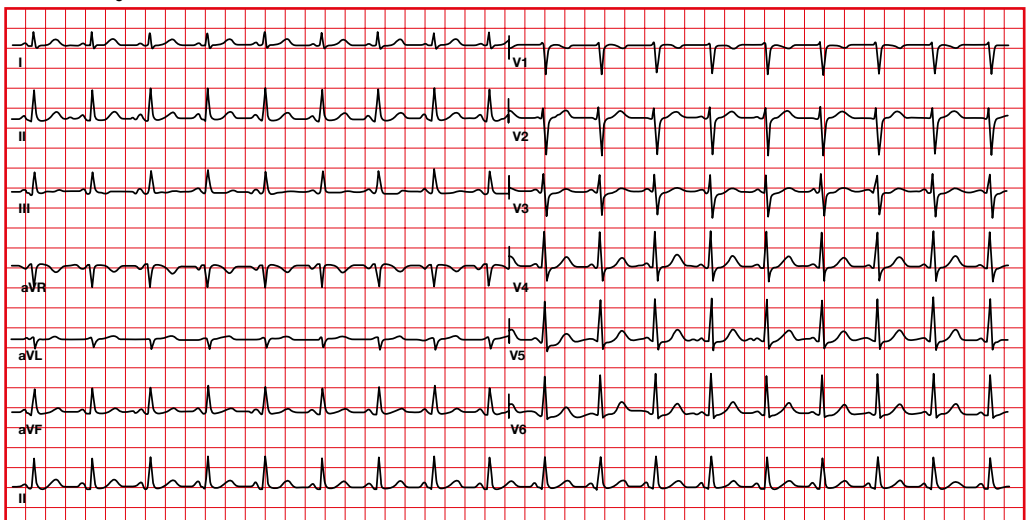
6.3. Sinus tachycardia

- Normal P wave morphology.
- Heart rate greater than 100 beats per minute.
- With increasing heart rate, the amplitude of the P wave increases and the PR shortens.

Sinus bradycardia

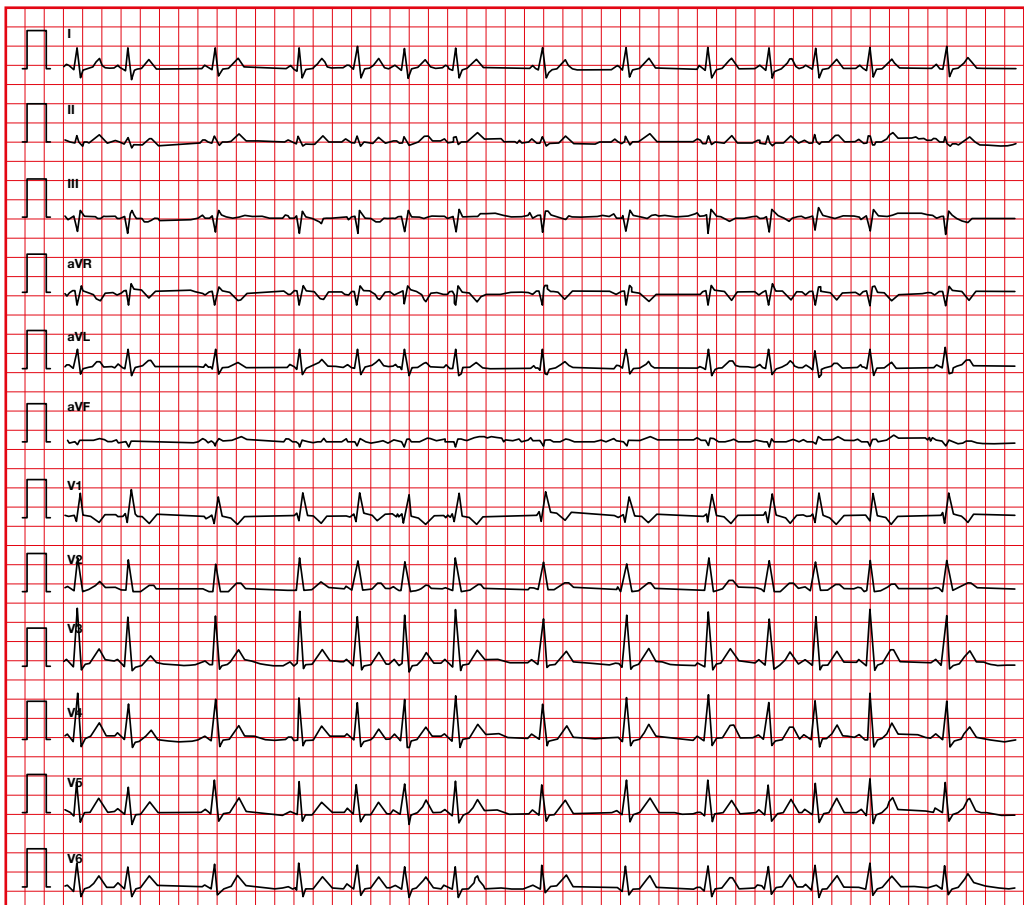


Sinus tachycardia



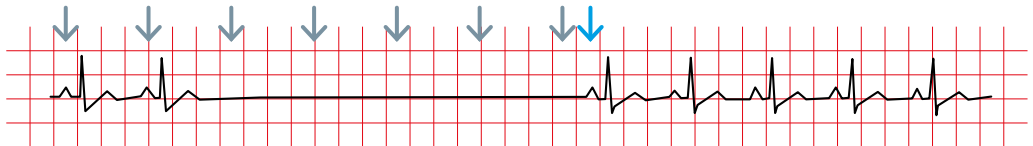
6.4. Sinus arrhythmia

- Normal P wave morphology.
- Gradual change of PP interval (may be sudden).
- There are more than 0.16 seconds difference between the longest and shortest PP interval.
- It is often used to define normal variation with breathing (sinus frequency increases with inspiration and decreases with expiration).



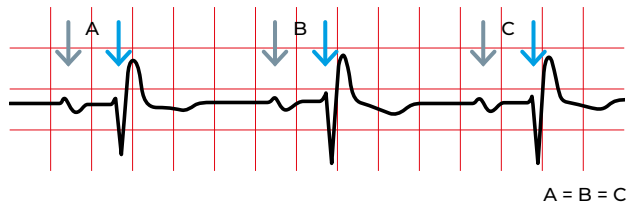
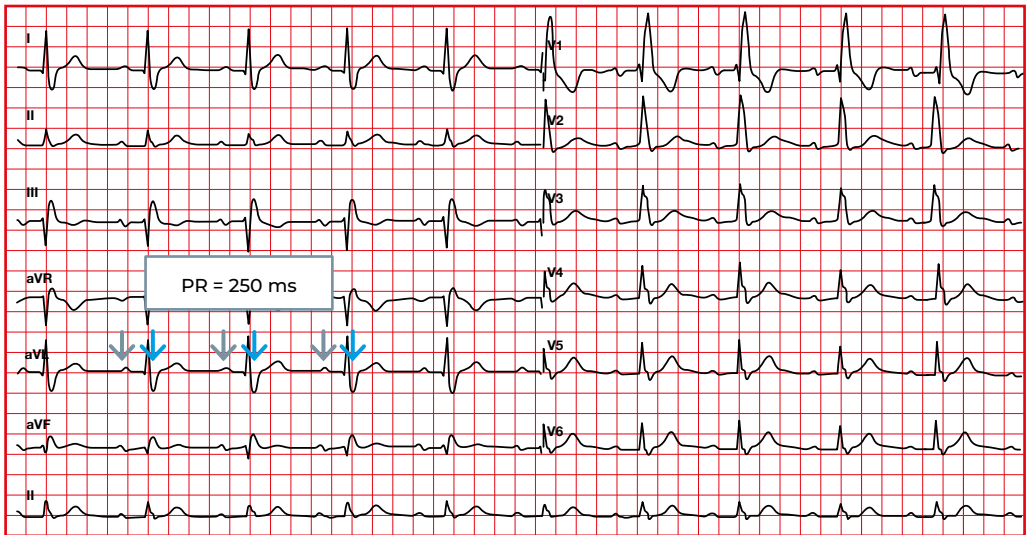
6.5. Sinus pause or arrest

- Inability of the sinus node to initiate an impulse, with absence of P waves.
- Constant PR interval.
- Sinus arrest: pause > 2 seconds.
- The pause is not multiple of the PP interval prior to the pause.



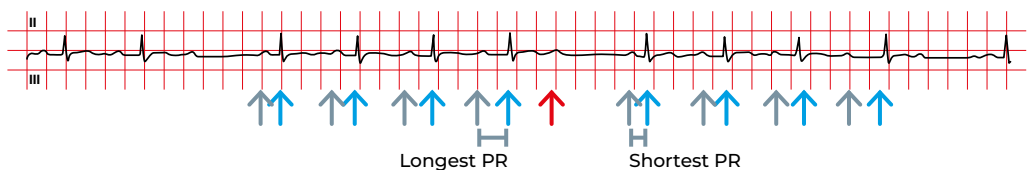
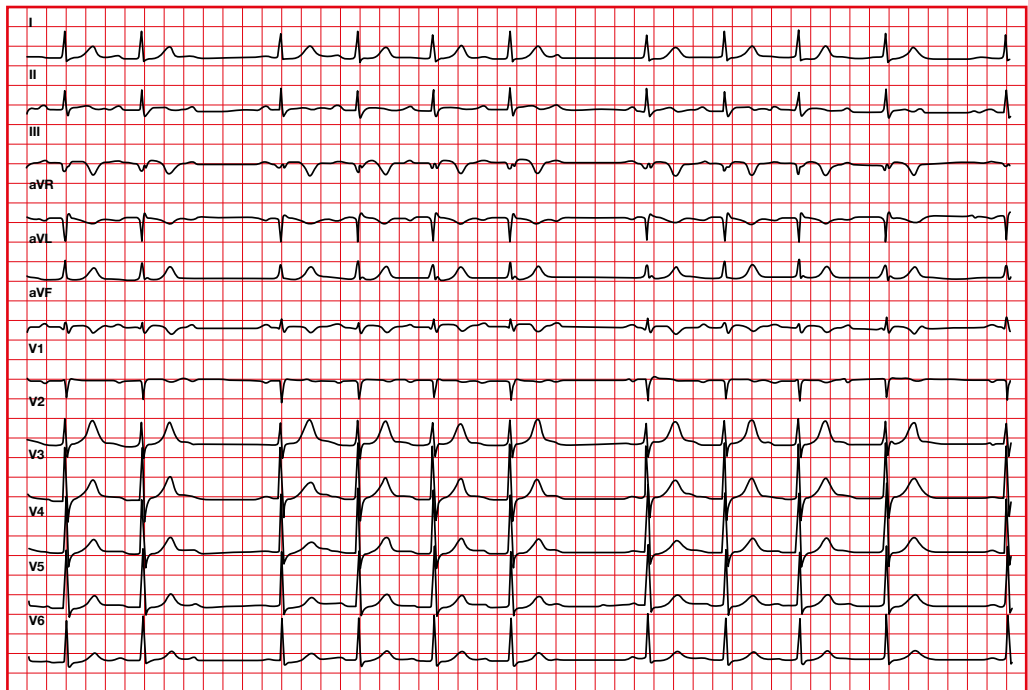
6.6. First-degree atrioventricular (AV) block

- Each P is followed by a QRS.
- PR > 0.20 seconds (in children > 0.18 seconds).
- Constant PR.
- Regular rhythm.



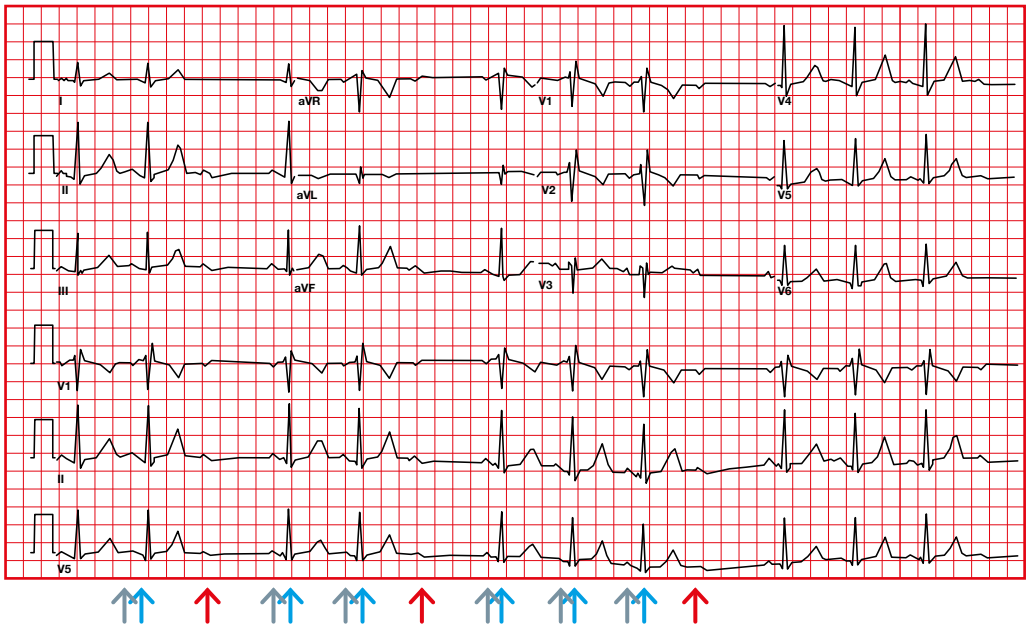
6.7. Second-degree AV block type 1 (Mobitz I or Wenckebach)

- Some P waves do not conduct.
- Progressive prolongation of the PR interval and shortening of the RR interval until a P wave is blocked and is not followed by a QRS.
- The RR interval containing the non conducted P is less than 2 PP intervals.
- Group beating pattern is usually seen, ventricular rhythm may appear irregular.



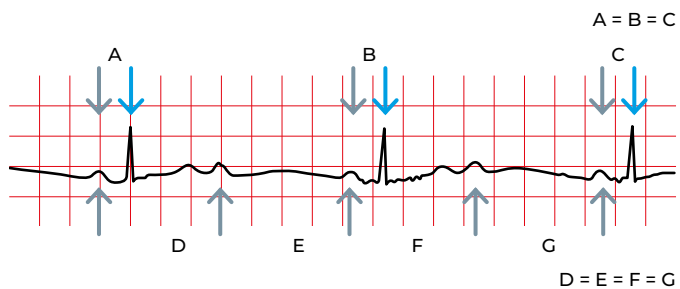
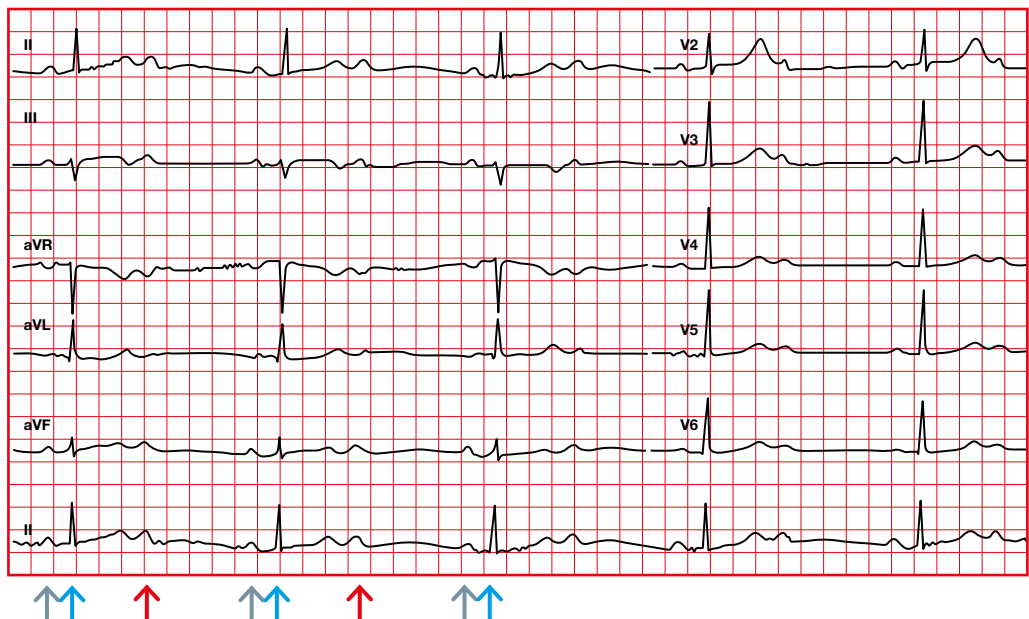
6.8. Second-degree AV block type 2 (Mobitz II)

- Some P waves do not conduct.
- Constant PR.
- There is no change in PR or RR before a non-conducted P wave.
- RR containing the blocked P is exactly twice the PP interval.



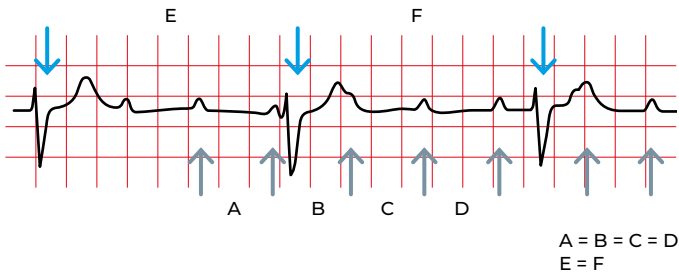
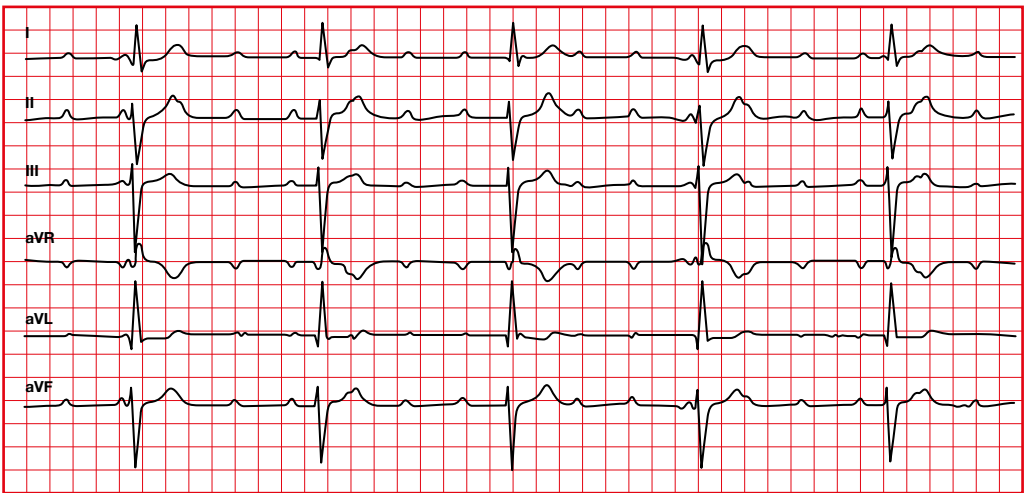
6.9. Second-degree AV block type 2:1

- It can be Mobitz I or II.
- If the QRS is abnormal, with bundle branch block or bifascicular block, it will most likely be Mobitz II.



6.10. Third-degree AV block

- Atrial and ventricular rhythms are independent and regular.
- Atrial rhythm is usually faster than the ventricular rate.
- The P wave can be hidden inside a QRS or a T wave.
- If the ventricular rhythm is faster than the atrial rhythm, there is AV dissociation, not AV block.

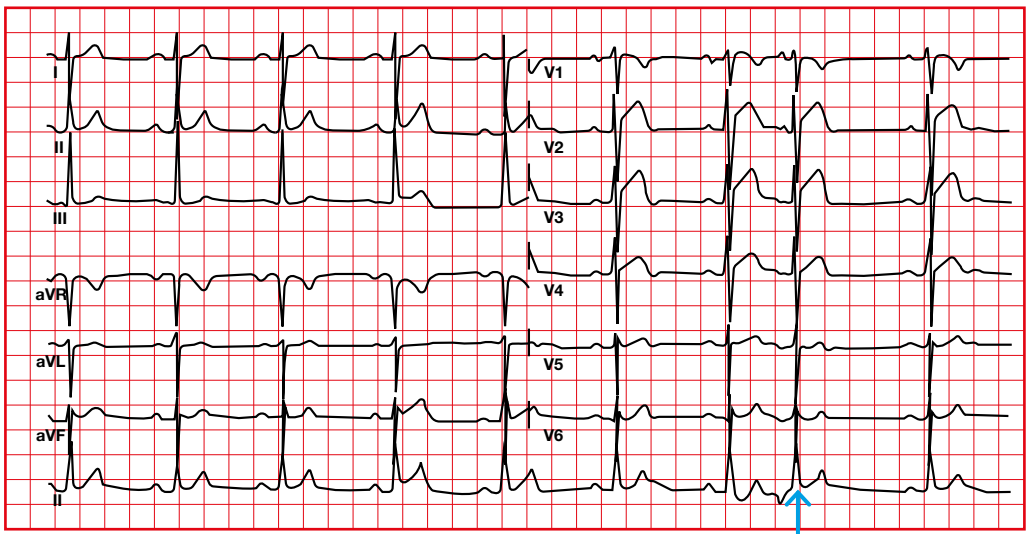


6.11. Atrial extrasystoles

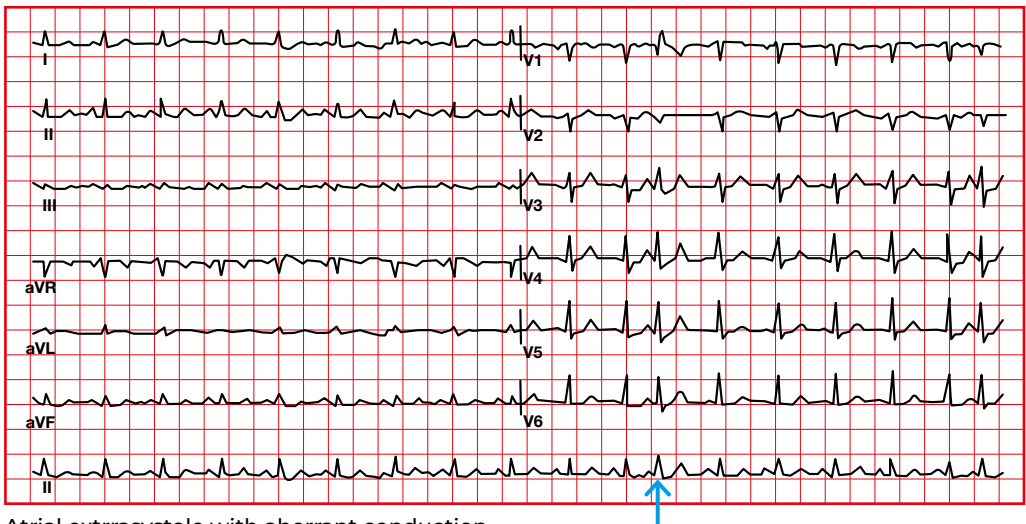
- The P wave has an abnormal morphology and it is premature compared to normal PP interval.
- The PR interval can be long, normal or short.
- There is no compensatory pause.
- In non-conducted atrial extrasystoles there is a P wave, but there is no QRS.

6.12. Atrial extrasystoles with aberrant conduction

A bundle branch block may occur if the extrasystole is very premature (extrasystole with aberrant intraventricular conduction).



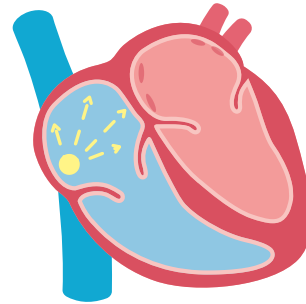
Atrial extrasystole



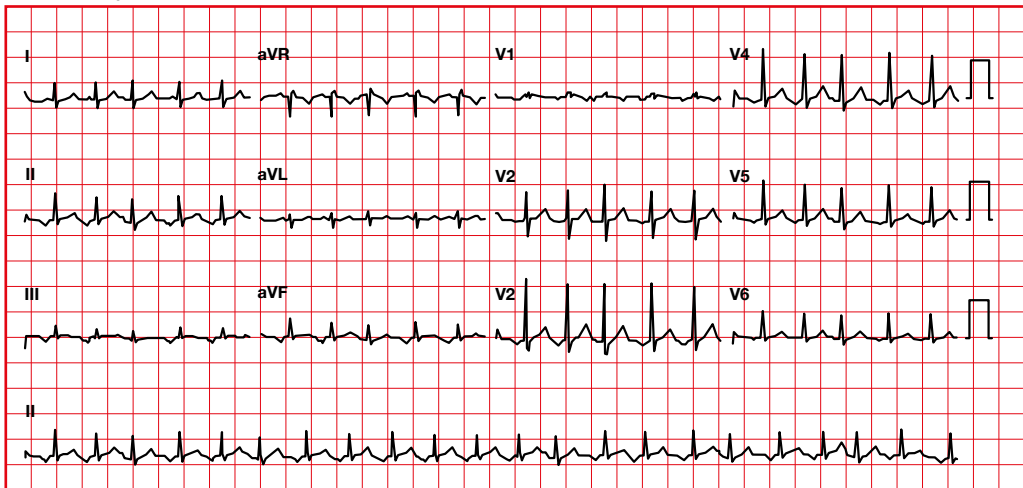
Atrial extrasystole with aberrant conduction

6.13. Atrial tachycardia

- P wave axis and morphology are different from sinus P wave.
- PR > 0.11 seconds.
- Heart rate > 100 beats per minute.



Atrial tachycardia

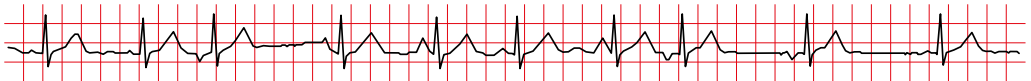
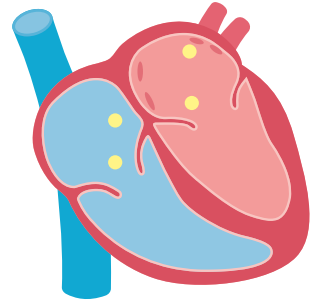


6.14. Multifocal atrial tachycardia

- P with three or more morphologies in a same lead.
- Heart rate > 100 beats per minute.
- Irregular rhythm: variable PR, RR and PR.

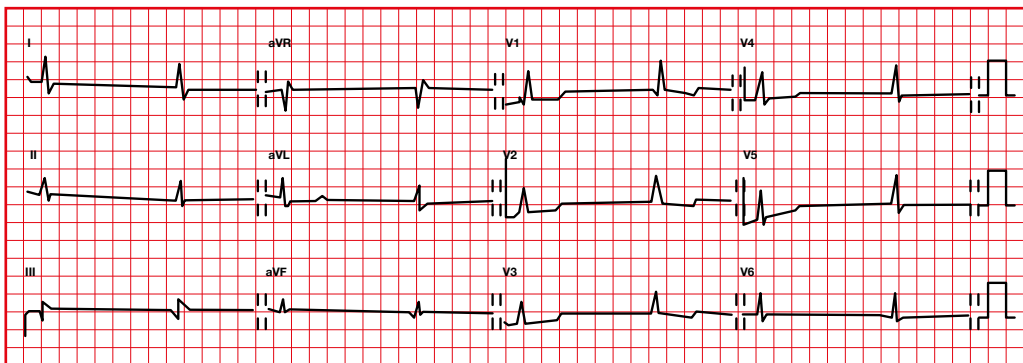
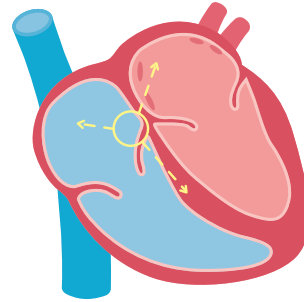
Multifocal P wave:

- It can be misinterpreted as sinus rhythm with multifocal premature complexes (but there is an atrial pacemaker, P wave, dominant).
- It can be misinterpreted as flutter/FA. We have to look for the isoelectric line, which is present in the multifocal.
- It is very common in patients with COPD (chronic obstructive pulmonary disease).



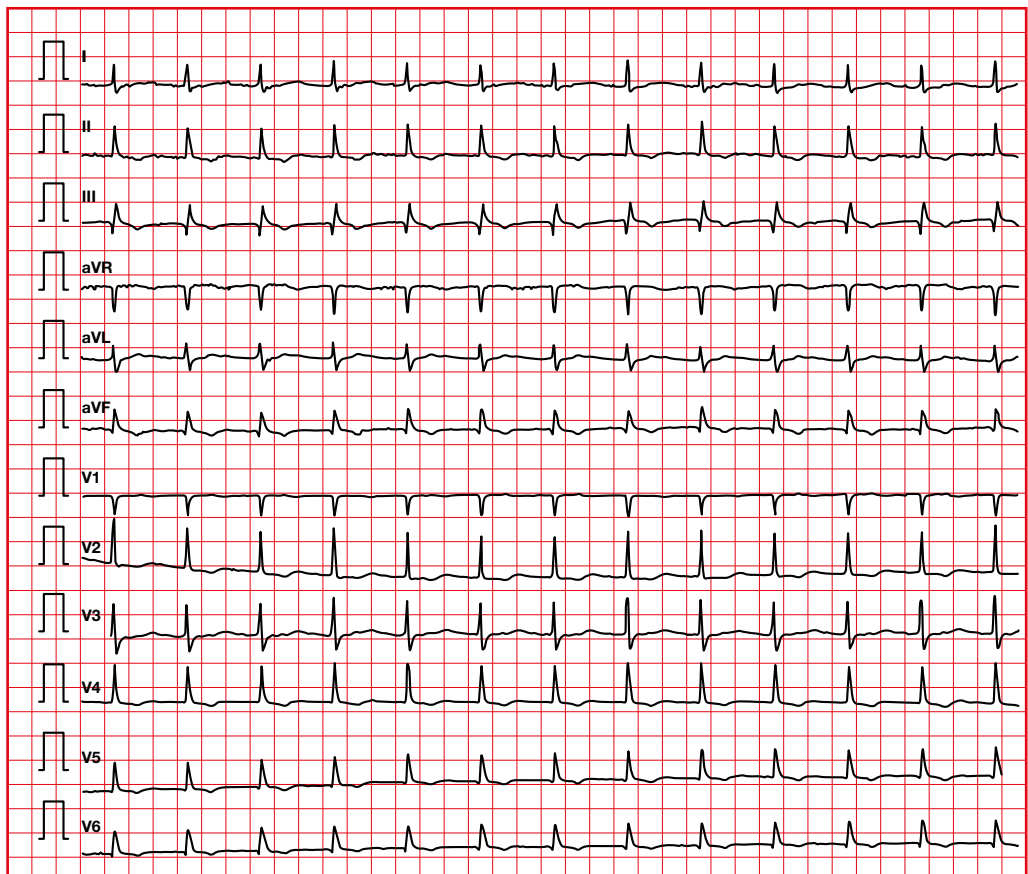
6.15. Junctional escape rhythm

- HR between 40 and 60 beats per minute.
- Retrograde atrial activation. Negative P in II, III, aVF can be seen in front, inside or behind the QRS.
- Normal or aberrant QRS.
- It usually appears in a situation of lack of sinus stimulation (high-grade block or pause).



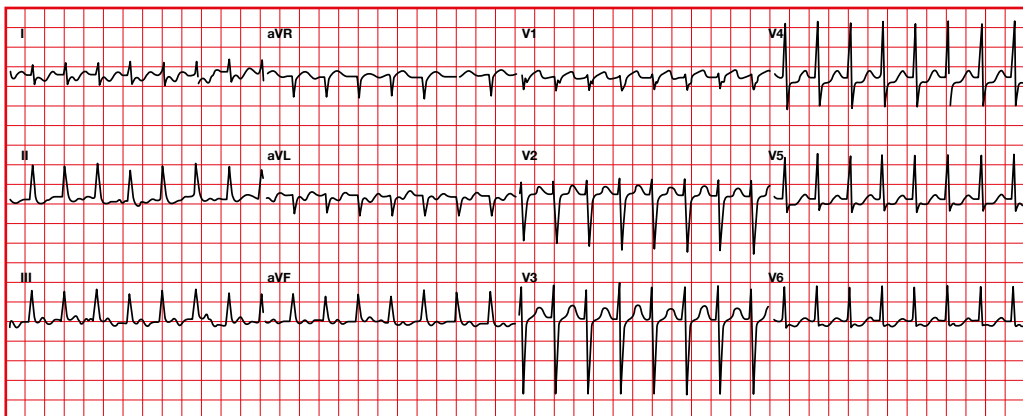
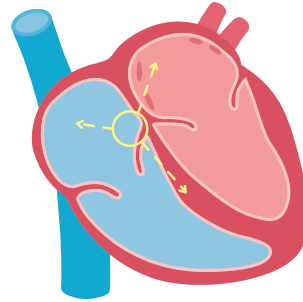
6.16. Accelerated junctional rhythm

- Caused by an increase in the automaticity of the atrioventricular node.
- HR > between 60 to 100 beats/minute.
- The P can precede, be inside the QRS, or behind the QRS.
- Normal or aberrant QRS.



6.17. Nodal or junctional tachycardia

- Caused by increased automaticity or by reentry.
- Retrograde atrial activation.
- Abnormal P in axis and morphology (P negative in II, III, aVF).
- Heart rate greater than 100 beats per minute.
- If there is retrograde conduction through the fast av nodal pathway, the P will appear quickly next to the QRS (RP < PR).
- If there is retrograde conduction through the slow av nodal pathway, the P wave will be farther away from the QRS (RP > PR).

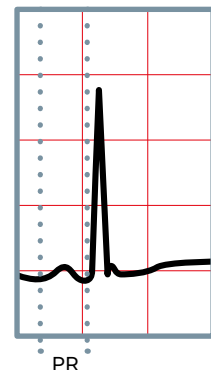
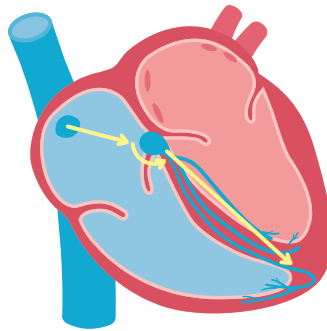


6.18. Junctional reentry and accessory pathway

- Micro-reentry: junctional.
- Macro-reentry: accessory pathway.

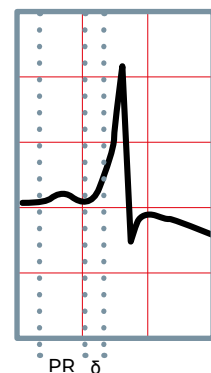
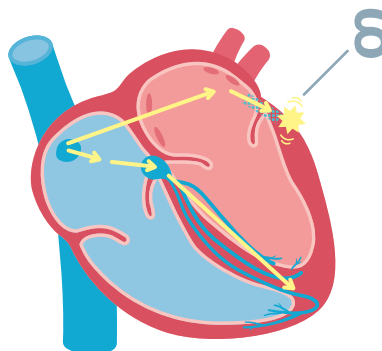
LGL (Lown-Ganong-Levine syndrome)

Combination of short PR, normal QRS, and supraventricular tachyarrhythmias. There is a normal P wave and QRS, but the PR segment has shortened due to the faster activation of the ventricle, bypassing the AV node.



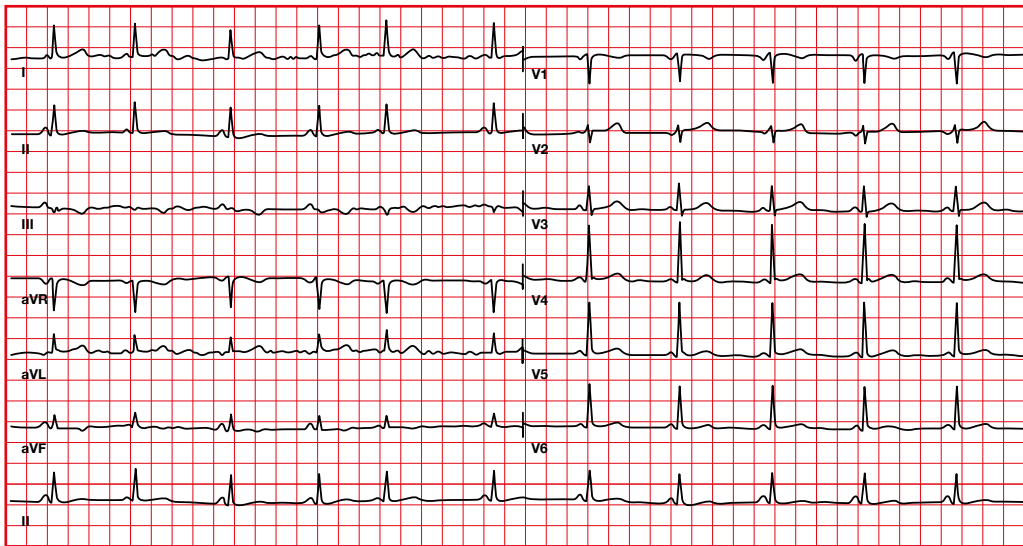
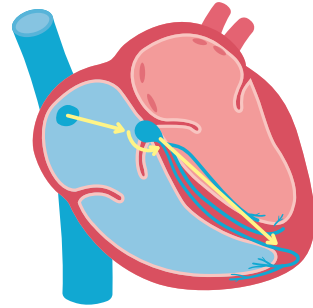
WPW (Wolff-Parkinson-White syndrome)

Combination of short PR, wide QRS caused by delta wave, and supraventricular tachyarrhythmias. The delta wave corresponds to the activation of the part of the ventricle adjacent to the accessory pathway.



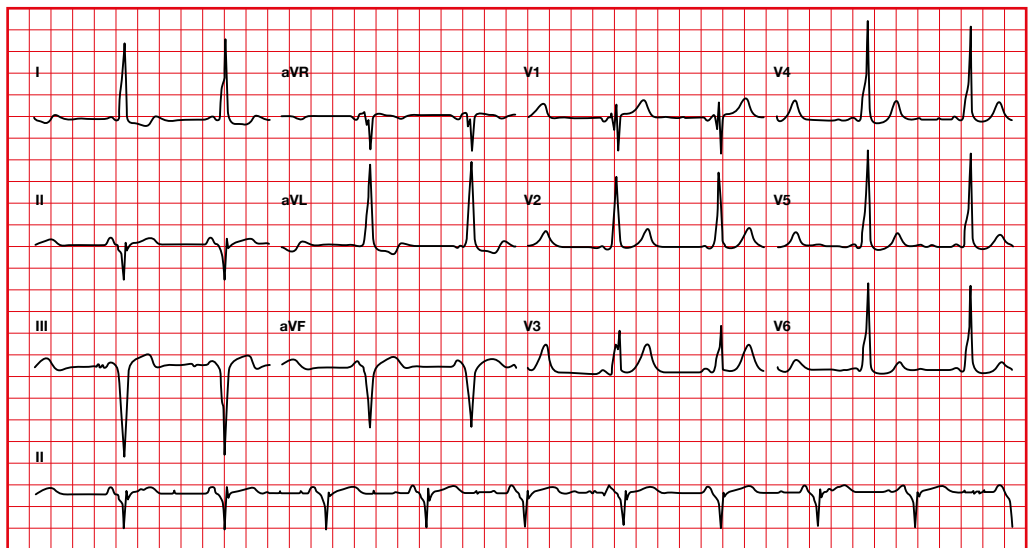
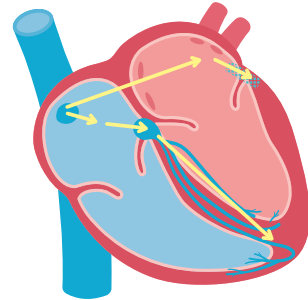
6.19. Long-Ganong-Levine syndrome

There is a faster activation of the ventricular depolarization, due to an accelerated conduction at the atrioventricular node level.

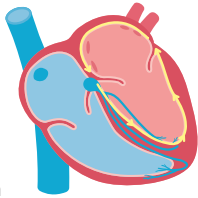


6.20. Wolff-Parkinson-White syndrome

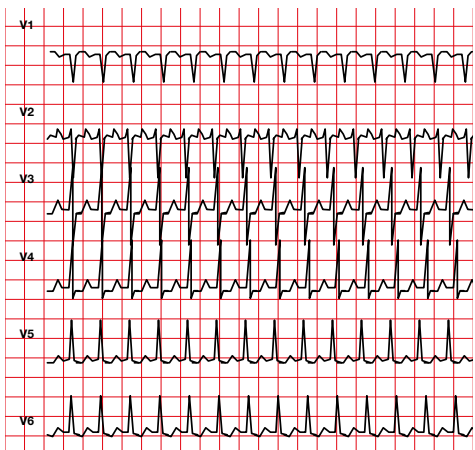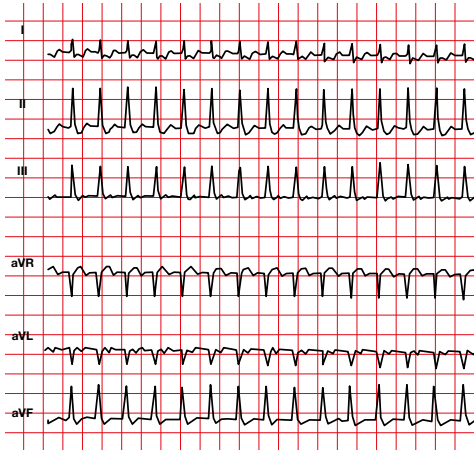
There is a faster activation of ventricular depolarization, due to the activation of ventricular tissue adjacent to an accessory pathway.



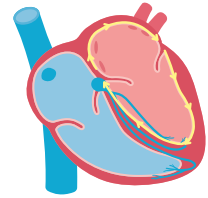
- **Orthodromic tachycardia.** The impulse travels in the right direction (the impulse travels down the His bundle and returns to the atrium via the accessory pathway). The QRS can be narrow.



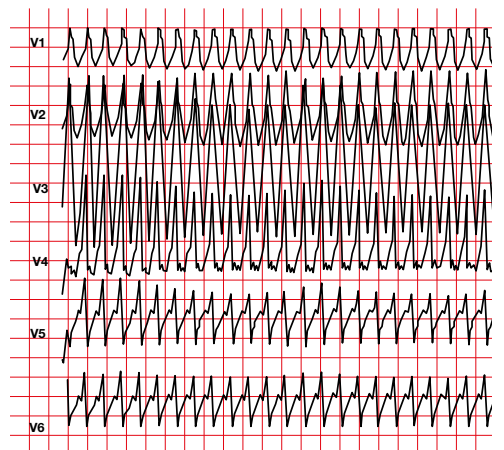
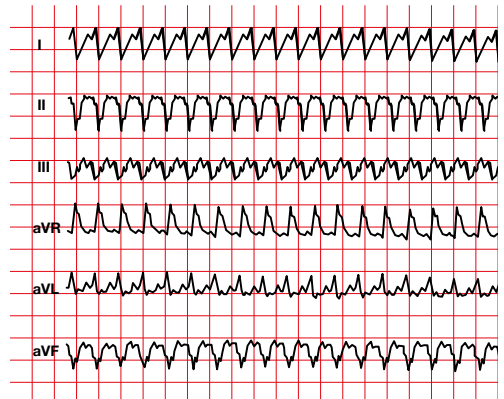
Orthodromic tachycardia



- **Antidromic tachycardia.** The impulse travels in the opposite direction (the impulse travels down the accessory pathway and returns to the atrium through the His bundle). The QRS will always be wide.

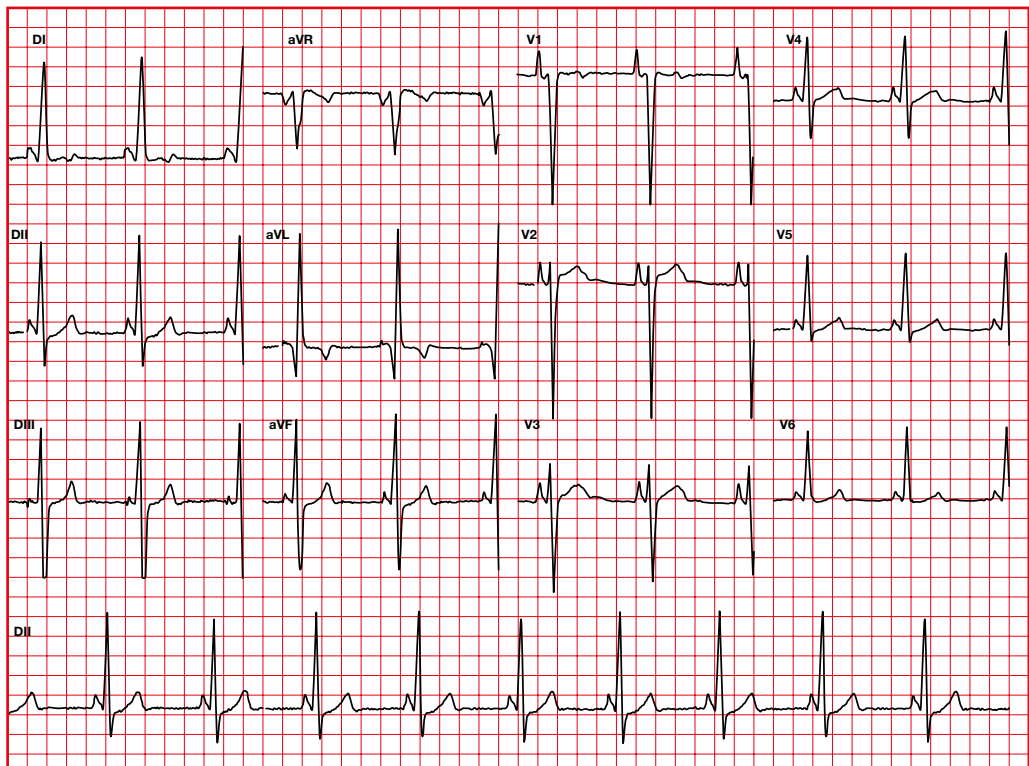


Antidromic tachycardia



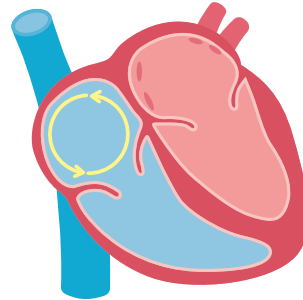
6.21. Short PR with left ventricular hypertrophy

The phenotype characterized by the presence of pre-excitation, conduction abnormalities, and left ventricular hypertrophy may be associated with genetic variations in the PRKAG2 gene, causing an alteration in glycogen storage in the cardiac myocytes.

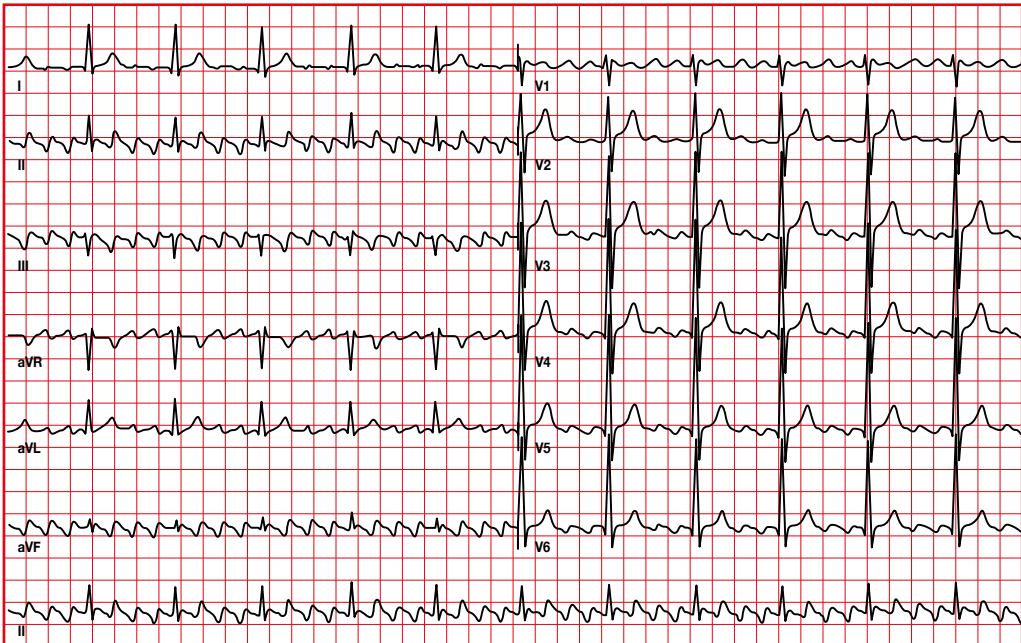


6.22. Flutter

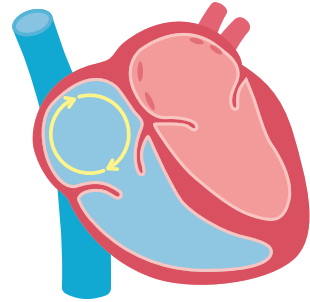
- Fast atrial waves are detected (F waves or flutter waves at 250-300 per minute).
- In the typical flutter, the circuit uses the cavotricuspid isthmus.
- Suspect flutter when the frequency is 150 beats per minute (2:1 block).



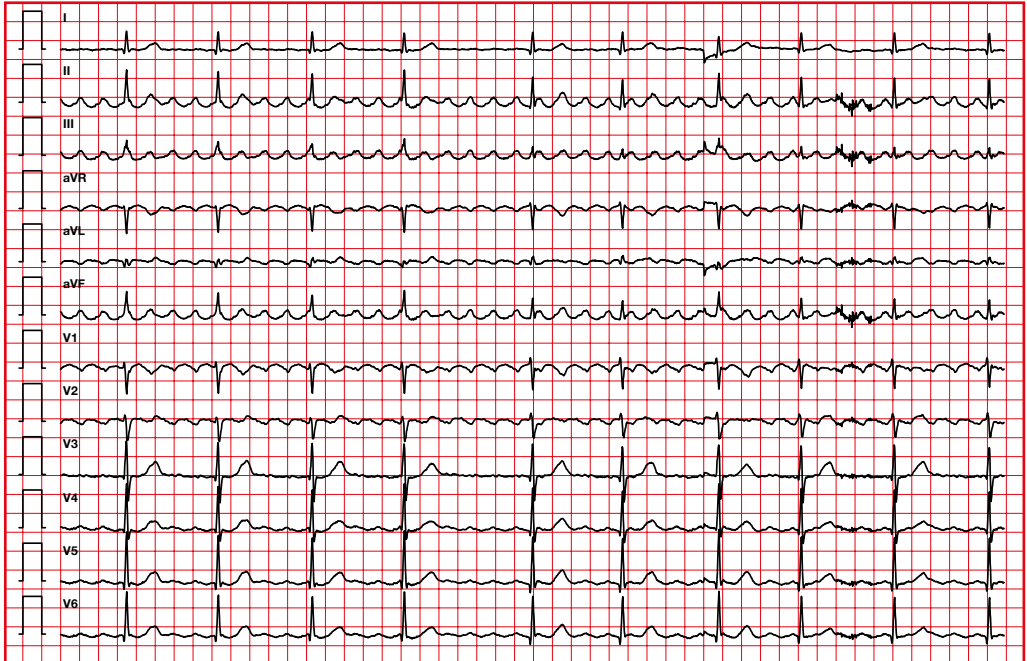
Typical flutter



Negative F waves in II, III and aVF. Counterclockwise circuit.

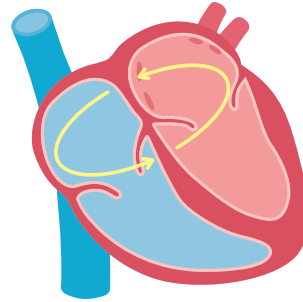


Typical atrial flutter with variable AV conduction

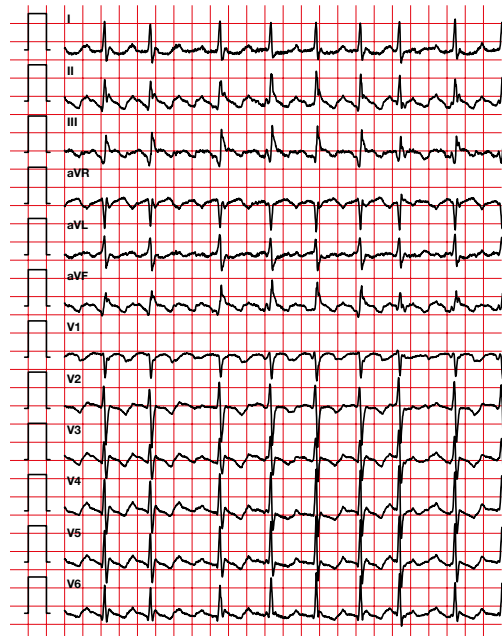
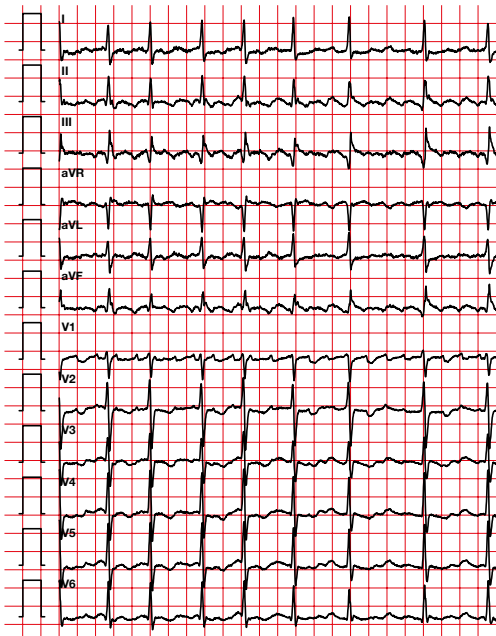


6.23. Atypical flutter

- Applies to rapid atrial tachycardias with ECG patterns that differ from the typical flutter described above, as well as to reentrant tachycardias with different circuit configuration than the typical flutter circuit.
- Atypical flutter is often associated with structural heart disease, especially in patients who have undergone cardiac surgery or extensive catheter ablation for the treatment of atrial fibrillation.
- The circuit does not use the cavotricuspid isthmus.

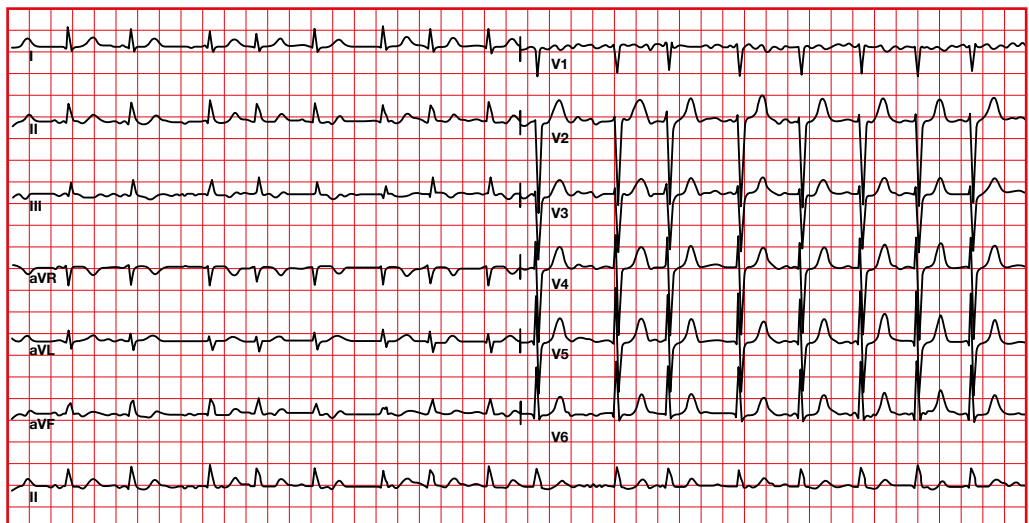
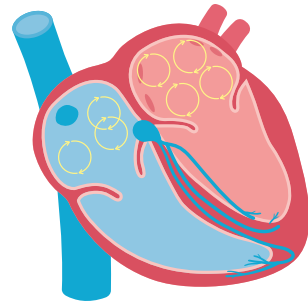


Atypical flutters in a patient with previous ablations



6.24. Atrial fibrillation

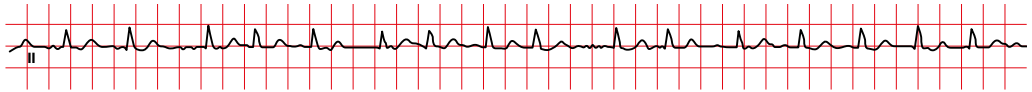
- Fast atrial rate (between 400 and 700 per minute).
- It is a disorganized rhythm, with no ability to generate atrial contraction.
- We will see the presence of f waves (fibrillation waves).
- The ventricular rhythm is irregular.
- When there is slow atrial fibrillation, you have to suspect digitalis intoxication.



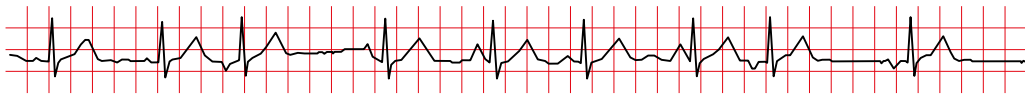
6.25. Arrhythmias with narrow QRS and irregular rhythm

Atrial fibrillation and multifocal atrial tachycardia are typically irregular.

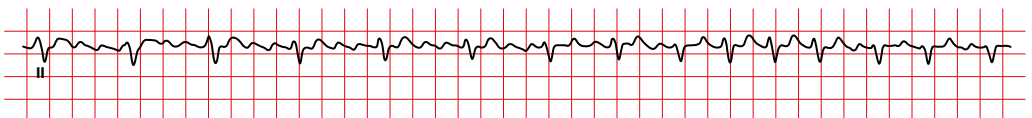
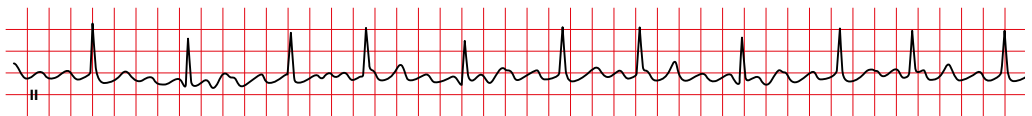
Atrial fibrillation



Multifocal atrial tachycardia



The frequency and regularity of the QRS complexes in atrial flutter depend on the AV conduction.



↑ 4:1 ↑ 75 bpm ↑ 3:1 ↑ 100 bpm ↑ 2:1 ↑ 150 bpm

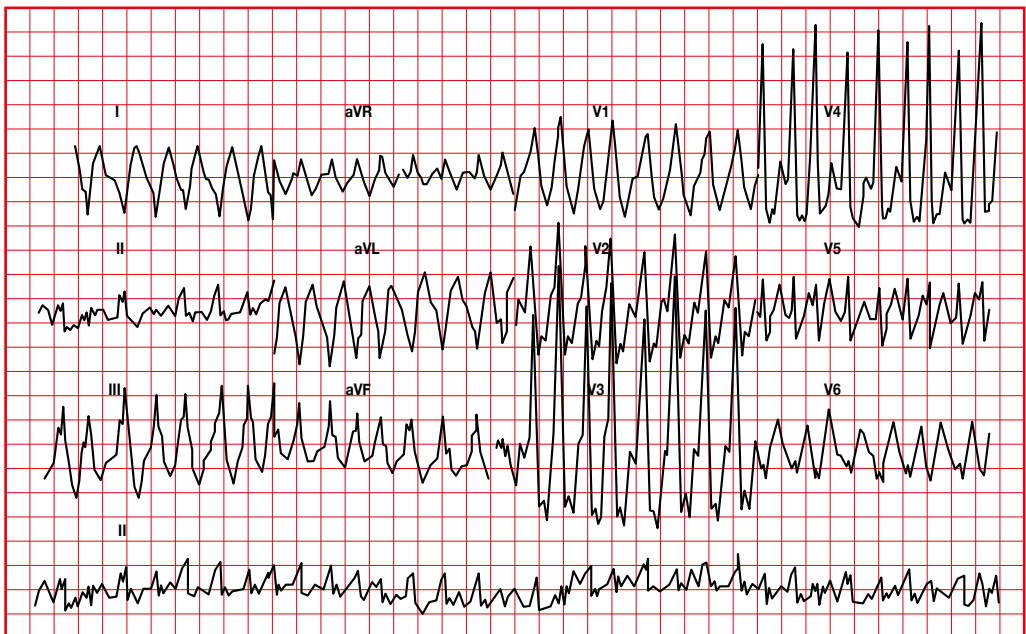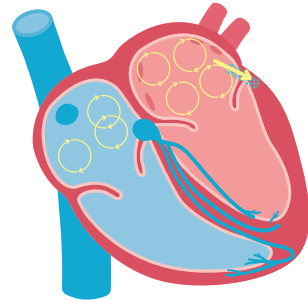
6.26. WPW with atrial fibrillation

In WPW syndrome, when atrial fibrillation is triggered, the impulse is transmitted through the accessory pathway and not through the AV node (therefore there is no brake on ventricular activation).

The ventricular rate can reach 200-300 impulses per minute and cause ventricular fibrillation and sudden death.

An atrial fibrillation or flutter with QRS that varies in width and HR > 200 suggests WPW.

We will observe wide changing QRS complexes with irregular rhythm.

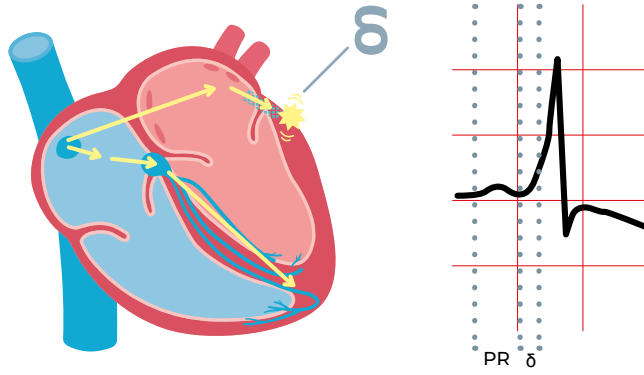


6.27. Electrocardiogram before and after ablation

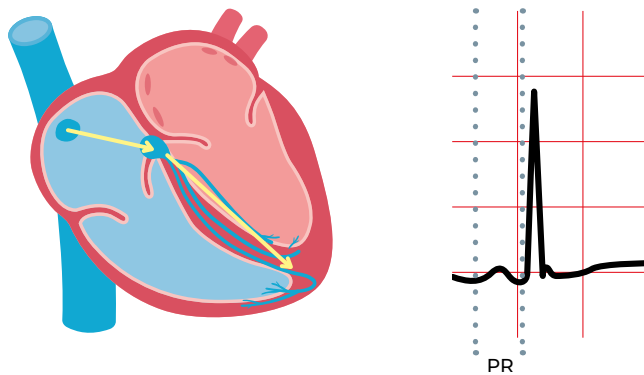
Ablation of the accessory pathway eliminates the anomalous communication between the atrium and the ventricle. All activation is forced through the atrioventricular node, recovering the normality.

Since there is no activation of ventricular tissue adjacent to the accessory pathway, the delta wave disappears and the PR interval is normalized.

Before ablation



After ablation



6.29. Classification of supraventricular arrhythmias

	Tachycardia	P wave	QRS
Sinus tachycardia	Rhythmic (90-130 bpm)	Normal morphology(+ DII, DIII and -aVR)	Narrow (with intact conduction system)
Atrial tachycardia	Rhythmic (150-220 bpm)	Non sinus morphology	Narrow (with intact conduction system)
Multifocal atrial tachycardia	Arrhythmic (90-150 bpm)	Non sinus morphology (3 different P waves)	Narrow (with intact conduction system)
Nodal or junctional tachycardia (paroxysmal supraventricular)	Rhythmic (120-150 bpm)	P embedded in the QRS or just after (hard to spot)	Narrow (with intact conduction system)
Orthodromic tachycardia (accessory pathway WPW)	Rhythmic (120-180 bpm)	After the QRS Inferior negative P wave (DII, DIII and aVF) and positive in aVR	Narrow (with intact conduction system)
Antidromic tachycardia (accessory pathway WPW)	Rhythmic (120-180 bpm)	After the QRS P difficult to be visualized due to wide QRS	Wide
Atrial Flutter	Rhythmic 150 bpm if 2:1 conduction	F waves	Narrow (with intact conduction system)
Atrial fibrillation	Arrhythmic (150-180 bpm) Irregular ventricular conduction	f waves	Narrow (with intact conduction system)

7. Ventricular rhythms

7.1. Ventricular extrasystole

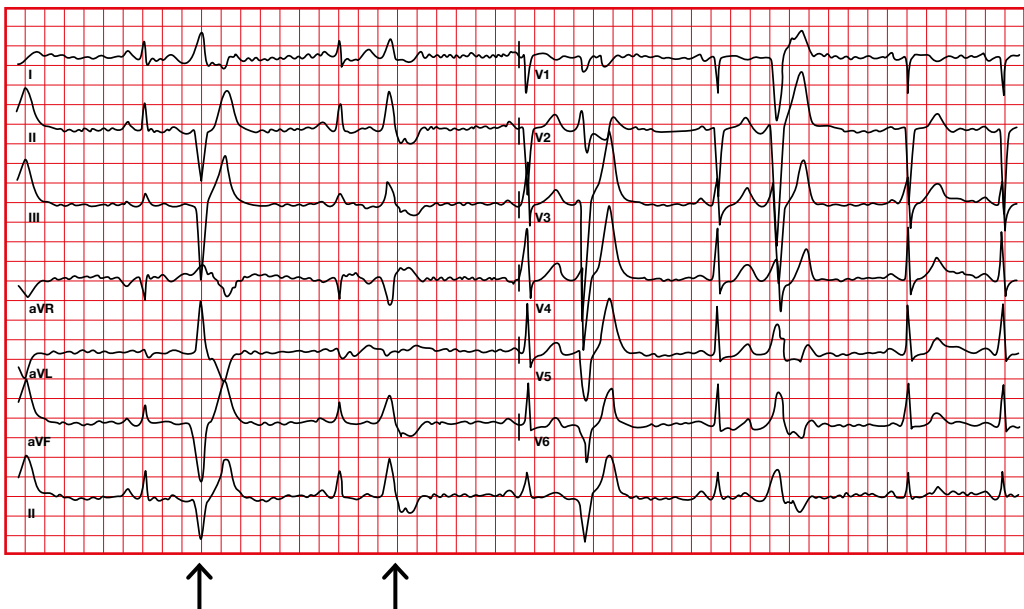
- QRS that is premature to normal RR and not preceded by a P wave.
- The QRS is normally > 0.12 seconds.
- The initial axis of the QRS is different from the QRS during sinus rhythm.
- Secondary ST-T changes in a direction opposite to the major QRS deflection.
- There may be retrograde atrial activation.
- There is compensatory pause.

Monomorphic

All extrasystoles are identical in the same lead.

Polymorphic

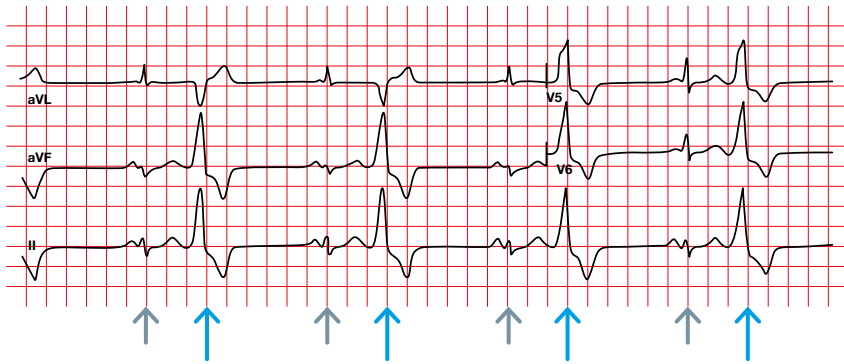
Two or more morphologies.



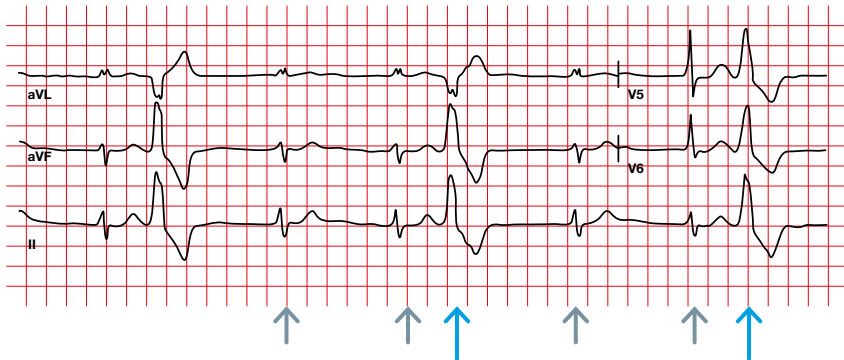
In some cases extrasystoles appear repetitively, each certain number of normal depolarizations. They are

named according to the numerical relationship between the normal depolarizations and the extrasystoles.

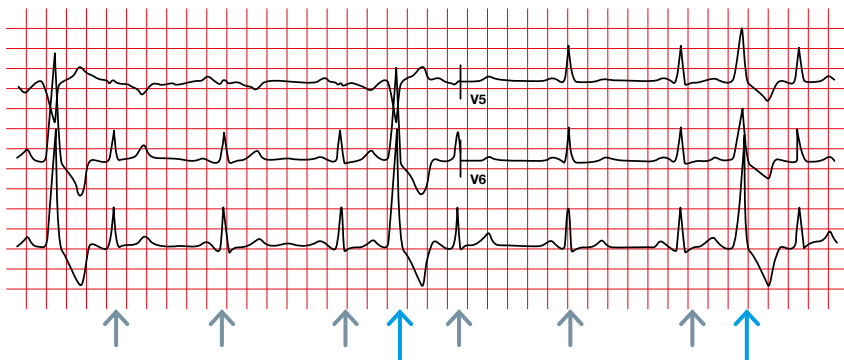
Bigeminism



Trigeminism



Quadriginism

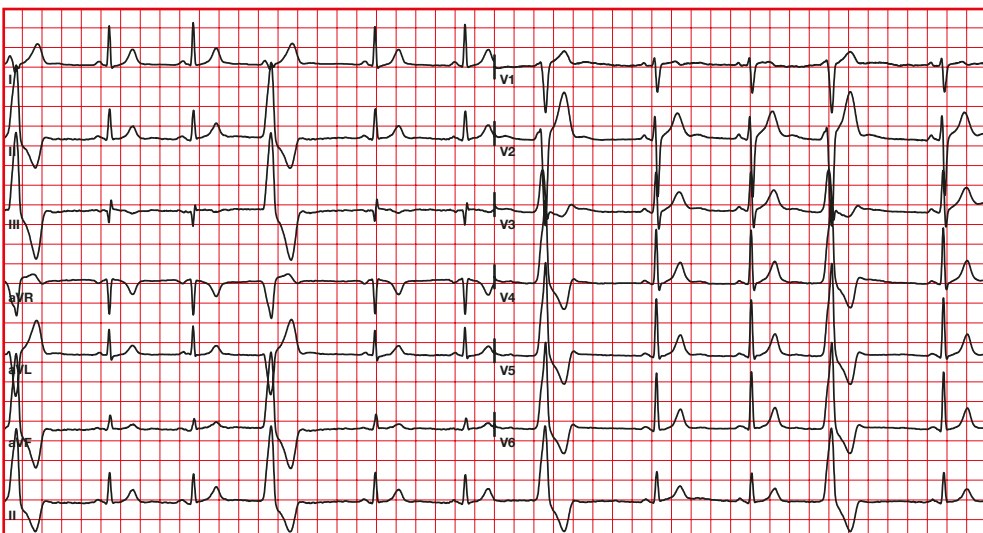
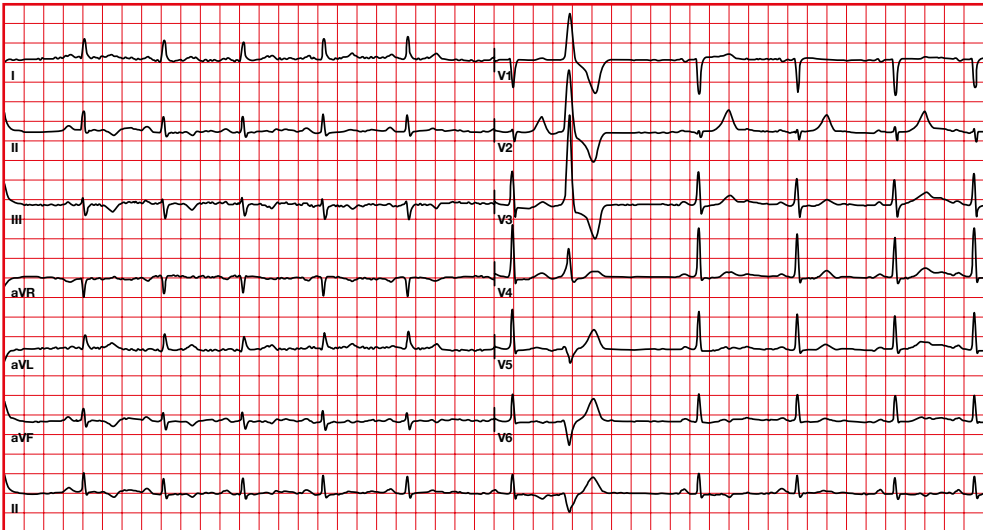


7.2. Right extrasystole

- It will be negative in V1 with a left bundle branch block pattern.
- They are usually seen in structurally normal hearts.

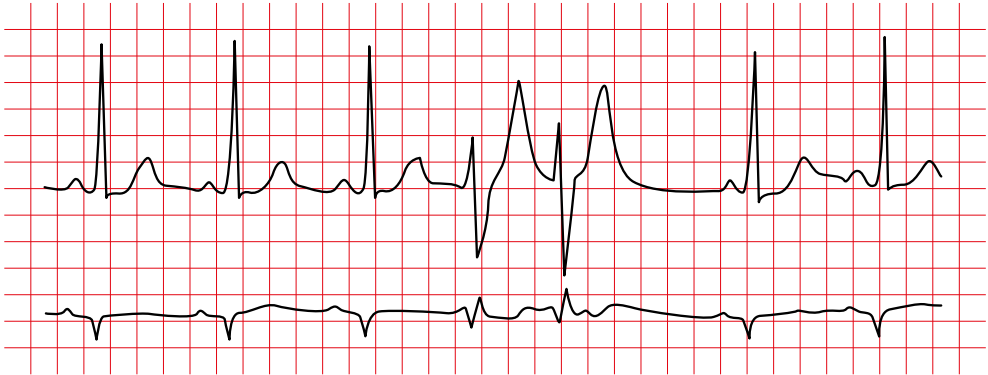
7.3. Left extrasystole

- It will be positive in V1 with a right bundle branch block pattern.
- They tend to be more associated with cardiovascular disease.
- They precipitate ventricular fibrillation more easily during an acute myocardial infarction.

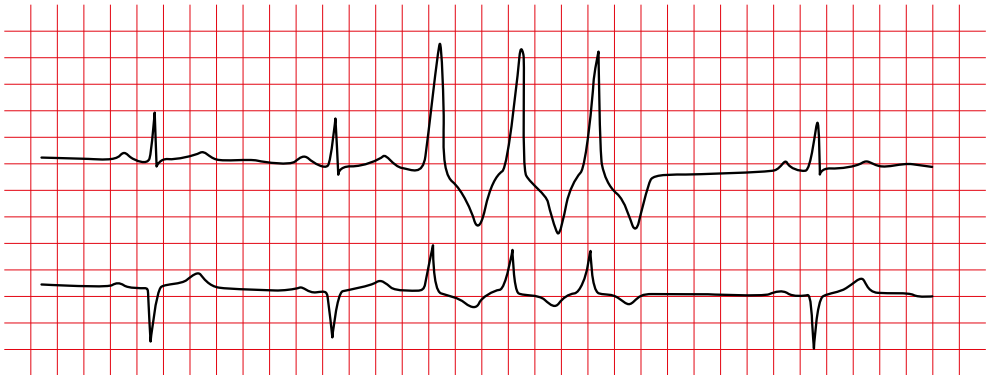


7.4. Ventricular extrasystoles

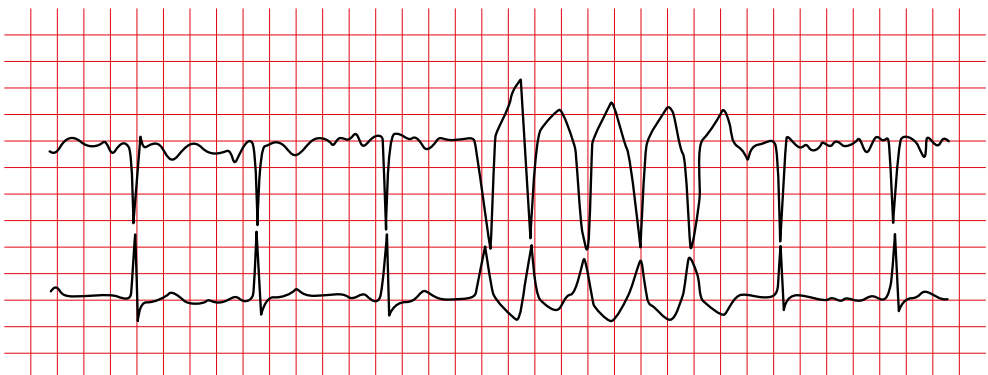
Couplet



Triplet



Non-sustained VT



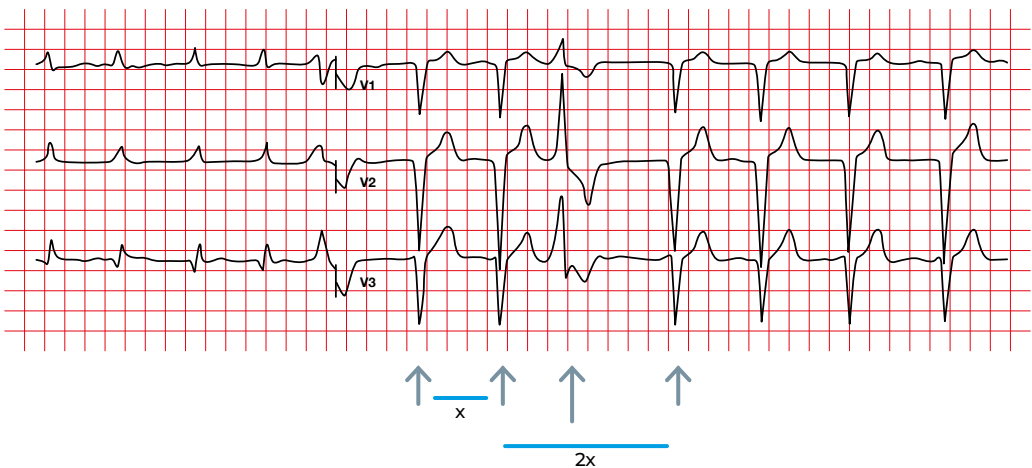
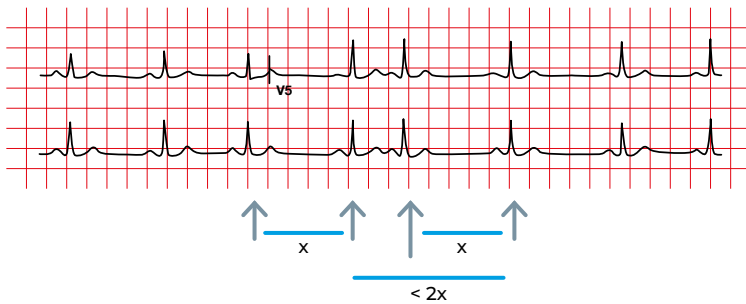
7.5. Distinction between supraventricular and ventricular extrasystoles

Atrial extrasystoles:

- There is a reset of the rhythm. Therefore, after the premature stimulus the supraventricular rhythm is reactivated (there is no compensatory pause).
- The PP containing the extrasystole is less than twice that of a normal PP.
- QRS can be wide, due to aberrant conduction.

Junctional or ventricular extrasystoles:

- There is no reset of supraventricular activation. Therefore, the normal stimulus following the extrasystole is not advanced (there is a compensatory pause).
- The PP that contains the extrasystole is twice that of a normal PP.



7.6. Ventricular tachycardia

- It can be monomorphic/
polymorphic.
- In monomorphic VT the RR is
normally regular, but it can be
irregular.
- There is an abrupt onset and end of
the arrhythmia.
- There is AV dissociation.
- Fusion and capture beats can be
observed.

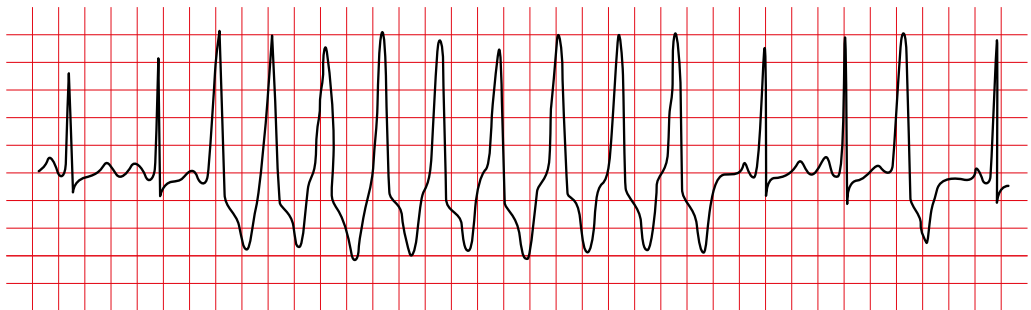
Non-sustained:

- ≥ 3 consecutive beats.
- Rapid succession of three or more
ventricular beats at a rate of more
than 100 per minute.

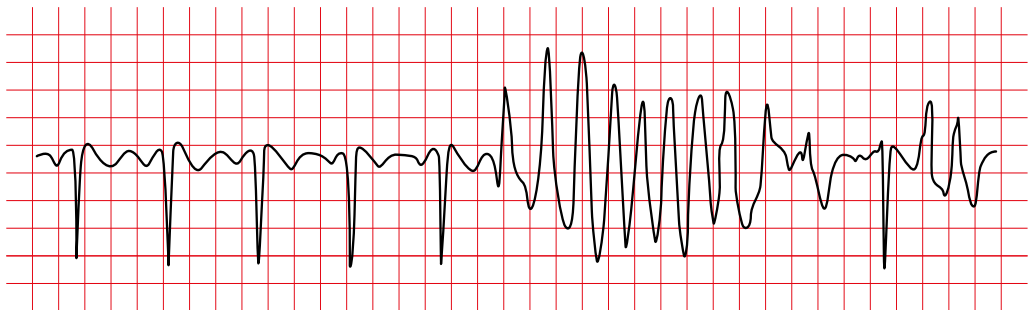
Sustained:

- Ventricular tachycardia that lasts
> 30 seconds.

Monomorphic non-sustained ventricular tachycardia

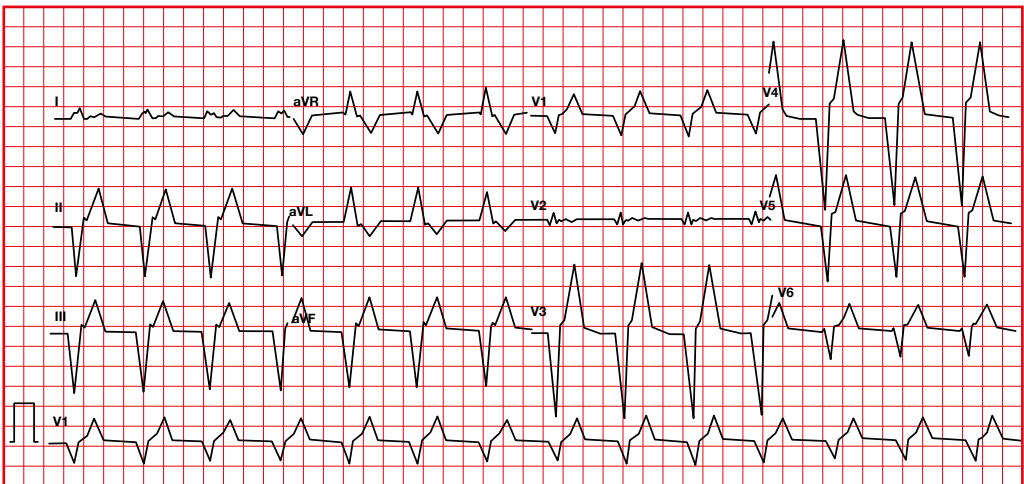


Polymorphic non-sustained ventricular tachycardia



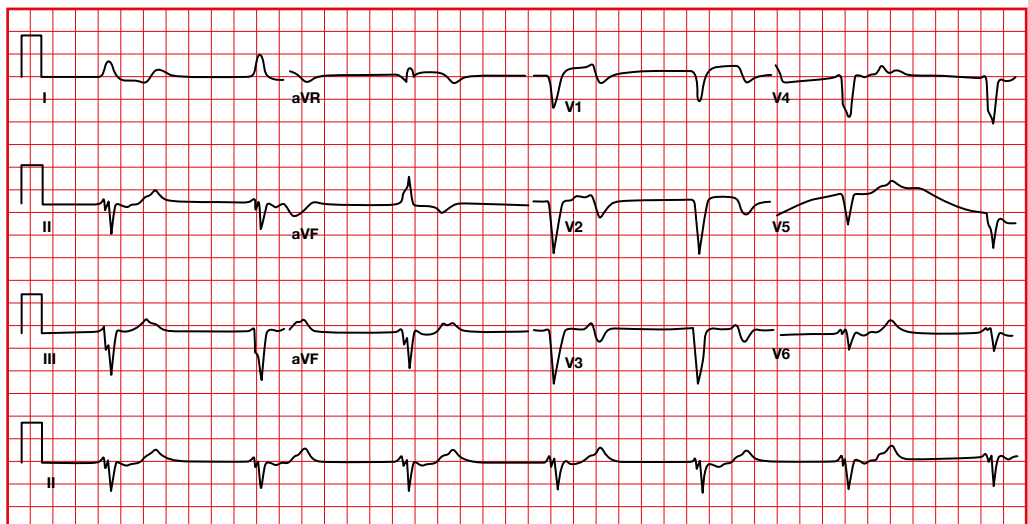
7.7. Accelerated idioventricular rhythm

- Regular or minimally irregular rhythm.
- Frequency from 60 to 110 beats per minute.
- 3 or more ventricular complexes with QRS > 120 ms.
- AV dissociation is common.
- Capture and fusion complexes are observed.
- Associated with reperfusion in a context of myocardial infarction.



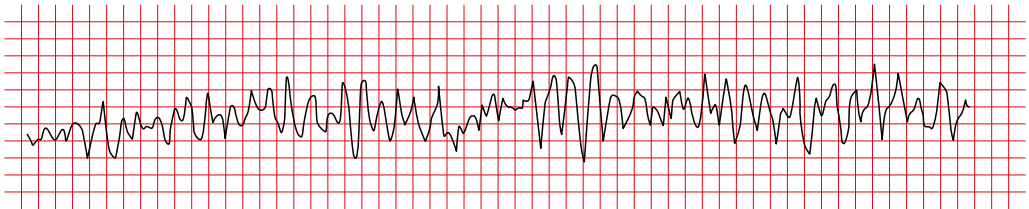
7.8. Ventricular escape rhythm

- Regular or minimally irregular ventricular rhythm.
- Frequency of 30 to 40 beats per minute, it can be 20 to 50 beats.
- Ventricular complexes with QRS > 120 ms.



7.9. Ventricular fibrillation

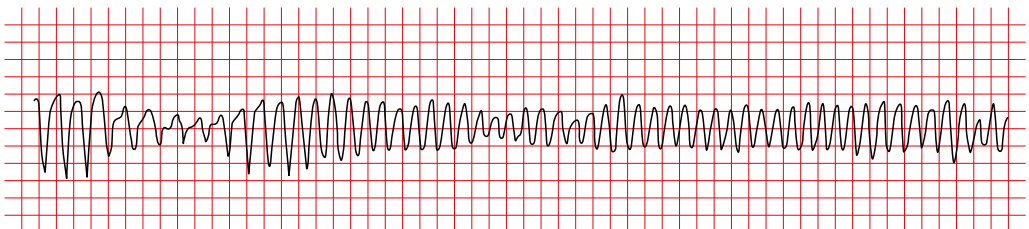
- Rapid and irregular ventricular rhythm.
- No clear P, QRS, or T waves are detected.
- Erratic and uncoordinated heart rhythm.



7.10. Torsade de pointes

Very fast arrhythmias caused by:

- Low potassium, calcium or magnesium.
- Medications that block potassium channels (some antifungals, antiarrhythmics, antidepressants, phenothiazines).
- Genetic alterations (Long QT syndrome).

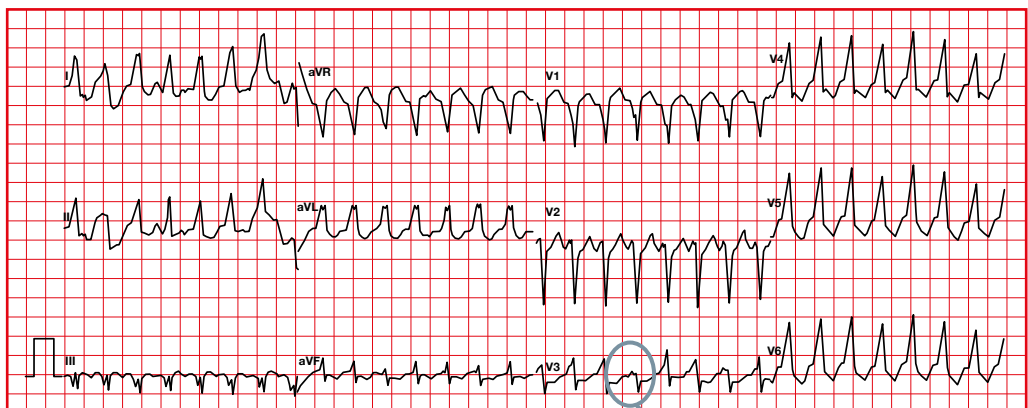


8. Differentiation between ventricular tachycardia and supraventricular tachycardia with wide QRS

A well-tolerated tachycardia does not rule out the possibility that it may be ventricular.

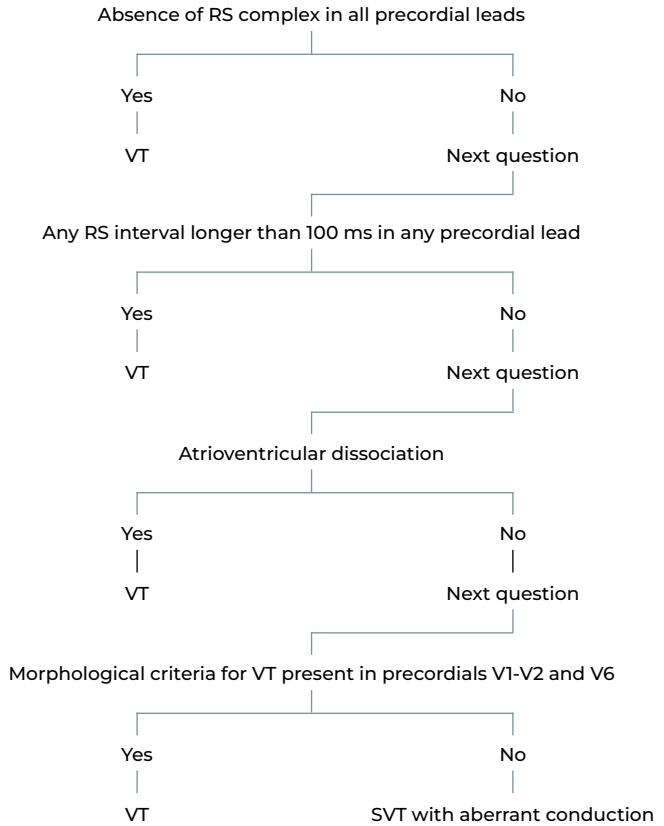
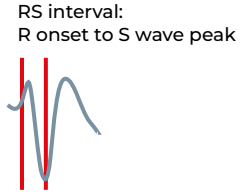
Will favor TV:

- Extreme right axis deviation.
- QRS > 140 ms.
- Presence of fusion or capture beats.

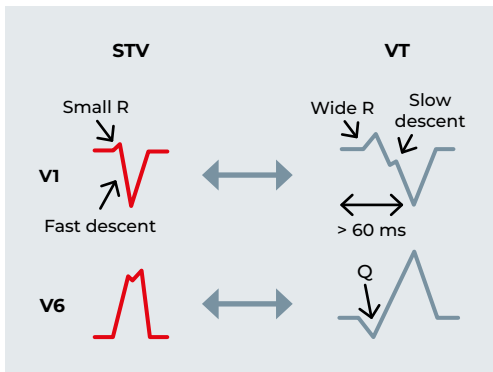


Fusion beat

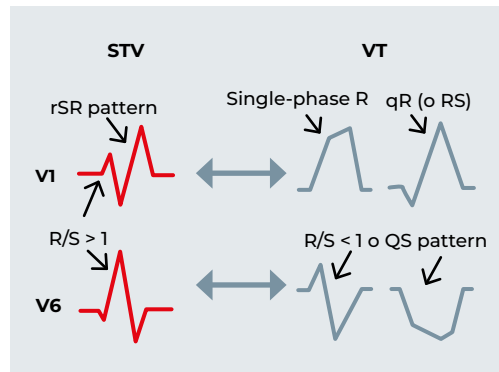
Brugada algorithm

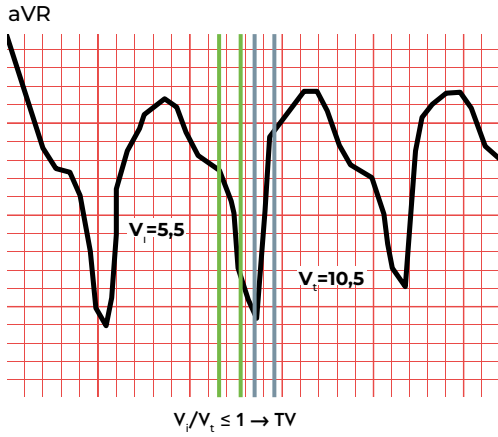


LBBB



RBBB

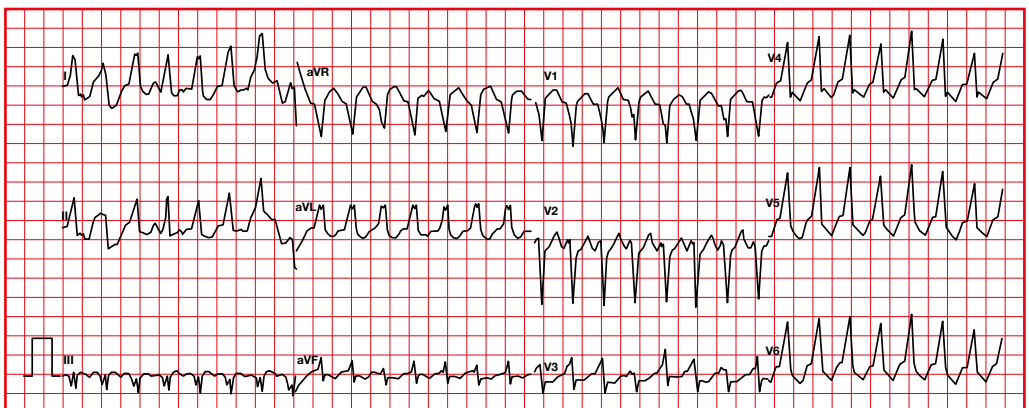
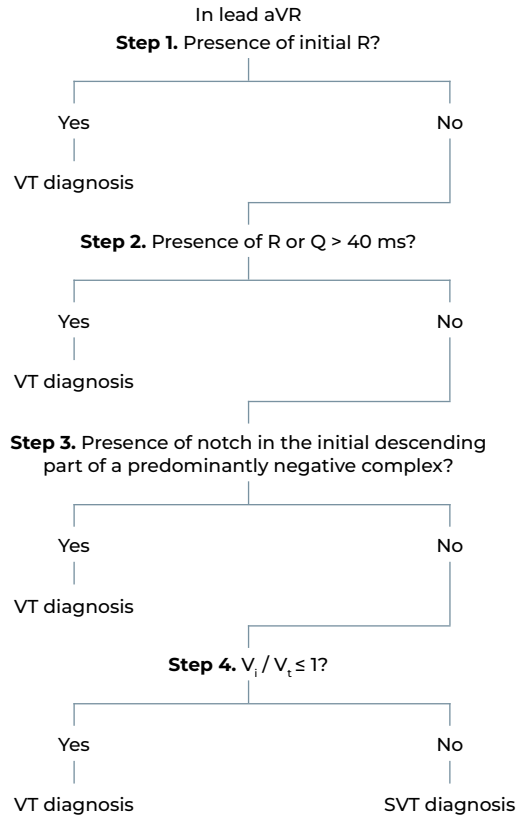




V_i : amplitude of the depolarization vector in the initial 40 ms.

V_t : amplitude of the depolarization vector in the terminal 40 ms.

Vereckei criteria



A concise and clear guide to understanding the interpretation of the electrocardiogram (ECG). This book covers the fundamentals of cardiac cellular electrophysiology through to the systematic assessment of the ECG, using a sequential analysis of waves, complexes, segments and intervals. With a didactic and accessible structure, it provides a detailed explanation of the electrical activity of the heart, its transmission and possible alterations, helping the reader to identify normal and pathological patterns accurately.

Designed for both students and health professionals, with simple language and practical examples, *Electrocardiography at your fingertips* is an indispensable tool for anyone who wants to master ECG interpretation safely and effectively.



Documenta
Universitaria

@DocUniv
documentauniversitaria.com



CÀTEDRA UDG DE
MALALTIES
CARDIOVASCULARS

Universitat
de Girona



